

## CASE REPORT

doi: 10.5455/medarch.2023.77.155-157

MED ARCH. 2023 APR; 77(2): 155-157

RECEIVED: DEC 10, 2022

ACCEPTED: FEB 12, 2023

<sup>1</sup>Department of Diagnostic Radiology and Nuclear Medicine, Faculty of Medicine, Jordan University of Science and Technology, Irbid, Jordan

<sup>2</sup>Department of Surgery, Faculty of Medicine, Jordan University of Science and Technology, Irbid, Jordan

**Corresponding author:** Naser Obeidat, MD. Department of Diagnostic Radiology and Nuclear Medicine, Faculty of Medicine, Jordan University of Science and Technology, P.O.Box 3030, Irbid 22110, Jordan. E-mail: nmobeidat8@just.edu.jo. Phone: +962 799 677 944. ORCID ID: <http://www.orcid.org/0000-0002-2155-7743>.

# Perforated Stress Ulcer of the Duodenum: a Case of an Unexpected Diagnosis in a COVID-19 Patient Following Dilatation and Curettage Procedure

Naser Obeidat<sup>1</sup>, Ghaith Heilat<sup>2</sup>, Tarek Ajam<sup>1</sup>, Hamzeh Al-Zoubi<sup>1</sup>

## ABSTRACT

**Background:** Stress ulcers in the upper gastrointestinal tract can arise from pathologies related to erosive or inflammatory insults in critically ill patients. The relationship between stressful bodily events and the ischemia and perforation of stress ulcers is poorly understood. **Objective:** We present a case of perforated stress ulcer following an abortion that was treated by dilatation and curettage (D&C) and complicated by a coronavirus disease 2019 (COVID-19) infection. **Case presentation:** A 40-year-old lady presented to the emergency room complaining of diffuse abdominal pain, she was recently diagnosed with an incomplete abortion and managed via a D&C procedure in an external hospital. A computed tomography (CT) scan was done at our center for the abdomen and pelvis, showing extensive pneumoperitoneum, which brought the radiologist's attention to suspect a small bowel perforation presumably accompanying a uterine perforation secondary to the D&C. There were no obvious signs of pelvic small bowel perforation in the initial CT images. The perforated duodenal stress ulcer was diagnosed the next day by a new CT scan following oral contrast ingestion and managed surgically by repair and omental patch, and no other bowel perforations were found upon surgical exploration. After the surgery, the patient was diagnosed with COVID-19, and her clinical status deteriorated gradually during the following week, and she passed away from a cardiac arrest. **Conclusion:** It is unclear whether septic abortion or COVID-19 has resulted in stress ulcer perforation in our patient. This case report highlights the importance of raising early suspicion in the diagnosis of stress ulcer perforation in critically ill patients to reduce the risk of morbidity and mortality.

**Keywords:** Duodenal ulcer, pneumoperitoneum, computed-tomography, COVID-19.

## 1. BACKGROUND

In 1969, stress ulceration was first identified as a focal lesion in the mucosa of the gastric fundus during a post-mortem examination of critically ill patients (1). The term "stress-related mucosal damage" (SRMD) was later used to describe the pathology associated with acute, erosive, and inflammatory insults to the upper gastrointestinal tract in critically ill patients (2). Studies have linked stress-related gastrointestinal bleeding to poor prognosis, including perforation, hemorrhagic shock, and death (1, 3). A study by Selye et al has shown that stress can lead to the development of gastrointestinal ulcers and is a major contributing factor to peptic ulceration (4).

The stomach lining has many mechanisms in place to protect itself from damage, due in part to the acidic environment of the stomach (5). The exact cause of gastric and duodenal ulcers in critically ill patients is not known, but it is believed that factors such as inflammation, reduced blood flow to the gut, and poor circulation from conditions such as low blood volume or shock can lead to damage and a decrease in the pH level within the stomach lining (6).

Hemorrhage is the most typical symptom of a stress ulcer, but perforation and blockage can also occur, although they are rare. Additionally, stomach-related symptoms are usually not present (7). Patients with a perforated ulcer require extra attention, and it is essential to provide prompt diagnosis, resuscitation, and appropriate surgical treatment to minimize the risk of morbidity and mortality (8).

© 2023 Naser Obeidat, Ghaith Heilat, Tarek Ajam, Hamzeh Al-Zoubi

This is an Open Access article distributed under the terms of the Creative Commons Attribution Non-Commercial License (<http://creativecommons.org/licenses/by-nc/4.0/>) which permits unrestricted non-commercial use, distribution, and reproduction in any medium, provided the original work is properly cited.

## 2. OBJECTIVE

This report presents a patient who developed a stress ulcer following D&C and was further complicated by COVID-19. To the best of our knowledge, it is the first reported case of this type in the medical literature.

## 3. CASE PRESENTATION

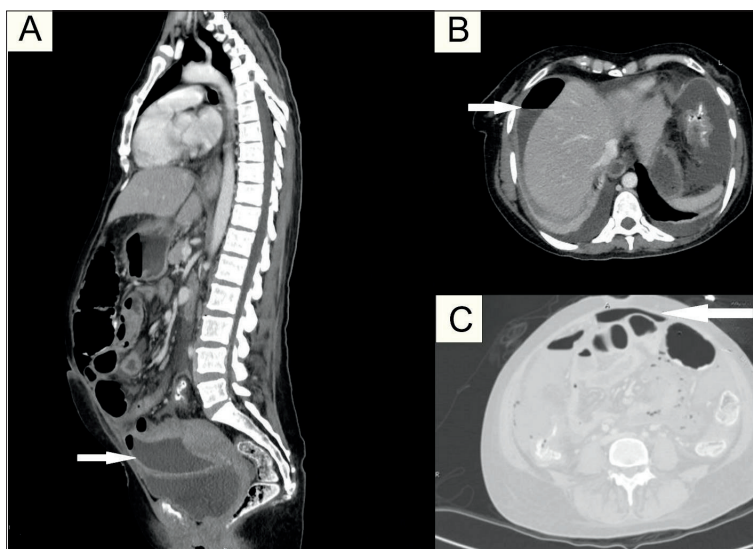
A 40-year-old lady presented to the emergency room (ER) with diffuse abdominal pain. She was medically and surgically free until 8 days before her presentation when she tested positive for pregnancy in a primary health care center and was reassured and sent back home. Four days after that her pain persisted with the new development of vaginal spotting, which was subsequently diagnosed with an incomplete abortion, for which a D&C was performed in a community hospital. After four days in the hospital, she was discharged on antibiotics (metronidazole and ceftriaxone) and analgesia.

The day following discharge the patient's symptoms persisted and became much more intense with new nausea, non-bilious vomiting (10 times a day), and abdominal distention, for which she sought medical attention at our center. A physical exam revealed abdominal distention, rigidity, diffuse tenderness, and guarding. The pain was severe and stabbing in nature, mainly in the paraumbilical region.

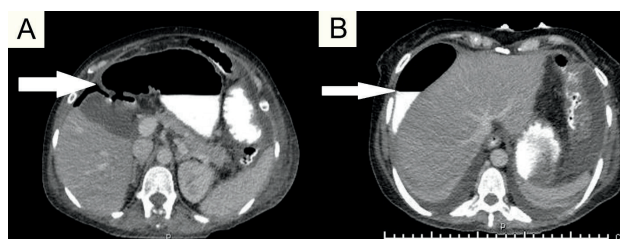
Uterine perforation was suspected; therefore, a computed tomography (CT) scan of the abdomen and pelvis was done. The uterus appeared slightly bulky, without gross mural defects seen to suggest perforation, though this could not be excluded with confidence at the time. In addition, the CT showed a rim-enhancing collection just above the uterus and multiple other collections throughout the remaining abdomen and pelvis, mainly in the bilateral paracolic gutters and the right perihepatic region with air-fluid level, associated with extensive pneumoperitoneum as shown in Figure 1 A, B, and C.

These findings raised concerns for small bowel perforation in the pelvis that was presumed to have happened, in conjunction with a subtle or partially sealed uterine perforation, during the D&C procedure. Medical attention was brought to this clinical scenario, despite there being no obvious mural defects detected on the CT scan images in pelvic small bowel loops with good distention. The treating surgeon decided to conservatively treat the patient, and the patient was responding well to the management plan (nothing by mouth "NPO", broad-spectrum antibiotics, and prophylactic proton-pump inhibitor "PPI"), and all her vital signs were unremarkable except for mild tachycardia. The interventional radiology team also inserted a pigtail catheter into the walled-off pelvic collection to drain 1.2 L of purulent fluid.

A follow-up CT scan with oral contrast was performed the next day, revealing a 0.5 cm mural defect in the anterior wall of the first part of the duodenum, with extravasation of oral contrast into the right perihepatic region



**Figure 1. A) Walled-off rim-enhancing pelvic fluid collection just anterior to the uterus; B) Air-fluid level in the right perihepatic region; C) Pneumoperitoneum.**



**Figure 2. A) Duodenal mural defect; B) Air-contrast level in the right perihepatic region.**

as shown in Figure 2 A and B. This was overlooked on the initial CT scan probably due to the small size of the defect, and more importantly the unintentional, clinically guided false preoccupation with the diagnosis of pelvic small bowel perforation. This was explained by the treating team as a perforated stress ulcer and was subsequently managed on the following day with surgical exploration and repair with an omental patch. No other areas of bowel perforation were detected during surgery, particularly in pelvic small bowel loops.

Paralleling the aforementioned clinical events, the patient experienced mild shortness of breath since the day of admission, which was initially interpreted by the critical care team to be secondary to abdominal distention, especially since this has improved after pigtail insertion to the pelvic collection. A rapid COVID-19 antigen test was done returning as negative. A reverse transcription polymerase chain reaction (RT-PCR) test via a nasal swab was performed at the same time, but it returned positive on the 1st-day post-surgery. The respiratory team was consulted, and the patient was put on an appropriate management plan.

It was not until the 3<sup>rd</sup>-day post-surgery that the patient's respiratory condition started to deteriorate, for which a more vigorous treatment plan was applied. The patient improved subsequently, though with residual mild tachycardia and tachypnea. However, this improvement did not last long since the patient deteriorated again on the 6th-day post-surgery when she developed cardiac arrest and died.

#### 4. DISCUSSION

Our case illustrates an overlooked radiology diagnosis: stress-induced stomach and duodenum ulcers. Multiple pathophysiological factors could have contributed, either alone or in combination, to the stress ulcer development in our patient.

The cause of stress ulcers is not fully understood, but it is believed to be the result of multiple factors. It has been previously suggested that stress ulcers can develop following situations such as shock, sepsis, and trauma (9). Even though there has been progress in understanding the underlying physiology and treatment of stress ulcers, it remains a major public health concern. The specific mechanism behind the development of stress ulcers in the stomach is still a topic of debate (9).

According to the sequence of events, abortion complicated by sepsis – either septic abortion per se or secondary to the D&C procedure—can be the trigger for the chain of events that cause damage to the mucous membranes. There is little research on whether septic abortion can specifically lead to stress ulcers. However, it is known that septic abortion can cause sepsis, and stress ulcers may form as a complication of sepsis (10). Studies have shown that death resulting from septic abortion can be as high as 10 to 100 deaths per 100,000 abortions in some low and middle-income countries (11).

It is also possible that the stress ulcer was a complication of the patient's COVID-19 infection. While the focus of the radiological and surgical attention was on the diagnosis of small bowel perforation in the pelvis, the patient's COVID-19 lung infection was also becoming more severe. Previous research has indicated that there is a significant likelihood that the virus can lead to stress ulcers. A study conducted in northern Italy found that upper gastrointestinal bleeding complicated hospital stays in almost 0.5% of COVID-19 patients, and peptic ulcer disease was the most common finding (12). The reason why COVID-19 might cause gastrointestinal problems is related to the severe inflammation that is associated with the virus. This inflammation is characterized by an increase in acute phase reactants, such as a cytokine storm. Examples of these reactants include C-reactive protein, ferritin, and coagulopathy. These factors can raise the probability of bleeding in the gastrointestinal tract (13).

Based on the clinical data available at the time of presentation to our center, we are not sure whether the COVID-19 infection, the septic abortion, or the post-D&C sepsis resulted in the stress ulcer. However, our patient ended up with a perforated viscus that eventually had been repaired surgically by an omental patch. Interestingly, the first reported case in the literature for performing surgery on a patient with COVID-19 was on a perforated duodenal bulb ulcer (14).

#### 5. CONCLUSION

Our case report emphasizes the importance of the radiologist's role in raising early suspicion with the diagnosis of stress ulcer perforation in critically ill patients. Overall, gastroduodenal stress ulcers are a serious com-

plication, and prompt recognition and management are important to reduce the risk of morbidity and mortality.

- **Patient Consent Form:** Written informed consent was obtained from the patient in question.
- **Author's contribution:** All authors were involved in the preparation of this article. Final proofreading was made by the first author.
- **Competing interests:** The authors declare that they have no competing interests.
- **Funding:** The authors did not receive support from any organization for the submitted work.

#### REFERENCES

1. Skillman JJ, Bushnell LS, Goldman H, Silen W. Respiratory failure, hypotension, sepsis, and jaundice: A clinical syndrome associated with lethal hemorrhage from acute stress ulceration of the stomach. *The American Journal of Surgery*. 1969 Apr; 117(4): 523–530, doi: 10.1016/0002-9610(69)90011-7.
2. Peura DA. Stress-related mucosal damage. *Clin Ther*. 1986; 8(Suppl A): 14–23.
3. Czaja A, McAlhany JC, Pruitt BAJ. Acute gastroduodenal disease after thermal injury. An endoscopic evaluation of incidence and natural history. doi: <https://doi.org/10.1056/nejm197410312911801>.
4. Selye H. A syndrome produced by diverse noxious agents, 1036. *J Neuropsychiatry Clin Neurosci*. 1998; 10(2): 230–233. doi: 10.1176/jnp.10.2.230a.
5. Laine L, Takeuchi K, Tarnawski A. Gastric Mucosal Defense and Cytoprotection: Bench to Bedside. *Gastroenterology*. 2008; 135(1): 41–60. doi: 10.1053/j.gastro.2008.05.030.
6. Maynard N. et al. Assessment of splanchnic oxygenation by gastric tonometry in patients with acute circulatory failure. *JAMA*. 1993 Sep; 270(10): 203–210.
7. Moody FG, Cheung LY. Stress ulcers: Their pathogenesis, diagnosis and treatment. *Surgical Clinics of North America*. 1976; 56(6): 1469–1478. doi: 10.1016/S0039-6109(16)41099-6.
8. Elnagib E, Mahadi SEI, Ahmed ME. Perforated peptic ulcer in Khartoum. *Khartoum Medical Journal*. 2008; 1(2): 62–64. Available at: [https://www.researchgate.net/publication/277193116\\_Perforated\\_peptic\\_ulcer\\_in\\_Khartoum](https://www.researchgate.net/publication/277193116_Perforated_peptic_ulcer_in_Khartoum)
9. Moody FG, Cheung LY. Stress ulcers: Their pathogenesis, diagnosis and treatment. *Surgical Clinics of North America*. 1976; 56(6): 1469–1478. doi: 10.1016/S0039-6109(16)41099-6.
10. Finkielman JD, de Feo FD, Heller PG, Afessa B. The clinical course of patients with septic abortion admitted to an intensive care unit. *Intensive Care Medicine*. 2004 Jun; 30(6): 1097–1102. doi: 10.1007/s00134-004-2207-7.
11. Åhman E, Shah LH. New estimates and trends regarding unsafe abortion mortality. *International Journal of Gynecology and Obstetrics*. 2011; 115 (2): 121–126. doi: 10.1016/j.ijgo.2011.05.027.
12. Mauro A. et al. Upper gastrointestinal bleeding in COVID-19 inpatients: Incidence and management in a multicenter experience from Northern Italy. *Clin Res Hepatol Gastroenterol*. 2021 May; 45(3): doi: 10.1016/j.clinre.2020.07.025.
13. Mccreary EK, Pogue JM. Treatment: A Review of Early and Emerging Options. doi: 10.1093/ofid/ofaa105/5811022.
14. He L, Zhao W, Zhou W, Pang P, Liao Y, Liu J. An Emergency Surgery in Severe Case Infected by COVID-19 With Perforated Duodenal Bulb Ulcer. *Ann Surg*. 2020 May; 272(1): e35–e37. doi: 10.1097/SLA.0000000000003958.