

Toxoplasmosis Gondii Infection and Diabetes Mellitus Type 2 Treated by Using Autologous Peripheral Blood Stem Cells a Unique Case Report of a Caucasian 83 Year Old Lady

Ciro Gargiulo^{1*}, Van Hung Pham², Kieu C.D. Nguyen¹, Ngan Duong Kim¹, Thinh Nguyen Van¹, An Luu Tuan¹, Kenji Abe³, and Melvin Shiffman⁴

¹ Division of Internal Medicine, The Human Medicine International Clinic, Ho Chi Minh City, Vietnam

² Molecular Diagnostics Department, Nam Khoa-Biotek Laboratory, Ho Chi Minh City, Vietnam

³ Department of Pathology, National Institute of Infectious Diseases, Tokyo, Japan

⁴ Section of Surgery, Newport Specialty Hospital, Tustin, California.

*Corresponding author: dr.ciro@humanmedicine.com

Received: 13 July 2015 / Accepted: 20 August 2015 / Published online: 30 August 2015

© The Author(s) 2015. This article is published with open access by BioMedPress (BMP)

Abstract— Introduction: *Toxoplasma gondii* is an intracellular protozoan responsible for up to one-third of the world's population infestation. Diabetes is one of the most silent and threatening disease of the modern time it is constantly increasing in both industrialized and developing countries. This is a case of clinical importance for two reasons, firstly it will help clinicians save a broad differential diagnosis when attending to evaluate analogous cases and secondly, it may confirm the role of autologous peripheral blood stem cells (PB-SCs) in enhancing auto-immune response against parasitic infection and in regulating insulin uptake in diabetes mellitus type 2 (DM2). Case presentation: We present a unique case of 83-year-old woman from Argentina presenting with a widespread erythema and urticaria for 5 months and DM2 as underlying condition. She was initially diagnosed with unspecific skin auto-immune disorder. By the time of visit she was complaining of constant diarrhea-constipation and general mental and physical fatigue. Conclusion: This case illustrates that toxoplasmosis can present with just simple disseminated and generalized skin erythema with severe itching and, thus can be confused with similar infectious disease such as Epstein-Barr virus (EBV), cytomegalovirus, cat scratch disease or leishmaniasis. The report emphasizes the need of correct diagnostic procedure in confusing cases, and may help to increase the awareness about the identification of this disease. This case may open to the possibility of a different approach and methodology in treatment *T gondii* and DM2 through the use of PB-SCs.

Key words: Toxoplasma gondii, Human Peripheral Blood Stem cells, NK cells, CD3, CD4, CD8.

INTRODUCTION

Toxoplasma gondii is a very hostile and exceptionally common intracellular protozoan parasite with one of the highest infestation rates among world's population (Fong MY, 2010; Taila et al., 2011). Transmission of *T. gondii* starts by ingestion of infected food or contaminated water containing cysts of the parasite, it can be transmissible through blood transfusion and organ transplant (Masters, 2015; Taila et al., 2011). However, in healthy subjects the infection is generally asymptomatic and can remain silent for years (Fong MY,

2010). Manifested symptoms are similar to those of different infectious diseases such as EBV, varicella, mononucleosis, cytomegalovirus, cat scratch disease or leishmaniasis and can include lymphadenopathy, fever, fatigue, muscle pain, sore throat and headache (Fong MY, 2010). In pregnant women, toxoplasmosis can be of serious risks of malformation to fetus, neurological impairment, impaired vision even death (Fong MY, 2010). In immunosuppressed individuals, the infection may trigger secondary disseminated infection in system leading to death (Fong MY, 2010). Cutaneous manifestation of toxoplasmosis, however, is rarely

encountered (Fong MY, 2010). Clinical presentation of *T. gondii* infection varies with the age and immune status of the patient. Roughly 10% of immune competent patients develop a non-specific and self-limiting illness most typically characterized by isolated cervical or occipital lymphadenopathy that may persist for less than four to six weeks (Taila et al., 2011). The lymph nodes are usually unnoticeable, non-tender and are not exclusive for *T. gondii* diagnosis (Fong MY, 2010; Masters, 2015; Taila et al., 2011). Rarely immune competent patients may develop some form of secondary infection such as myocarditis, polymyositis, pneumonitis, hepatitis, or encephalitis (Fong MY, 2010; Hoffman A, 2008; Masters, 2015; Taila et al., 2011). In general, after the acute phase, the infection will remain latent due to the presence of cysts within the tissues which does not manifest clinical symptoms (Taila et al., 2011). Conversely, for immunocompromised patients, such as with HIV or common variable immunodeficiency (CVID) this parasite can be a serious life-threatening pathogen (Porter and Sande, 1992). In this population, toxoplasmosis arises consequently to a reactivation of subtle chronic condition often affecting the central nervous system (CNS) (Mrusek et al., 2004; Porter and Sande, 1992; Shachor et al., 1984). *T. gondii* infection can be diagnosed via different types of screening, directly via polymerase chain reaction (PCR), hybridization, isolation, and histology and indirectly via serological methods (Fong MY, 2010; Hoffman A, 2008; Liesenfeld et al., 2001; Masters, 2015; Mrusek et al., 2004; Porter and Sande, 1992; Shachor et al., 1984; Taila et al., 2011). Immunocompetent patient are usually tested by indirect serological methods as it is faster and readily available; however, it is highly recommended that this screening for asymptomatic immunocompromised patients as well, for IgG antibodies to *T. gondii*, as this allows to recognize recurrence of latent infection (Liesenfeld et al., 2001). It is generally accepted that the presence of high avidity antibodies is likely to indicate a more recent infection which might be happened during a period of past three to four months; on the other hand, low avidity antibodies tend to be present well after three months of infection indicating a past acquired infection (Liesenfeld et al., 2001). PCR amplification of *T. gondii* genes (specifically, the B1 gene) can be performed on both fluids and tissue samples, which in optimal storage and handling condition would give a sensitivity rate no greater than 50% but would be highly specific (Angel SO, 1997). Conventional thera-

py depends on immunity state of the patient. Pyrimethamine, sulfadiazine and folinic acid are usually used for both immunocompromised patients and immunocompetents with severe or recurrent signs of the infection (Torre D, 1998). Duration of treatment varies from two to four months, depending on clinical signs and symptoms (Torre D, 1998). Protocol indicates maintenance therapy to be commenced after the acute phase and should be based on half dose medication used during the acute phase. Kaplan and colleagues have suggested that this therapy should be continued until symptoms and immunology responses are resolved. Particular cases such as in HIV infected patients the therapy should be continued for the life (Masur, 2002). Diabetes is a life persistent disorder affected by daily food intake, life-style, genetic predisposition, infection (Coxsackie B4 virus) and stress (Shivanshankar M, 2011). The genetic element has been traced to particular HLA genotypes known as genetic "self" identifiers that closely depend on the immune system (Shivanshankar M, 2011). It is a metabolic disorder characterized by high blood glucose accompanied by insulin resistance and relative insulin deficit (Shivanshankar M, 2011). At the initial onset of the disease DM is managed by increasing exercise and diet, however over the time the condition steadily progresses thus medications are needed to control the elevation incidence of blood sugar (Shivanshankar M, 2011). Cardiovascular diseases, ulcerative lesions, retinopathies and kidney failures are long-term complications from high blood sugar (Shivanshankar M, 2011).

Autologous Peripheral Blood Stem Cells can improve immunity response and can act against Diabetes type 2 progression

Though we did not anticipate such special effects as we started with the intention to treat skin allergic reaction, in this paper, we present a possible novel therapeutic strategy based on autologous PB-SCs in the treatment of parasitic infestation and DM2. In this case we obtained two main unexpected results, a particular improvement of a chronic parasitic infection of *T. gondii* and a complete remission of DM2 in an 83 year old woman. As previously established human peripheral blood revealed to have different sub-groups of pluripotent and multipotent stem cells that may represent a breakthrough in the field of regenerative medicine and immunological condition (Gargiulo et al., 2015). Reverse transcription polymerase chain reaction (RT

PCR) was used to identify the expression of multipotent markers Oct4, Sox2, OCN, Nestin, Nanog and DMP (Gargiulo et al., 2015). Flow cytometry analysis confirmed that both adherent and non-adherent mononucleated cells were positive for a panel of multipotency and pluripotency markers such as CD44, CD73, CD90, CD133, CD 34, CD45, CD14, Nestin, SSEA3 and Tra1 (Di Nicola M, 2000). It quantified the presence of 14 hormones and, it measured the ability of hPB-SCs to secrete high level pro-inflammatory cytokines TNF α and IL-6 and low level of pro-inflammatory cytokines IFN γ and IL-2 (Gargiulo et al., 2015). The immune-modulatory capacity of stem cells is a well-recognized feature, autologous HSCs infusion following high-dose chemotherapy supported a longer disease-free survival in hematologic malignancies as well as solid tumors, and reported cases included non-Hodgkin's lymphoma in relapse, acute myelogenous leukemia and multiple myeloma (Attal et al., 1996; Bezwoda et al., 1995; Guillaume et al., 1999; Humblet Y, 1987; Philip et al., 1995; Thierry G, 1992; Zittoun et al., 1995). While the increased number of neutrophils and platelets is a crucial target in hematological recovery after intensive chemotherapy and stem cell transplantation, the recovery and the well-functioning of immune system is a fundamental goal in recovery a normal response against cancerous cells (Thierry G, 1992).

The effective recovery of lymphoid and immune effector cells is a slow process, the restoration of regular humoral and cellular immunity may take more than a year (Thierry G, 1992). Immune reconstitution involves the reconstruction of active B cells, a proliferation of thymic and extra-thymic T-cells, a reappearance of cytotoxic T cells and natural killer (NK) cells, and efficient antigen compartment crucial to rebuild the pre-transplantation immune condition (Thierry G, 1992). The immediate phase following the stem cell transplant T CD4⁺ cells tend to decrease (due to a persistently low level of naive CD4⁺/CD45RA⁺ T cells) whilst there is an increase of CD8⁺ T cells, B cells also reduce in number (Damiani et al., 2002). Patients' antigen presenting cells (APC) such as dendritic cells (DCs) are influenced either numerally or functionally after SCs transplant as well (Damiani et al., 2002; Di Nicola M, 2000). Dendritic cells induce T cell activation by binding and presenting antigens to T cells (Bachereau T, 1998)].

Literature has presented cases where SCs have been used against parasitic infestation in animal models

with very high promising results. Culture supernatant MSCs were found to inhibit activation and proliferation of macrophages enhanced by the soluble egg antigen of *Schistosoma japonicum*, whilst ameliorating liver injuries and fibrosis in mouse models (Zhang et al., 2013). Injected MSCs into naïve mice showed to promote both host resistance and host protective immune responses against malaria by modulating regulatory T cells activity (Zhang et al., 2013). The application of BM mononucleated cells in mouse models of Chagas disease showed to have double benefits activity, a clear protective anti-inflammatory activity controlling right ventricular dilatation and to reduce fibrosis insurgences (Zhang et al., 2013). In regarding the use of SCs in the context of DM1-2 research and application, MSCs are sensibly the most widely used. MSCs have been induced to generate insulin-producing cells (Karnieli et al., 2007), they have revealed a remarkable host immune-modulation (Fiorina et al., 2009; Madec et al., 2009), they showed amelioration of islet engraftment with longer survival rate (Berman et al., 2010; Ding et al., 2009) and, MSCs demonstrated an impressive curative effect on diabetic ulcers and limb ischemia (Lu et al., 2011). In nonrandomized DM2 pilot trials bone marrow derived mononuclear cells inserted by intra-arterial injection through selective cannulation within pancreatic vasculature revealed high positive impact on metabolic control on reduction of insulin requirements and A1C values without adverse effects (Bhansali et al., 2009; Estrada et al., 2008). MSCs beneficial activity on diabetes is based on their capacity to generate insulin-producing cells (IPCs) (Volarevic et al., 2010; Volarevic et al., 2011; Xie et al., 2009). These IPCs express multiple genes related to the development or function of pancreatic beta cells, including high expression of pancreatic and duodenal homeobox 1, insulin and glucagon (Xie et al., 2009). Koblas and colleagues, classify them in two concomitant groups of cells, CD133-positive pancreatic cells which contain endocrine progenitors capable of expressing neurogenin-3 and, cells expressing human telomerase, ABCG2, Oct-3/4, Nanog, and Rex-1 which carry markers of pluripotency (Koblas et al., 2008). Eventually results showed that these cells were highly proficient insulin producing cells in a glucose-dependent modus that led to amelioration of diabetic disorders in streptozotocin-treated nude mice (Xie et al., 2009). Of note, data from different lines of studies seem to confirm the role of *in vivo* hyperglycemia as a crucial element for MSCs differen-

tiation into IPCs which exert a stabilizing effect on hyperglycemia in a diabetic models (Volarevic et al., 2011).

CASE PRESENTATION

An 83-year-old lady, on cholesterol, blood pressure and diabetic type 2 medications, presented to her primary care physician with a history of persistent erythema and urticaria since few months. It was found that for one month prior to presentation, the patient had noticed multiple enlarged skin red patches, with small varicella like eruptions largely disseminated, no lymph nodes enlargement were noted. Patient was of South America heritage, but raised in the USA since her early 20's. She had not had contact with infected individuals nor had she had any occupational exposure. A series of constitutional symptoms were reported such as constant diarrhea accompanied by constipation, blurry vision, mental and physical debilitation. A panel test was performed for the presence of *Strongyloides stercoralis*, *Gnathostoma* and *Toxocara* with negative results. CBC test revealed Lymphopenia $1,29 \times 10^3/\text{mm}^3$ (normal range $1.50-4.00 \times 10^3/\text{mm}^3$). Given these findings, the primary care physician prescribed a course of antihistaminic medication Telfast and Alerius for a total period of 4 months without valuable results.

Thus, the patient came to our clinic for re-evaluation. Symptoms got worse with more intense pruritus that increased during night time. On physical examination, the patient was afebrile with normal vital signs, abdomen was bloated and distended, lower right and left quadrant were sensitive on palpation, the entire body presented with round and elongated swollen reddish-pink patches extremely itching accompanied with small varicella like eruptions. This patient was clear and cognitively alert. A monospot VZV-DNA PCR test was performed and resulted negative for *Varicella Zoster* virus infection. Upon more thorough investigation, the patient indicated that approximately every day she was eating a diet rich in meat, starches and carbohydrates. Additional laboratory studies were ordered and showed a mild high Neutrophilia 75.1 % (normal range 45-70%), high Acid uric $\mu\text{mol/L}$ (normal range $150-420 \mu\text{mol/L}$), high Glucose 7.36 mmol/L (normal range $3.9-6.4 \text{ mmol/L}$) low Testosterone 0.139 ng/ml (normal range female $0.14-1.2 \text{ ng/ml}$), low globulin 24.2 g/L (normal range $25-35 \text{ g/L}$), Folate at limit low 7.3 ng/ml (normal range $3.1-20 \text{ ng/ml}$) and

low Vitamin D 37.6 ng/ml (normal range $30-150 \text{ ng/ml}$), HbA1c 5.5% (normal range 4.1-6.5%), Glucose 7.36 mmol/L (normal range $3.9-6.4 \text{ mmol/L}$), C peptide 0.312 mmol/L (normal range $0.2-0.6 \text{ mmol/L}$), Insulin 8.12 mUI/L (normal range $<20 \text{ mUI/L}$). At the moment of the visit she was under the antihistaminic medication Telfast and Alerius, Trajenda 5mg for diabetes, Lipitor 20 mg, Co.Diovan 80/12.5 mg, Herbesser R100 100mg and Aspirin 81mg. The patient was diagnosed with a non-specific chronic/acute allergic reaction and counseled regarding dietary habits and risk factors. A specific low glycemic index diet was suggested, and in accordance with the patient treatment with autologous PB-SCs were administered to ensure resolution of allergic/intolerance reaction. At the end of the treatment clinical symptoms as itching and erythematous rashes drastically decreased by 80%, her general health state improved and she was back to a normal active life. Immediately after the treatment we decided to perform a new panel screen for parasite infestation by Elisa and, with our surprise results showed IgM negative and IgG positive with OD 1.319 for *T gondii* which confirmed that the patient has been recently infected, a month later the results showed negative for *T gondii*. RT-PCR has been performed on blood sample twice and results confirmed negative for *T gondii* infection. By the end of June diabetes marker levels revealed HbA1c 6%, C peptide 1.04 mmol/L , Glucose 5.95 mmol/L , Insulin 11.32 uU/ml . Additional test have been performed on her blood and stem cells after the treatment, by using Flow-cytometry (BD.FACS Canto II, 2-laser, 6-color) to assess her lymphocytic activity such as T cells CD3-CD4-CD8, B cells CD19, NK cells CD56-CD16, CD45, CD34 and CD14 (Fig. 1, and 2; and Table 2, and 3).

TREATMENT PROCEDURE AND CONCLUSION

Peripheral Blood Stem Cells Isolation

Mononucleated cells were isolated from consented patient's peripheral blood according to the guidelines of Helsinki Declaration. Mononucleated cells were isolated by density gradient centrifugation using Ficoll-Paque™ PLUS (GE Healthcare, Uppsala, Sweden). A total of 10 blood samples (35ml each) were carefully layered 1:2 on Ficoll-Paque and centrifuged at 300g for 20 min at 20°C. The mononucleated cell layer, 4×10^7 , at the plasma-Ficoll interface, were aspirated and was

washed three times with phosphate buffered saline and cultured in 25T flasks with free serum medium containing 2% (v/v) penicillin-streptomycin at 37 °C in a humidified atmosphere containing 5% CO2 for a period of 7.3 days.

Suspension and adherent mononucleated cells were cultured in free serum medium (FSM-Life, Technology-CTS™-StemPro[®], Canada). For both suspension

and adherent mononucleated cells, the trypan blue exclusion assay was used to observe the proliferation of the cells. Before each transfusion samples were collected to be analyzed for bacteria, fungal and viral contamination. Cells were cultured for 7.3 days average, subsequently re-suspended adherent cells were collected and injected to patient (**Table 1**).

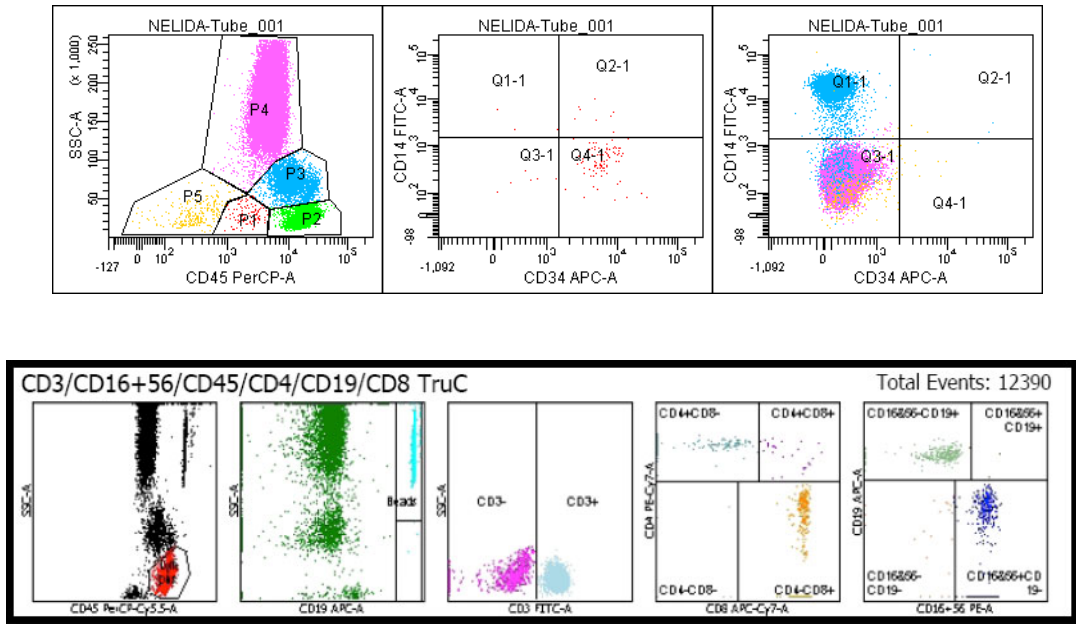


Figure 1. Flow-cytometry from patient’s peripheral blood sample after treatment (First time). The results showed these samples positive for CD45, CD14 10% and CD34 92%. CD 45 includes P1 (red color 0.3%): Basophiles; P2 (green color 23%): Lymphocytes; P3 (blue color 9%): Monocytes CD14+; P4 (violet color 67.2%): Myelo; P5 (yellow color 0.5%): erythrocytes and fragments.

Table 1. Total number of PB-SCs obtained after each culture. Average=51.375.400/ml

Date	Times	Days of cell culture	Amount of cells/ml
19 th May 2015	1	7	20.480.000
20 th May 2015	2	9	63.360.000
21 st May 2015	3	8	58.800.000
23 rd May 2015	4	7	55.440.000
25 th May 2015	5	7	61.800.000
27 th May 2015	6	7	53.625.000
29 th May 2015	7	6	52.034.000
1 st June 2015	8	6	52.735.000
3 rd June 2015	9	6	37.745.000
05 th June 2015	10	7	57.735.000
Total			513.754.000±3-5%

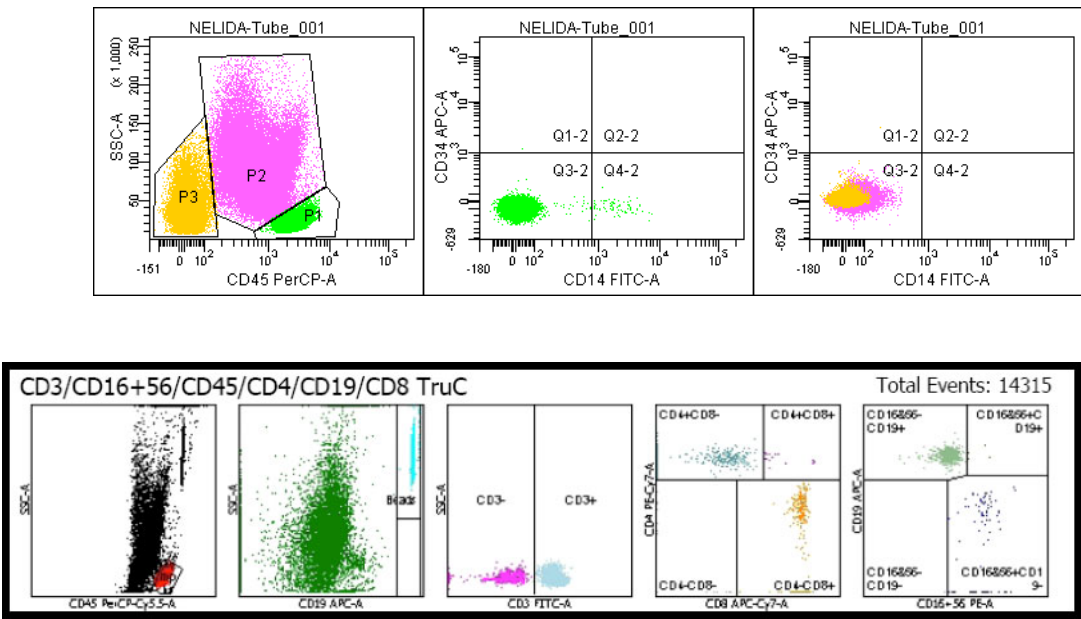


Figure 2. Flow-cytometry from patient’s peripheral blood sample after treatment (Second time). The results showed the sample positive for CD45, CD14 and CD34. CD45: P1: (green color) # 28%; P2: (violet color) # 56%; P3: (yellow color) # 16%.

Table 2. Results of lymphocytes B,T and NK from blood sample (CD16, CD56, CD19, CD3, CD4, CD8)

Cell phenotype in blood sample after stem cell therapy	Cells/ μ L	%	Range Cells/ μ L (%)
Lymph events	2475		
Bead events	1984		
Lympho T (CD3+)	905.27	71.64	0.69-2.54 x 10 ³ (55-84)
o CD4+ T-cell (CD3+CD4+CD8-)	670.91	53.09	0.41-1.59 x 10 ³ (31-60)
o CD8+ T-cell (CD3+CD8+CD4-)	243.55	19.27	0.19-1.14 x 10 ³ (13-41)
o CD3+CD4+CD8+	13.79	1.09	
Lympho B (CD19+)	154.71	12.24	
NK cells (CD56+CD16+)	189.94	15.03	
4/8 ratio		2.75	

Table 3. Results of lymphocytes B,T and NK from blood sample (CD16, CD56, CD19, CD3, CD4, CD8)

Cell phenotype	Q.ty Cells/ μ L	%	Range Cells/ μ L (%)
Lymph events	2423		
Bead events	1815		
Lympho T (CD3+)	1001.28	74.04	0.69-2.54 x 10 ³ (55-84)
o CD4+ T-cell (CD3+CD4+CD8-)	804.82	59.51	0.41-1.59 x 10 ³ (31-60)
o CD8+ T-cell (CD3+CD8+CD4-)	193.11	14.28	0.19-1.14 x 10 ³ (13-41)
o CD3+CD4+CD8+	7.81	0.58	
Lympho B (CD19+)	303.06	22.41	
NK cells (CD56+CD16+)	45.21	3.34	
4/8 ratio		4.17	

Conclusion

The present case was a very particular one where the patient presented with a very complicated scenario, old age, chronic inflammatory symptoms with erythema, purpura and constant itching accompanied by DM2, high blood pressure and hypercholesterolemia. The use of stem cells was initially used to modulate patient's chronic inflammatory-allergic state as at the beginning we were completely unaware about her *T gondii* parasitic infection. Pluripotent and pluripotent stem cells such as ESCs, MSCs or HSCs are provided of low immunogenicity and immune-modulating properties conferred by their unique biological nature that can also be found secreted in their microenvironment acting on different cells of the immune system that protect them from cytotoxic effects [Berman et al., 2010; Ding et al., 2009; Fiorina et al., 2009], 36,37]. Intriguingly, flow-cytometry analysis on PB-SCs from the patient after the treatment have shown a strong presence of humoral immunity cells such as CD3, CD4 and CD8, CD19 and CD16 and CD56 cells. This would suggest that PB-SCs may exert a direct impact on the immune system cellular and humoral components development and mobility and that these cells may eventually contribute to the regeneration process of damaged tissues under an indirect influence of organized stem cells. Here, we raise up the feasible implication of autologous PB-SCs and their secreted factors via stimulation of immune cells and inflammatory cytokines reparative mechanisms, as also confirmed by a previous study conducted by our team (Gargiulo et al., 2015). We highlight clinical implications that are amenable to immune-mediated regeneration such as parasite infection and metabolic disorders as DM2, suggesting more immune targeting strategies for both tissue regeneration and immune-modulation through the use of stem cells. However, we are well aware that many studies are needed to strongly establish the role of stem cells upon immune system cells in both allogeneic and autologous settings in long-term transplantation (Aurora and Olson, 2014; Nehlin et al., 2011).

Consent

Written informed consent was obtained from the patient for publication of this case report. A copy of the written consent is available for review by the Editor-in-Chief of this journal.

References

- Angel SO, M.M., Margarit J, Nigro M, Illescas E, Pszeny V, Amendoeira MR, Guarnera E, Garberi JC. J Clin Microbiol (1997). Screening for active toxoplasmosis in patients by DNA hybridization with the ABGTg7 probe in blood samples. *J Clin Microbiol* 35, 591.
- Attal, M., Harousseau, J.-L., Stoppa, A.-M., Sotto, J.-J., Fuzibet, J.-G., Rossi, J.-F., Casassus, P., Maisonneuve, H., Facon, T., Ifrah, N., et al. (1996). A Prospective, Randomized Trial of Autologous Bone Marrow Transplantation and Chemotherapy in Multiple Myeloma. *New England Journal of Medicine* 335, 91-97.
- Aurora, Arin B., and Olson, Eric N. (2014). Immune Modulation of Stem Cells and Regeneration. *Cell Stem Cell* 15, 14-25.
- Bachereau T, S.R. (1998). Dendritic cells and the control of immunity. *Nature* 392, 245-252.
- Berman, D.M., Willman, M.A., Han, D., Kleiner, G., Kenyon, N.M., Cabrera, O., Karl, J.A., Wiseman, R.W., O'Connor, D.H., Bartholomew, A.M., et al. (2010). Mesenchymal Stem Cells Enhance Allogeneic Islet Engraftment in Nonhuman Primates. *Diabetes* 59, 2558-2568.
- Bezwooda, W.R., Seymour, L., and Dansey, R.D. (1995). 349 High dose chemotherapy with hematopoietic rescue as primary treatment for metastatic breast cancer: A randomised trial. *European Journal of Cancer* 31, S76.
- Bhansali, A., Upreti, V., Khandelwal, N., Marwaha, N., Gupta, V., Sachdeva, N., Sharma, R.R., Saluja, K., Dutta, P., Walia, R., et al. (2009). Efficacy of Autologous Bone Marrow-Derived Stem Cell Transplantation in Patients With Type 2 Diabetes Mellitus. *Stem Cells and Development* 18, 1407-1416.
- Damiani, D., Stocchi, R., Masolini, P., Michelutti, A., Sperotto, A., Geromin, A., Skert, C., Cerno, M., Michieli, M., Baccarani, M., et al. (2002). Dendritic cell recovery after autologous stem cell transplantation. *Bone Marrow Transplant* 30, 261-266.
- Di Nicola M, L.R. (2000). Dendritic cells: specialized antigen presenting cells. *Haematologica* 85, 202-207.
- Ding, Y., Xu, D., Feng, G., Bushell, A., Muschel, R.J., and Wood, K.J. (2009). Mesenchymal Stem Cells Prevent the Rejection of Fully Allogeneic Islet Grafts by the Immunosuppressive Activity of Matrix Metalloproteinase-2 and -9. *Diabetes* 58, 1797-1806.
- Estrada, E.J., Valacchi, F., Nicora, E., Brieva, S., Esteve, C., Echevarria, L., Froud, T., Bernetti, K., Cayetano, S.M., Velazquez, O., et al. (2008). Combined Treatment of Intrapancratic Autologous Bone Marrow Stem Cells and Hyperbaric Oxygen in Type 2 Diabetes Mellitus. *Cell Transplantation* 17, 1295-1304.
- Fiorina, P., Jurewicz, M., Augello, A., Vergani, A., Dada, S., La Rosa, S., Selig, M., Godwin, J., Law, K., Placidi, C., et al. (2009). Immunomodulatory Function of Bone Marrow-Derived Mesenchymal Stem Cells in Experimental Autoimmune Type 1 Diabetes. *The Journal of Immunology* 183, 993-1004.
- Fong MY, W.K., Rohela M, Tan LH, Adeeba K, Lee YY, Lau YL (2010). Unusual manifestation of cutaneous toxoplasmosis in a HIV-positive patient. *Tropical Biomedicine* 27(3), 447-450.
- Gargiulo, C., Pham, V.H., Thuy Hai, N., Nguyen, K.C.D., Phuc, P.V., Abe, K., Flores, V., and Shiffman, M. (2015). Isolation and Characterization of Multipotent and Pluripotent Stem Cells from Human Peripheral Blood. *Stem Cell Discovery* 05, 19-32.
- Guillaume, T., Rubinstein, D.B., Zaner, K.S., Humblet, Y., and Symann, M. (1999). Autologous peripheral blood stem cell transplantation for lung cancer. *Best Practice & Research Clinical Haematology* 12, 233-246.
- Hoffman A, Z.G., Miller M (2008). Case report and review of the literature: Toxoplasma gondii encephalitis in a 40-year-old woman with

common variable immunodeficiency and a new diagnosis of large granular lymphocytic leukemia, pp. 309-310.

Humblet Y, S.M., Bosly A, Delaunois L, Francis C, Machiels J, Beauduin M, Doyen C, Weynants P, Longueville J, Prignot J (1987). Late intensification chemotherapy with autologous bone marrow transplantation in selected small cell carcinoma of the lung: A randomized study. *Journal of Clinical Oncology. Journal of Clinical Oncology* 5, 1864.

Karnieli, O., Izhar-Prato, Y., Bulvik, S., and Efrat, S. (2007). Generation of Insulin-Producing Cells from Human Bone Marrow Mesenchymal Stem Cells by Genetic Manipulation. *Stem Cells* 25, 2837-2844.

Koblas, T., Pektorova, L., Zacharovova, K., Berkova, Z., Girman, P., Dovolilova, E., Karasova, L., and Saudek, F. (2008). Differentiation of CD133-Positive Pancreatic Cells Into Insulin-Producing Islet-Like Cell Clusters. *Transplantation Proceedings* 40, 415-418.

Liesenfeld, O., Montoya, Jose G., Kinney, S., Press, C., and Remington, Jack S. (2001). Effect of Testing for IgG Avidity in the Diagnosis of *Toxoplasma gondii* Infection in Pregnant Women: Experience in a US Reference Laboratory. *The Journal of Infectious Diseases* 183, 1248-1253.

Lu, D., Chen, B., Liang, Z., Deng, W., Jiang, Y., Li, S., Xu, J., Wu, Q., Zhang, Z., Xie, B., et al. (2011). Comparison of bone marrow mesenchymal stem cells with bone marrow-derived mononuclear cells for treatment of diabetic critical limb ischemia and foot ulcer: A double-blind, randomized, controlled trial. *Diabetes Research and Clinical Practice* 92, 26-36.

Madec, A.M., Mallone, R., Afonso, G., Abou Mrad, E., Mesnier, A., Eljaafari, A., and Thivolet, C. (2009). Mesenchymal stem cells protect NOD mice from diabetes by inducing regulatory T cells. *Diabetologia* 52, 1391-1399.

Masters, B.R. (2015). Mandell, Douglas, and Bennett's Principles and Practice of Infectious Diseases, Eighth Edition (2015) Eds: John E. Bennett, Raphael Dolin, Martin J. Blaser. ISBN: 13-978-1-4557-4801-3, Elsevier Saunders. *Graefes Arch Clin Exp Ophthalmol*.

Masur, P.b.H. (2002). Guidelines for Preventing Opportunistic Infections among HIV-Infected Persons—2002: Recommendations of the U.S. Public Health Service and the Infectious Diseases Society of America*. *Annals of Internal Medicine* 137, 435.

Mrusek, S., Marx, A., Kummerle-Deschner, J., Tzaribachev, N., Enders, A., Riede, U.N., Warnatz, K., Dannecker, G.E., and Ehl, S. (2004). Development of granulomatous common variable immunodeficiency subsequent to infection with *Toxoplasma gondii*. *Clinical and Experimental Immunology* 137, 578-583.

Nehlin, J., Isa, A., and Baringto, T. (2011). Immunogenicity and Immune-Modulating Properties of Human Stem Cells. In *Stem Cells in Clinic and Research (InTech)*.

Philip, T., Guglielmi, C., Hagenbeek, A., Somers, R., Van Der Lelie, H., Bron, D., Sonneveld, P., Gisselbrecht, C., Cahn, J.-Y., Harousseau, J.-L., et al. (1995). Autologous Bone Marrow Transplantation as Compared with Salvage Chemotherapy in Relapses of Chemotherapy-Sensitive Non-Hodgkin's Lymphoma. *New England Journal of Medicine* 333, 1540-1545.

Porter, S.B., and Sande, M.A. (1992). Toxoplasmosis of the Central Nervous System in the Acquired Immunodeficiency Syndrome. *New England Journal of Medicine* 327, 1643-1648.

Shachor, J., Shneyour, A., Radnay, J., Steiner, Z.P., and Bruderman, I. (1984). Toxoplasmosis in a Patient with Common Variable Immunodeficiency. *THE AMERICAN JOURNAL OF THE MEDICAL SCIENCES* 287, 36-37.

Shivanshankar M, M.D. (2011). A brief overview of diabetes. *International Journal of Pharmacy and Pharmaceutical Science* 3(4), 22-27.

Taila, A.K., Hingwe, A.S., and Johnson, L.E. (2011). Toxoplasmosis in a patient who was immunocompetent: a case report. *J Med Case Rep* 5, 16.

Thierry G, R.D., Symann M (1992). Immune Reconstitution and Immunotherapy After Autologous Hematopoietic Stem Cell Transplantation. *Blood* 92(5), 1471-1490.

Torre D, C.S., Speranza F, Donisi A, Gregis G, Poggio A, Ranieri S, Orani A, Angarano G, Chiodo F, Fiori G, Carosi G (1998). Randomized trial of trimethoprim sulfamethoxazole versus pyrimethamine-sulfadiazine for therapy of toxoplasmic encephalitis in patients with AIDS. *Antimicrobial Agents and Chemotherapy* 42, 1346-1349.

Volarevic, V., Al-Qahtani, A., Arsenijevic, N., Pajovic, S., and Lukic, M.L. (2010). Interleukin-1 receptor antagonist (IL-1Ra) and IL-1Ra producing mesenchymal stem cells as modulators of diabetogenesis. *Autoimmunity* 43, 255-263.

Volarevic, V., Arsenijevic, N., Lukic, M.L., and Stojkovic, M. (2011). Concise Review: Mesenchymal Stem Cell Treatment of the Complications of Diabetes Mellitus. *STEM CELLS* 29, 5-10.

Xie, Q.-P., Huang, H., Xu, B., Dong, X., Gao, S.-L., Zhang, B., and Wu, Y.-L. (2009). Human bone marrow mesenchymal stem cells differentiate into insulin-producing cells upon microenvironmental manipulation in vitro. *Differentiation* 77, 483-491.

Zhang, Y., Mi, J.-Y., Rui, Y.-J., Xu, Y.-L., and Wang, W. (2013). Stem cell therapy for the treatment of parasitic infections: is it far away? *Parasitology Research* 113, 607-612.

Zittoun, R.A., Mandelli, F., Willemze, R., de Witte, T., Labar, B., Resegotti, L., Leoni, F., Damasio, E., Visani, G., Papa, G., et al. (1995). Autologous or Allogeneic Bone Marrow Transplantation Compared with Intensive Chemotherapy in Acute Myelogenous Leukemia. *New England Journal of Medicine* 332, 217-223.

Cite this article as:

Gargiulo, C., Pham, V., Nguyen, K., Kim, N., Nguyen, T., Luu, A., Abe, K., & Shiffman, M. (2015). Toxoplasmosis Gondii Infection and Diabetes Mellitus Type 2 Treated by Using Autologous Peripheral Blood Stem Cells a Unique Case Report of a Caucasian 83 Year Old Lady. *Biomedical Research And Therapy*, 2(8): 339-346.