A MODERN TREATMENT OF BILATERAL OSTEOCHONDRITIS DISSECANS IN KNEES: FROM A CASE REPORT TO LITERATURE'S REVIEW

Marco Corzani*, **Luigi Meccariello****, **Michele Bisaccia***, **Pellegrino Ferrara***, **Giuseppe Rinonapoli***, **Luigi Piscitelli***, **Maria Liberata Meccariello**◊ and Auro Caraffa***

*Division of Orthopedics and Trauma Surgery, University of Perugia, Santa Maria della Misericordia Hospital, Perugia, Italy., **Department of Medical and Surgical Sciences and Neuroscience, Section of Orthopedics and Traumatology, University of Siena, University Hospital "Santa Maria alle Scotte", Siena, Italy., ◊School of Medicine and Surgery, IInd University of Naples, Caserta, Italy.

ABSTRACT

Background Osteochondritis dissecans (OCD) is an idiopathic disease due to a subchondral bone necrosis that generally affects the medial femoral condyle as well as above lying cartilage. The incidence of patients with OCD of the knee aged 6 to 19 years was 9.5 per 100,000 overall and 15.4 and 3.3 per 100,000 for male and female patients, respectively. Bilateral lesions occur in at least 10-12 % of the OCD patients. The typical patient is male (70%), between 6 and 19 years of age who has participated in organized sports, and overall 20-40% of all cases have a history of knee trauma. The etiology has been hypothesized as being multi-factored due to traumas or microtraumas along with metabolic, endocrine and genetic disorders leading to subchondral necrosis. **Description of case** A 15-year old male amateur soccer player presented to our department complaining of recurrent episodes of pain at rest in both knees, swelling and articular blockage occurring over the past three years. RX and MRI revealed bilateral lesions on both medial condyles. An innovative one-time surgical technique was performed to resolve the disease. **Conclusion** Here, we describe a rare case of bilateral OCD of the knees where each of the osteochondral lesions was evaluated taking into account results from a physical exam, imaging, and arthroscopy. The patient underwent a surgical approach that incorporated both the withdrawal and transplant of stems into the lesions, the rationale of the "one-time technique" is based on the idea to transfer into the lesion site the entire bone marrow cellular pool; this allows not to loose "regenerative potential" present in the bone marrow and cells to be processed directly in the operating room without the need for a laboratory phase. A radiograph performed at six months showed remarkable results concerning tissue response. This case further highlights past cases regarding results, while it distinguishes itself for the fact that it has been performed on bilateral knees lesions.

KEYWORDS: Osteochondritis dissecans(OCD); ICRS Classification; Bone Marrow, Derived Mesenchymal stem cells (BMDC), Knee, Arthroscopic; Scaffold.

DOI:10.5455/ijsm-treatment-osteocondrithisdissecans-bilateral-knee
First Received: June 07, 2016
Accepted: September 15, 2016
Manuscript Associate Editor: George Baitchev (BG)
Editor-in Chief: Ivan Inkov (BG)
Reviewers: Sergej Thiele (DE); Ralf Henkelmann (DE); Jelle Gorter (NL); Luis Mendoza (BE)

[1]Luigi Meccariello, MD, Department of Medical and Surgical Science, and Neuroscience, Section of Orthopoedics and Traumatology, University of Siena, University Hospital "Santa Maria alle Scotte", Viale Bracci 1, 53100 Siena, Italy. E-mail: drlordmec@gmail.com

Introduction

Osteochondritis dissecans (OCD) is an idiopathic disease, most frequent in adolescents or young adults, due to a subchondral bone necrosis that affects the medial femoral condyle as well as above lying cartilage [1]. The incidence of patients with OCD of the knee aged 6 to 19 years was 9.5 per 100,000 overall and 15.4 and 3.3 per 100,000 for male and female patients, respectively. Bilateral lesions occur in at least 10-12% of the OCD patients[2,3]. The etiology has been supposed as being multi-factored due to either traumas or microtraumas as well as metabolic, endocrine and genetic disorders and leading to subchondral ischemia [1]. The typical patient is male (70%), between 6 and 19 years of age who has participated in organized sports, and overall 20-40% of all cases have a history of knee trauma. The knee is most common sight of OCD (75% of all cases) and afflicting the medial femoral condyle (63,6%) especially in the post-lateral portion, the lateral condyle (32,5%), the trochlear, and patella [1-4].

The classification universally used is ICRS (International Cartilage Repair Society) [5]. The cartilage lesions can be difficult to diagnose as they can be asymptomatic moreover, their symptoms, when present, are shared by other illnesses; therein leading to misdiagnosis. Symptoms include swelling and pain following physical activity; wide lesions can block articulation and in several causes episodes of knee, instability is reported. Mesenchymal stem cells (MSCs) of bone marrow, when utilized in suitable environments can differentiate between cartilage and bone as well as replicate spontaneously, therein avoiding cultivation in the laboratory. [6-7].

Moreover, MSCs can be conveniently implanted after having eliminated the red blood cells while at the same time the growth factors can be left during surgery. This one-step technique is indicated for treating chondral lesions of the femur in the III and IV stages according to either the ICRS Scale.

One-time surgery for osteochondral lesions of the knee using Mesenchymal stem cells (mscs)

Exclusion criteria in this type of treatment are age<15 and >50, severe osteoarthritis, diabetes, rheumatoid arthritis, as well as blood diseases and infections of the knee. Following this, mesenchymal bone marrow cells are entracted from the anterior iliac crest while the patient is supine and under either general or spinal anesthesia. This technique was made for a first time in IOR by Prof. Giannini in 2013 [8].

It has been over 40 years since Dr. Alexander Friedenstein first characterized mesenchymal stem cells. They were initially recognized in bone marrow and displayed plasticity and multipotency. Similar cells have been shown to be present in other tissues including peripheral blood, cord blood, skeletal muscle, heart, and adipose tissue [9-10].

The presence of these cells within other tissues has meant that they are perhaps more accurately described as mesenchymal stromal cells (MSCs) are observed to suppress inflammatory T–cell proliferation, and inhibit maturation of monocytes and myeloid dendritic cells resulting in an immunomodulatory and anti-inflammatory effect. This immunomodulatory mechanism raises potential for their use in auto-immune mediated inflammatory conditions including inflammatory arthropathies [11].

Step 1 bone marrow aspiration

A total of 60 mL bone marrow aspirate was taken from the anterior iliac crest, under general anesthesia. The bone marrow harvesting was performed with a marrow needle (size 11G, 9 100 mm) inserted 3 cm deep into the iliac crest marrow. In according to IOR and his article [8], five mL of bone marrow was aspirated into a 20-mL plastic syringe internally coated with the calcium-heparin solution, repeating the procedure with several perforations into the iliac crest through the same skin opening, until a total of 60 mL of bone marrow aspirate was collected. Each withdrawn of marrow was aspirated in small fractions from different points to maximize the harvesting of the marrow stromal cells and to reduce dilution by peripheral blood. After each withdrawal, the 5ml of bone marrow is immediately injected into a sack containing 500IU of heparin and 10 ml of saline solution(NACl 0.9% concentrated).

Step 2 Bone marrow concentration We performed similar procedure of the article of Mr. Vega et al. [12] The harvested bone marrow was treated directly in the operating room by using cell separator machine (IOR-G1, Novagenit, Mezzolombardo, TN, Italy) [Fig.1] to concentrate the bone marrow by removing most of the erythrocytes and plasma, preserving growth factors inside. The machine provides 6ml of concentrated fluid after 15 min of multiple cycle centrifuge, [8], with a single use sterilization kit. Two mililiters of this bone marrow concentrate is positioned on a hyaluronic acid membrane (Hyalofast, FidiaAdvanced Biopolymers, Italy) or collagen membrane (IOR-G1, Novagenit, Mezzolombardo, TN, Italy). The remaining part of the concentrate is used as a reserve. There is not an accepted protocol to control if the concentrated fluid has the constant concentration of stem cells and grow factors.

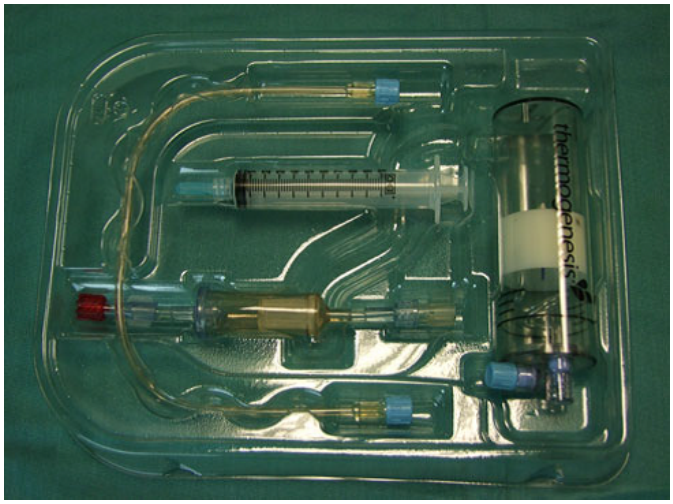

Figure 1: The IOR-G1 disposable kit is used for the cell concentration directly in our institute.

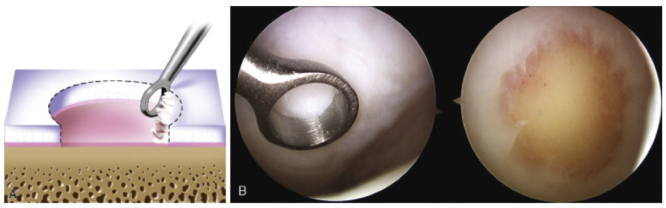

Figure 2: Arthroscopic chondral lesion.

Step 3 After the bone marrow harvesting phase, a standard knee arthroscopy was performed with the patient in the supine

position, carried out to define the margins and assess the level of chondral damage, [Fig 2] by searching for the presence of a free intra-articular fragment. The chondral lesion was of 3-4 rd grade of IKDC score.

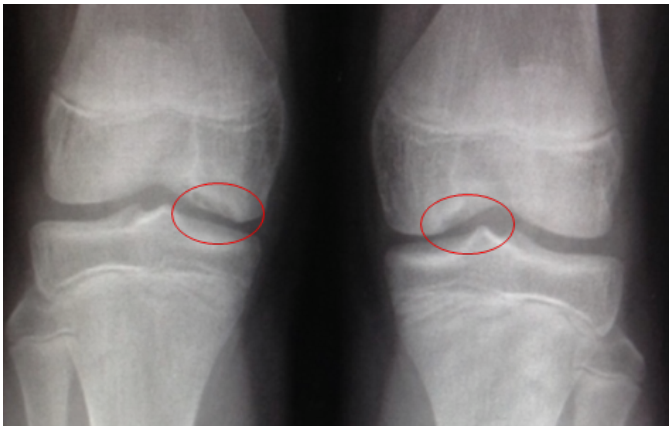

Figure 3: AP radiographs revealed an ample loss of substance at the medial condyles.

Step 4: Transplant of Bone Marrow Concentration After arthroscopic phase, we continued with an arthrotomy of the knee in the surgery same time to improve the access of the surgery, a drill is used to debride the lesion, resulting in a circular area with regular healthy cartilage, suitable for the transplantation of biomaterials. The scaffold was filled with two mL of bone marrow concentrate and loaded onto the delivery device, which was used to position the biomaterial within the defect, multiple stamp-sized pieces of the membrane can be overlapped to cover the whole area. Ultimately the knee is extended and flexed to assess the stability of implanted stamps. This type of treatment has been done on each knee lesion in the surgery same time.

Post-surgery treatment The rehabilitation was articulated in

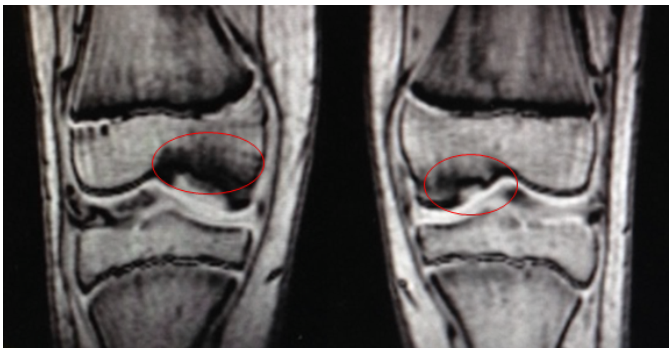

Figure 4: MRI revealed an ample loss of substance, resulting in an ICRS score of III-IV.

different stages:

1.The day after surgery: gradual passive mobilization of the knee with no weight-bearing.

2.Four weeks after the surgery: muscular reinforcement exercises, closed kinetic chain proprioceptive rehabilitation, static and walking exercises with partial and gradual weight-bearing, swimming but no frog style.

3.Ten weeks after the surgery: open kinetic chain rehabilitation exercises recovery of muscular function and walking with full weight-bearing, cycling.

4.Six months after the surgery: light running.

5.Twelve months after the surgery: high impact sports.

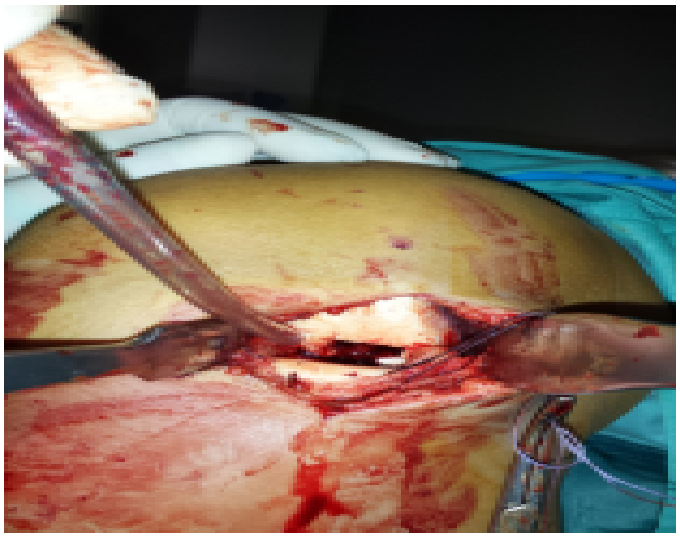

Right knee arthrotomy

Left knee arthrotomy

Figure 5: The arthrotomy performed evidenced that the chondral defects were circa 2.5 x 1.5 cm on the right and circa 2 x 1 cm on the left knee.

Clinical follow-up

The first scheduled follow-up is at 30 days from surgery, with subsequent follow-ups every 30 days thereafter until the patient has returned to sporting activities. To precisely quantify clinical improvement, the International Knee Documentation Committee (IKDC) or Knee Injury and Osteoarthritis Outcome (KOOS) and VAS scales are recommended [6,13]. An MRI scan is performed on all patients before surgery and at 9, 12 and 36 months post-surgery.

Case report

Here we describe a case of OCD treated with a new regenerative technique. A 15-year-old male presented to our department in apparent good health and reported no history of trauma or surgeries complaining of recurrent episodes of pain at rest in both

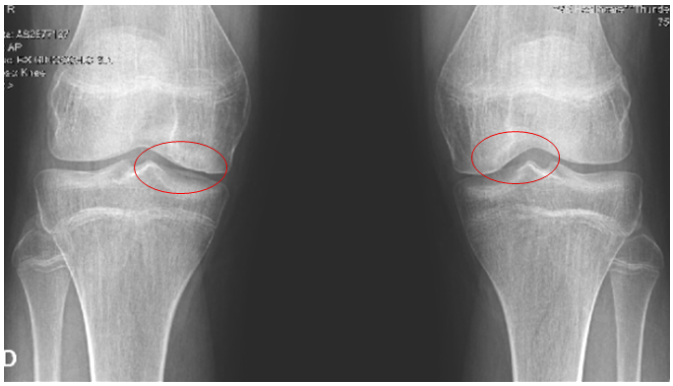

Figure 6: Rx evidence of the lesions healing at six months from surgery.

knees, swelling and articular blockage occurring over the past three years. The patient referred the event as coinciding with the recent initiation of intense and regular physical activity as an amateur soccer player; VAS score 7, IKDC scores 40,3. Both AP radiographs and MRI revealed an ample loss of substance at the medial condyles in the load zone (fig. 3,4), resulting in an ICRS score of III-IV. An arthroscopy before surgery showed no presence of intrarticular fragments or ulterior lesions due to ligaments, meniscus or other articular structures. The arthrotomy performed subsequently evidenced that the chondral defects were circa 2.5 x 1.5 cm on the right and circa 2 x 1 cm on the left (fig. 5). The patient underwent the one-step technique for the autologous transplant of bone marrow stem cells in everyone lesion. After surgery, the patient was prescribed to wear two braces at 0 degrees for 15 days with 20-degree increases every seven days until the brace could be removed. Since the first day after surgery, the braces could be temporary removed 3-4 times every day to do passive and active flexion-extension movements. At fifteen days post-surgery, the patient was permitted to partially load his body weight on two crutches.

At 30 days from surgery, the patient complained some self-limiting and expected symptoms like pain and slight stiffness at getting up in the morning and after prolonged periods of immobility of the limbs. Swelling was not referred.VAS score was 5, and IKDC score was 62.

At 90 days post-surgery, an 80% recovery of muscle tone was observed, compared to the statement prior to surgery, in the absence of stiffness and pain during movement. At this time, the patient was allowed to move his treated limb freely.VAS score was 3; IKDC score was 73. At six months a complete recovery of the muscular tone was evidenced. Return to running activity was allowed but without any participation in contact sports. A control radiograph performed at six months post-surgery observed a marked improvement, particularly in the right medial condyle which was the site of the largest lesion. (fig. 6)

Discussion

This technique and its related advantages is currently being widely discussed in the literature. A comparison with similar methods, particularly autologous chondrocytes transplantation (ACI). Is merited here to clarify its role better: ACI is considered to be one of the most advanced for the treatment of cartilage tissues, as it has been shown to regenerate the damaged tissue thanks to a neoapposition of the cartilage with properties similar to those of the healthy tissue, superior with regards to biomechanics compared to cartilage regenerated from micro-factures [14,15]. Numerous clinical results have been published based on long-term follow-ups following arthrotomy and more recently with techniques entirely arthroscopic [16-19].

Preclinical trials using techniques similar to ACI, but substituting the chondrocytes with MSCs, have shown positive results with formation of tissue with histological properties consistent with hyaline cartilage and a high type II collagen presence [20] Wakitani and colleagues are successfully transplanted isolated MSCs - seeded onto a type I collagen network - to an area of the chondral defect, resulting in successful filling of the defect. Later biopsy at two years indicated hyaline-like cartilage with type II collagen on histological evaluation.

Nejadnkik and colleagues published their results of a comparative cohort study assessing both the safety and efficacy of bone marrow MSC impregnated scaffolds (n=36) in direct comparison to autologous chondrocyte transplantation (n=36) for an isolated chondral defect. There was no difference between these groups in clinical outcome. [21,22]

The use of MSC-based therapy in conjunction with the accepted surgical technique of microfracture has been explored in a surgically induced isolated chondral goat lesion model. Post microfracture intra-articular injections of bone marrow aspirate (BMA) in combination with hyaluronic acid resulted in both improved integration of tissue and superior quality of tissue repair with type II collagen represented on histology. [23]

Kuroda and colleagues successfully treating a femoral condyle cartilage defect with autologous bone marrow MSCs, showing repair with 'hyaline-like' tissue at later arthroscopy and biopsy. [24] Extending upon the observed positive preclinical outcome of the use of MSCs in conjunction with arthroscopic techniques, Saw and colleagues have recently published a randomized controlled trial involving the use of peripheral blood MSCs in combination with arthroscopic microfracture/microdrilling of chondral lesions. Importantly, the participant group receiving MSCs showed significant improvement in the quality of articular cartilage repair (by histological and MRI evaluation) in comparison to the control group that underwent microfracture and hyaluronic acid injections alone [25]. Intra-articular injections of MSCs have resulted in pain and functional improvement in some preclinical and clinical trials. Importantly, recent limited case series evidence has shown regrowth of cartilage volume and disease modification following MSC injections. While recognizing the low level of scientific evidence (Level IV), a significant increase in cartilage volume in an accepted degenerative and progressive condition represents an exciting development.

Despite this, the necessity to perform within this procedure two distinct and costly operations along with a long phase for cellular expansion in the laboratory[26] has conditioned the interest of the scientific community regarding methods that unite the two surgical procedures. The most current of these alternatives is the technique that we have utilized which permits to extract and concentrate the cells directly in the operating room by skipping the culture phase and eliminating the two operating times required for the ACI [27] technique; therein reducing costs. Concerning the treatment of similar lesions, the results between the two methods are comparable [28,29]: IKDC and KOOS scores for the pre-surgery and pre-follow-up period ($p<0,0005$)[30]are similar, while for patients who underwent additional surgeries for other correlated pathologies, a delay in clinical improvement

was recorded to be from 6 to 12 months. However, data on final follow resulted being similar between the two groups [31]. MRI at post-surgery observed a regeneration of bone tissue and cartilaginous with a resolution of the chondral defect, evidencing a satisfactory integration of the regeneration at follow-up in 80% of the cases [32]. Similar results have been reported regarding bioptic samples taken from patients in the post-surgery period where it was possible to note the presence of regenerated cartilaginous tissue in an advanced remodeling phase [33]. Next to the right results of this technique,there are some aspects that needs definition,one of those is what can be the best source for mesenchymal cell sampling: stem cell in membrane and synovial fluid, periosteum, trabecular bone, adipose tissue, cutis, muscles,and umbilical cord [34] have different yields, differentiation properties, and needs more studies about the method for obtaining them and coulture, that limit their clinical use [35-39].

Another aspect to define is the quality of withdrawn bone marrow cells and the correct concentration of MSCs to apply for an optimal result. Currently, data on dose and response lack for cartilaginous regeneration. Moreover, literature reports on varying quantities of transplanted cells which renders a comparison among outcomes very difficult. The activation of transplanted mesenchymal cells in experimental defected cartilage using various scaffolds in the presence of combined growth factors including TGF-β, BMP-2,BMP-4 and PDGF [40-43] has lead to greater improvement in lesion repair, compared to scaffolds without these growth factors. A complete regeneration of the cartilage has not yet been achieved with these methods suggesting a lack of understanding regarding the role of growth factors in differentiating stem cells.

Conclusion

Here, we describe a rare case of bilateral OCD of the knees where each of the osteochondral lesions was evaluated taking into account results from a physical exam, imaging, and arthroscopy. The patient underwent a surgical approach that incorporated both the withdrawal and transplant of stems into the lesions, the rationale of the "one-time technique" is based on the idea to transfer into the lesion site not only mesenchymal stem cells, but the entire bone marrow cellular pool;this allows not to loose "regenerative potential" present in the bone marrow and cells to be processed directly in the operating room without the need for a laboratory phase.A radiograph performed at six months showed noteworthy results concerning tissue response.This case further highlights past cases regarding results, while it distinguishes itself for the fact that has been performed on bilateral knees lesions.

Authors' Statements

Competing Interests

All authors disclose any financial and personal relationships with other people or organisations that could inappropriately influence (bias) their work. Examples of potential conflicts of interest include employment, consultancies, stock ownership, honoraria, paid expert testimony, patent applications/registrations, and grants or other funding.

Human And Animal Right: For this type of study is not required any statement relating to studies on humans and animals. All patients gave the informed consent prior being included into the study. All procedures involving human participants were by the 1964 Helsinki declaration and its later amendments.

References

1. Shea KG, Jacobs JC Jr, Carey JL, Andreson AF, Oxford JT: Osteochondritis dissecans knee histology studies have variable findings and theories of 75 etiology. Clin OrthopRelat Res 2013; 471(4):1127-36.

2. Kessler JI, Nikizad H, Shea KG, Jacobs JC Jr, Bebchuk JD, Weiss JM: The demographics and the epidemiology of the Osteochondritis dissecans of the knee in children and adolescents. Am J Sports Med. 2014 Feb;42(2):320-6.

3. Brandon J. Erickson, Peter N. Chalmers, Adam B. Yanke, and Brian J. Cole.Surgical management of Osteochondritis dissecans of the knee. CurrRevMusculoskeletMed. 2013 Jun; 6(2): 102–114. Published online 2013 Feb 3.

4. Jacobs JC Jr, Archibald-Seiffer N, Grimm NL, Carey JL, Shea KG: A Review ofArthroscopic Classification Systems for Osteochondritisdissecans of the Knee.Clin Sports Med 2014; 2:189-197.

5. Brittberg M: Clinical evaluation of cartilage defects and repair.Proceedings of the3rd Symposium of International Cartilage Repair Society in the New Millennium (2000).

6. Buda R, Vannini F, Cavallo M, Baldassarri M, Luciani D, Mazzotti A, Pungetti C, Olivieri A, Giannini S: One-step arthroscopic technique for the treatment of osteochondral lesions of the knee with bone-marrow-derived cells: three years results. MusculoskeletSurg 2013; 97(2):145-51.

7. Veronesi F, Giavaresi G, Tschon M, Borsari V, NicoliAldini N, Fini M: Clinical use of bone marrow, bone marrow concentrate, and expanded bone marrow mesenchymal stem cells in cartilage disease. Stem Cells Dev 2013; 15;22(2):181-92.

8. Buda R, Vannini F, Cavallo M, Baldassarri M, Luciani D, Mazzotti A, Pungetti C, Olivieri A, Giannini S. One-step arthroscopic technique for the treatment of osteochondral lesions of the knee with bone-marrow-derived cells: three years results. Musculoskelet Surg. 2013 Aug;97(2):145-51. doi: 10.1007/s12306-013-0242-7.

9. Vaananen HK. Mesenchymal stem cells. Ann Med. 2005;37(7):469–79.

10. Barry FP, Murphy JM. Mesenchymal stem cells: clinical applications and biological characterization. Int J Biochem Cell Biol. 2004;36(4):568–84.

11. Djouad F, Bouffi C, Ghannam S, et al. Mesenchymal stem cell: innovative therapeutic tools for rheumatic diseases. Nat Rev Rheumatol. 2009;5:392–9.

12. Vega A, Martín-Ferrero MA, Del Canto F, Alberca M, García V, Munar A, Orozco L, Soler R, Fuertes JJ, Huguet M, Sánchez A, García-Sancho J.Treatment of Knee Osteoarthritis with Allogenic Bone Marrow Mesenchymal Stem Cells; A Randomized Controlled Trial.

13. Irrgang JJ, Andreson AF,Boland AL, et al.: Development and validation of the International Knee Committee subjective knee form. Am J Sports Med 2001;29(5):600-613.

14. Peterson L, Minas T, Brittberg M, Lindahl A: Treatment of osteochondritis dissecans of the knee with autologous chondrocyte transplantation: results at two to ten years. J Bone Joint Surg Am, 2003)+;85-A Suppl 2:17-24.

15. Saris DB, Vanlauwe J, Victor KF, Almqvist KF, Verdonk R, Bellemans J, Luyten FP, TIG/ACT/01/2000&EXT Study Group: Treatment of symptomatic cartilage defects of the knee: characterized chondrocyte implantation results in better clinical outcome at 36 months in a randomized trial compared to microfracture. Am J Sports Med 2009;37 Suppl 1:10S-19S.

16. Papaioannou G, Demetropulos CK, King YH: Predicting the effects of knee focal articular surface injury with a patient-specific finite element model. Knee 2010; 17(1):61-8.

17. Moradi B, Schonit E, Nierhoff C, Hagmann S, Oberle D, GotterbarmT, Schmitt H, Zeifang F: First-generation autologous chondrocyte implantation in patients with cartilage defects of the knee: 7 to 14 years clinical and magnetic resonance imaging follow-up evaluation Arthroscopy,(2012);28(12):1851-61.

18. Beris AE, Lykissas MG, Kostas-Agnantis I, Manoudis GN: Treatment of full-thickness condrale defects of the knee with autologous chondrocyte implantation: a functional evaluation with long-term follow-up. Am J Sports Med,(2012); 40(3):562-7.

19. Ossendorf C, Steinwachs MR, Kreuz PC, Osterhoff G, Lahm A, DucommunPP,Erggelet C: Autologous chondrocyte implantation (ACI) for the treatment of large and complex cartilage lesions of the knee.Sports Med ArthroscRehabilTherTechnol,(2011);21;3-11.

20. Grigolo B, Lisignoli G, Desando G, Cavallo C, Marconi E, Tschon M, Giavaresi G, Fini M, Giardino R. Osteoarthritis treated with mesenchymal stem cells on a hyaluronan-based scaffold in the rabbit. Tissue Eng Part C Methods. 2009;15:647–58.

21. Nejadnik H, Hui JH, Feng Choong EP, et al. Autologous bone marrow-derived mesenchymal stem cells versus autologous chondrocyte implantation: an observational cohort study. Am J Sports Med. 2010;38:1110–6.

22. Wakitani S, Imoto K, Yamamoto T, et al. Human autologous culture expanded bone marrow mesenchymal cell transplantation for repair of cartilage defects in osteoarthritic knees. Osteoarthritis Cartilage. 2002;10:199–206

23. Saw KY, Hussin P, Loke SC, et al. Articular cartilage regeneration with autologous marrow aspirate and hyaluronic acid: an experimental study in a goat model. Arthroscopy. 2009;25(12):1391–400.

24. Kuroda R, Ishida K, et al. Treatment of a full-thickness articular cartilage defect in the femoral condyle of an athlete with autologous bone-marrow stromal cells. Osteoarthritis Cartilage. 2007;15:226–31.

25. Saw KY et al. Articular cartilage regeneration with autologous peripheral blood stem cells versus hyaluronic acid: a randomized controlled trial. Arthroscopy. 2013;29(4):684–94.

26. Bosniakovski D, Mizuno M, Kim G, Ishiguro T, Okumura M, Iwanaga T, Kadosawa T, Fujinaga T: Chondrogenic differentiation of bovine bone marrow mesenchymal stemcells in cultural pellet system.ExpHematol 2004;32(5):502-9.

27. Di Martino A, Liverani L, Rainer A, Salvatore G, Trombetta M, Denaro V. Electrospun scaffolds for bone tissue engineering.MusculoskeletSurg 2011;95(2):69-80.

28. Kon E, Gobbi A, Filardo G, Delcogliano M, Zaffagnni S, Marcacci M: Arthroscopic second-generation autologous chondrocyte implantation compared with microfracture for chondral lesions of the knee: prospective nonrandomized study at five years. Am J Sports Med 2009;37(1):33-41.

29. Nejadnik H, Hui JH, Feng Choong EP, Tai BC, Lee EH: Autologous bonemarrow-derived mesenchymal stem cells versus autologous chondrocyte implantation: an observational cohort study. Am J Sports Med 2010; 38(6):1110-6.

30. Giannini S,Buda R,Vannini F,Cavallo M,Grigolo B: One-step bone marrow derived cell transplantation in talar osteochondral lesions.Clin Orthop Relat Res 2009;467(12):3307-3320.

31. Necas A, Planka L, Srnec R, Crha M, et al.: Quality of newly formed cartilaginous tissue in defects of the articular surface after transplantation of mesenchymal stem cells in a composite scaffold based on collagen I with chitosan micro- and nanofibres.Physiol Res 2010; 59(4):605-14.

32. Gobbi A, Karnatzikos G, Sankineani SR: One step surgery with multipotent stem cells for the treatment of large full-thickness condrale defects of the knee.Am J Sports Med. 2014 Mar;42(3):648-57.

33. Lodi D, Iannitti T, Palmieri B: Stem cells in clinical practice: applications and warnings. J ExpClin Cancer Res. 2011 Jan 17;30:9. doi: 10.1186/1756-9966-30-9.

34. Chen FH: Mesenchymal stem cells in arthritic diseases.Arthr Res Ther 2008;8710(5):223.

35. Frisbie DD, Lu Y, Kawcak CE, DiCarlo EF, Binette F, McIlwraith CW: In Vivo evaluation of autologous cartilage fragment-loaded scaffolds implanted into equine articular defects and compared with autologous chondrocyte implantation. Am J Sports Med 2009; 37 Suppl 1:71S-80S.

36. Koga H, Engebretsen L, Brinchmann JE, Muneta T, Sekiya I: Mesenchymal stem cell-based therapy for cartilage repair: a review.KneeSurg Sports TraumatolArthrosc 2009; 17(11):1289-97.

37. Wakitani S, Yamamoto T: Response of the donor and recipient cells in mesenchymal cell transplantation to cartilage defect.Microsc Res Terap 2002;58(1):14-8.

38. Xie X, Wang Y, Zhao C, Guo S, Liu S, Jia W, Tuan RS, Zhang C: Comparative evaluation of MSCs from bone marrow and adipose tissue seeded in PRP-derived scaffold for cartilage regeneration. Biomaterials 2012; 33(29):7008-18.

39. Zhang Y, Wang F, Chen J, Ning Z, Yang L: Bone marrow-derived mesenchymal stem cells versus bone marrow nucleated cells in the treatment of chondral defects. IntOrthop 2012; 36(5):1079-86.

40. Lee JM, Kim BS, Lee H, Im GI: In vivo tracking of mesenchymal stem cells using fluorescent nanoparticles in an osteochondral repair model.MolTher 2012;20(7):1434-42.

41. Mimura T, Imai S, Okumura N, LI L, Nishizawa K, Araki S, Ueba H, KuboM, Mori K, Matsusue Y: Spatiotemporal control of proliferation and differentiation of bone marrow-derived mesenchymal stem cells recruited using collagen hydrogel for repair of articular cartilage defects. J Biomed Mater Res B ApplBiomater 2011; 98(2):360-8.

42. Re'em T, Witte F, Willbold E, Ruvinov E, Cohen S: Simultaneous regeneration of articular cartilage and subchondral bone induced by spatially presented TGFbetaand BMP-4 in a bilayer affinity binding system. ActaBiomater 2012;8(9):3283-93.

43. Sukarto A, Yu C, Flynn LE, Amsden BG: Co-delivery of adipose-derived stem cells and growth factor-loaded microspheres in RGD-grafted N-methacrylate glycol chitosan gels for focal chondral repair. Biomacromolecules 2012;13(8):2490-502.