

PHYLLODES TUMOR OF THE BREAST: A CLINICOPATHOLOGICAL ANALYSIS FROM A SINGLE INSTITUTION

Naoual Benhmidou^{*,1}, Fadoua Rais^{*}, Fadila Kouhen^{**}, Jihan Aarab^{*}, Abdelhak Maghous^{*}, Hasna Loughlimi^{*}, Khadija Bellahammou^{***}, Hanan Elkacemi^{*}, Tayeb Kebdani^{*}, Sanaa Elmajjaoui^{*} and Nouredine Benjaafar^{*}

^{*}Department of Radiotherapy, National Institute of Oncology, Mohammed V University in Rabat, Morocco., ^{**}Department of Radiotherapy, International University Hospital Sheikh Khalifa, Casablanca, Morocco., ^{***}Department of Medical Oncology, National Institute of Oncology, Mohammed V University in Rabat, Morocco.

ABSTRACT

The aim of our study is to examine the clinical and pathological features of patients with breast phyllodes tumors and to determine features that are correlated with outcome. Forty-four phyllodes tumors were assessed. There were 11 benign, 11 borderline and 22 malignant tumors. Ten of 44 patients (22.72%) relapsed at any site. Seven patients (15.9%) had a local recurrence (LR), and three patients experienced a local and metastatic relapse. The 5-year and 10-year survival rates are 97% and 95% respectively. The five years and ten years disease free survival (DFS) are 81% and 77% respectively. Grade, histological size, margin involvement impacted disease free survival. Adjuvant radiation therapy improved local control in high-grade tumors although it did not reach significance.

KEYWORDS phyllodes tumors, recurrence, prognostic factors.

Introduction

Phyllodes tumors are rare fibroepithelial neoplasms of the breast known for their high potential to locally recur after surgical treatment. The role of adjuvant therapies remains uncertain in the lack of large studies. Our aim is to evaluate different therapeutic options as well as prognostic factors for local recurrence and survival.

Patients and Methods

This is a population-based registry that encompasses patient's data from the north and the center areas of Morocco. Between

January 2006 and December 2010, 44 patients were newly diagnosed with breast phyllodes tumors.

For each patient, we retrospectively collected information about age at diagnosis, sex symptoms, surgery type, histological features, adjuvant therapies, recurrence, and finely clinical outcomes (overall survival (OS), DFS, local control (LC)). Histopathological reports included: size of the macroscopic tumor, stromal cellularity, nuclear stromal atypia, stromal mitoses, margin (circumscribed or infiltrative), margin involvement, the presence of necrosis and the epithelial histology. Grading was established according to the World Health Organization classification [1] into benign (circumscribed margins, low cellularity, mild stromal cell atypia and a mitotic count of $\leq 2/10$ hpfs), malignant (infiltrative margins, stromal overgrowth and a mitotic count ≥ 5 per 10 hpfs) and borderline if the tumor does not satisfy criteria of benign and malignant tumors. Close margins are defined as less than 10 mm microscopically involved margins. H&E slides were reviewed to confirm the diagnosis for the doubtful cases.

All Patients were examined at 3-month intervals for the first two years after treatment, then at 6-month intervals for the next three years, then once a year afterward.

Copyright © 2016 by the Bulgarian Association of Young Surgeons

DOI:10.5455/ijsm.phyllodes-tumor-breast

First Received: July 11, 2016

Accepted: August 01, 2016

Manuscript Associate Editor: George Baytchev (BG)

Editor-in Chief: Ivan Inkov (BG)

Reviewers: Ivan Inkov (BG)

¹Naoual Benhmidou, Department of Radiotherapy, National Institute of Oncology, Mohammed V University in Rabat, Morocco Email:naoualbenhmidou@gmail.com

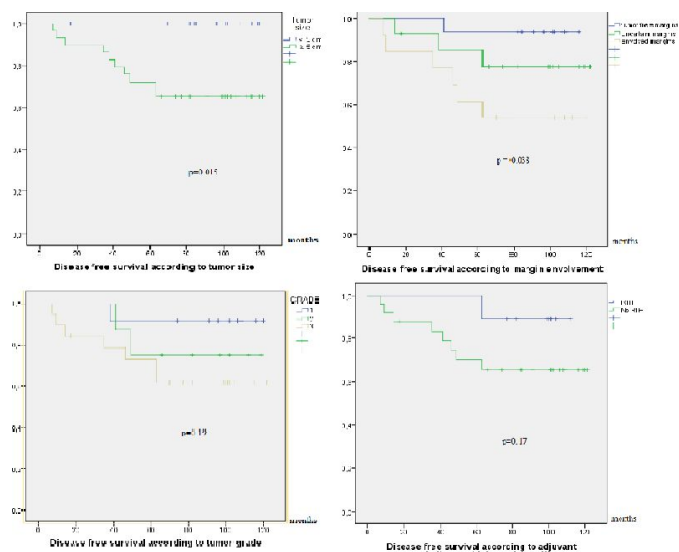


Fig.1 Prognostic factors for disease-free survival.

Statistical analysis was performed using SPSS software, version 13. Local control and patient's survival distribution was calculated using the Kaplan–Meier method. Time to recurrence was calculated from the time of histological diagnosis to the time of histological or radiographic confirmation of recurrence. Log-rank test tested the significance of the survival. Multivariate analysis was performed using the Cox proportional hazard regression. A value of p less than 0.05 was considered statistically significant.

Results

All 44 patients were female. The age at diagnosis ranged from 19 to 55 years (median 37.5 years). Of the 44 phyllodes tumors (PTs) assessed histologically, there were 11 benign, 11 borderline and 22 malignant. The tumor size ranged from 1.5 cm and 29 cm (mean 7.6 cm).

Surgery consisted of wide local excision in most of the patients ($n = 28$, 63.6%), a mastectomy in 14 patients (34%) and parietectomy (including pectoralis muscles) in one patient (2.27%). Four of the mastectomies were for pathologic margins after breast conserving surgery. Seven patients had an axillary dissection; no one had node involvement. Ten patients (25.6%) received adjuvant radiation therapy (RT), with a median total dose of 50.4 Gy (range 42 – 60 Gy) and a dose per fraction ranging between 2 Gy and 2.8 Gy to the whole breast after conservative surgery or to the chest wall after total mastectomy using two tangential high energy photon beams. None of the irradiated patients had nodal RT. The median duration of RT was 34 days (range 21– 46 days). None of the patients had adjuvant chemotherapy.

After a median follow-up of 85 months, 10 of 44 patients (22.72%) relapsed at any site. Seven patients (15.9%) had LR, and three patients experienced a local and metastatic relapse. The distribution of LR between patients whose tumors were initially benign, borderline, and malignant was 1 of 11 (9%), 2 of 11 (18.18%), and 7 of 22 (31.81%), respectively. Table 1 shows the grade and size of the tumors that recurred. Ten of the 44 patients (15%) in the study had recurrent PTs. Seven patients were salvaged by surgery either total mastectomy or parietectomy. One patient had neoadjuvant chemotherapy to

surgery (adriamycin – ifosfamide). Two patients had radiation therapy to the chest wall after surgery of the recurrence delivered at a dose of 50 Gy (2Gy/fr).

Three patients had a local and metastatic recurrence in the lung in two patients and the lung and bone in one patient. They all received Adriamycin-based chemotherapy. One patient had second line ifosfamide based chemotherapy. Two patients died from disease progression 7 and 11 months after. The last was in complete remission four months after chemotherapy. The 5-year and 10-year survival rates are 97% and 95 % respectively. The five years and ten years DFS are 81% and 77% respectively.

In univariate analysis, prognostic factors for survival (figure 1) are Histological grade (5 years local control rates of 90%, 81.8% and 68% for benign tumors, borderline, and malignant tumors, respectively; $p = 0.19$).

Histological tumor size (5 years DFS of 93% for tumor size less than 5 cm versus 68% for tumor size greater than 5 cm; $p=0.015$) and margins involvement 5 years DFS 93% for tumor free margins versus 53% for tumoral or uncertain margins $p = 0.038$).

Also, in the malignant and borderline patients' group, adjuvant radiation therapy increased the local control rate at five years, from 66.7% to 88.9% ($p = 0.17$) There is a non-statistically significant difference in survival rates according to age at diagnosis (5 years DFS of 79% for patients younger than 40 years versus 70% for older ones; $p=0.39$).

Discussion

Phyllodes tumors (PT) are rare neoplasms of the breast representing less than 1% of all primary breast tumors and 2% to 3% of fibroepithelial neoplasms of the breast and are characterized by a stromal proliferation [2,3].

Typically, phyllodes tumor present as a painless palpable mass in the breast that often enlarge rapidly may reach a very large size and can completely replace the breast tissue [4] in our series, tumor size at presentation ranged from 1 to 30 cm with a median size of 10,25cm. Mammography and ultrasound are enabled to distinguish phyllodes tumors from adenofibroma. Therefore, in the presence of a rapidly enlarged clinical fibroadenoma, an excisional biopsy should be considered to exclude a phyllodes tumor [5] histologically.

Histologically, phyllodes tumors have a biphasic pattern of stromal and epithelial components that are both indispensable to confirm the diagnosis. Breast primary tumors with pure sarcomatoid differentiation and lack of epithelial element must be considered as soft tissue sarcomas [6].The differential diagnosis also arises with adenofibroma, key distinguishing with Pt is stroma hypocellularity with few mitotic and little evidence of pleomorphism in fibroadenomas. Stroma may differentiate into other mesenchymal elements that are in order of frequency: the fibrosarcoma, liposarcoma, chondrosarcoma, osteosarcoma and muscle sarcomas. Histological diagnosis, as well as grading, requires wide macroscopic sampling especially due to the high heterogeneity of the tumors. That is why biopsy samples and more over cytology often fail to set diagnosis [7].

Stromal elements determine malignancy and predict the overall behavior of the tumor. PT are classified in benign, borderline and malignant based on histological tumor characteristics that include margins, cellularity, atypia, stromal overgrowth tumor necrosis and mitotic index. The primary aim of any grading system is to predict the risk of tumor local and metastatic recurrence. However, the existent classifications fail accurately to

Table 1 Management of recurrent phyllodes tumors and factors associated to relapse.

Primary grade	Size of primary (cm)	Time to local recurrence (months)	Grade of recurrence	Treatment of recurrence
1	10	37.5	2	Surgery (mastectomy)
2	7	41	2	Surgery (mastectomy)
3	8	35.3	3	Surgery (mastectomy)
2	10.5	49	2	Surgery (parietectomy) - Radiotherapy
3	7	63.36	3	Chemotherapy - parietectomy - Radiotherapy
3	30	45.7	3	Chemotherapy
3	12.5	45.33	3	Chemotherapy
3	16	7.13	3	Surgery
3	29	21.16	3	Chemotherapy
3	8.5	3.66	3	Surgery - Radiotherapy

predict the clinical outcome of Phyllodes tumors [8]. Surgery remains the mainstay of treatment of PT, and the role of adjuvant therapies is still controversial [9]. Wide surgical resection with tumor-free margins (of 1 cm or greater) offers high rates of local control and disease-free survival [10]. Total mastectomy (without axillary dissection) is reserved for extended lesions or multi recurrent tumors despite adequate margins [11-12]. Most authors recommend mastectomy for recurrence of borderline and malignant tumors and another wide excision for the recurrence of benign breast phyllodes tumors. As axillary metastases account for less than 0.5%, surgical axillary staging or axillary lymph nodes, dissection is not recommended unless there are pathologic nodes at clinical examination [13].

The potential role of adjuvant radiotherapy is a matter of debate. Evidence from retrospective series and the prospective study by Barth et al. shows that radiotherapy reduces the risk of local relapse in malignant tumors but do not impact distant failure rate or survival [14-19]. However, in the lack of the major prospective trials no definite conclusion can be drawn. In our series, radiotherapy was delivered in ten patients (28%) and only one of them relapsed. Adjuvant radiation therapy is discussed according to tumor size, surgical margins status, and mitotic index. When RT indicated is delivered at a dose of 50 Gy to the chest wall with a boost of 10 to 15Gy in the case of pathologic margins. The authors agree not to irradiate the axillary areas [9,10].

Adjuvant chemotherapy failed to improve the clinical outcome of PT, and its indication is even more questionable [20]. Therefore, none of our patients received adjuvant chemotherapy. In metastatic PT, authors [4] reported that the use doxorubicin and ifosfamide have resulted in some benefit in patients with visceral metastases. However, few large studies are supporting efficacious chemotherapy regimens. 40% of breast phyllodes tumors express progesterone receptors but do not express estrogen receptors [21]. Hormonal dependence of breast phyllodes tumors remains controversial, and it has not observed any response to hormonal treatments [22]. Thus none of our patients has benefited from hormonal therapy.

In the current study prognosis of PT is excellent. The 5 and

ten years OS are 97% and 95% respectively, (97% and 96% in the large series of Belkacemi et al.). Local control is more problematic as PT are known for their unpredictable risk of recurrence. It is believed that the potential for local recurrence is tightly related to histology. Several attempts to correlate tumor recurrence with pathologic criteria have resulted in mixed outcomes and none of the pathological factors have been proven to be risk factors for recurrence or survival.

Of the different factors studied, much focus has been placed on tumor size, grade, and surgical margins status. Reinfuss and al reported that local recurrence rates in their series was 4.3%, 15.8% and 11.9% in patients with benign, borderline and malignant PT respectively [13] and concluded that grade was the only prognostic factor related to recurrence. Contrastingly, Bennett and al. found no significant differences in the recurrence rates according to grade but reported that malignant tumors tended to recur earlier [23]. On the other hand, pathologic margins and large tumors were the ones likely to recur locally. In our series grade size and status of surgical margins impact local control.

In addition to these factors, studies have reported mitotic index, cellular atypia [24], cellular pleomorphism [25], tumor necrosis, pseudoangiomatous stromal hyperplasia or stromal overgrowth [26,27] to be prognostic factors for local failure. Recent immunohistochemical features have been reported, such as p53 expression and the MIB-1 index, may be useful for predicting the outcome of phyllode tumors [28] Surgery well manages local recurrences in benign and borderline tumors (breast-conserving surgery or mastectomy) [29]. Also, during recurrence of low-grade tumors, the largest series reported an incidence of sarcomatous progression of (3%) (2.27% in our series) and a distant failure rate <0.5 % (no event in our series) [24,30,31]. Based on these facts, involved surgical margins in low-grade tumors may not predict a bad outcome, and one could safely indicate no adjuvant treatment or immediate further surgery.

Contrastingly, local relapse in malignant tumors is associated with higher incidence of distant failure (6.4% in the literature 4.54% in our series) chest involvement (three of our patients), and Phyllodes related death (2 deaths in our series) [32]. All our patients with distant metastases had a local failure. Metastases

are mostly reported in malignant and borderline tumors. When PT recur at distant sites, it is usually within the first five years. The majority of the authors agreed that high mitotic index, stromal overgrowth, and tumor size at presentation may indicate an increased risk of developing metastases [5, 11, 30].

Conclusion

In summary, this is a substantial single institution experience of a rare tumor. Our data confirmed the good prognosis of PT. Wide excision surgery provides good local control. Grade, histological size, and margin involvement impacted disease free survival. For borderline and malignant tumors, RT should be discussed according to pathologic characteristics as local recurrence in high-grade tumors is difficult to manage and has a bad outcome.

Disclosure Statement

There were no financial support or relationships between the authors and any organization or professional bodies that could pose any conflict of interests.

Competing Interests

Written informed consent obtained from the patient for publication of this case report and any accompanying images.

References

1. World Health Organization. Histological typing of breast tumors. *Tumori* 1981; (67):253–272.
2. Geisler DP, Boyle MJ, Malnar KF, et al. Phyllodes tumors of the breast: A review of 32 cases. *Am Surg* 2000; (66): 360–366.
3. Guerrero MA, Ballard BR, Grau AM. Malignant phyllodes tumor of the breast: Review of the literature and case report of stromal overgrowth. *Surg Oncol* 2003;(12): 27–37.
4. Hawkins RE, Schofield JB, Fisher C, et al. The clinical and histological criteria that predicts metastasis from cystosarcoma phyllodes. *Cancer* 1992; (69): 141–7.
5. Fou A, Schnabel FR, Hamele-Bena D, Wei XJ, Cheng B, El Tamer M, Klein L, Joseph KA. Long-term outcomes of malignant phyllodes tumors patients: an institutional experience. *The American Journal of Surgery* 2006; 192 (4): 492–495.
6. Moore MP, Kinne DW. Breast sarcoma. *Surg Clin NorthAm* 1996; (76): 383–92.
7. Haberer S, Laé M, Seegers V, Pierga JY, Salmon R, Kirova YM, Dendale R, Campana F, Reyat F, Miranda O, Fourquet A, Bollet MA. Management of malignant phyllodes tumors of the breast: The experience of the Institut Curie. *Cancer Radiothérapie* 2009; 13(4):305-12.
8. P.R.K. Bhargav, Anjali Mishra, G. Agarwal, A. Agarwal, A.K. Verma and Saroj Kanta Mishra. Phyllodes Tumour of the Breast: Clinicopathological Analysis of Recurrent vs. Non-recurrent Cases. *Asian J Surg.* 2009; 32(4):224-8.
9. Belkacémi Y, Bousquet G, Marsiglia H, Ray-Coquard I, Magné N, Malard Y, et al. Phyllodes tumor of the breast. *Int J Radiat Oncol Biol Phys* 2008; (70):492–500.
10. Macdonald OK, Lee CM, Tward JD, et al. Malignant phyllodes tumor of the female breast: association of primary therapy with cause-specific survival from the Surveillance, Epidemiology, and End Results (SEER) program. *Cancer* 2006;107(9):2127–33.
11. Chaney AW, Pollack A, Mc Neese MD, Zagars GK, Pisters PW, Pollock RE, et al. Primary treatment of cystosarcoma phyllodes of the breast. *Cancer* 2000; (89):1502–11.
12. De Roos WK, Kaye P, Dent DM. Factors leading to local recurrence or death after surgical resection of phyllodes tumours of the breast. *Br J Surg* 1999; (86):396–9.
13. Reinfuss M, Mitu's J, Duda K, Stelmach A, Ry's J, Smolak K. The treatment and prognosis of patients with phyllodes tumor of the breast: an analysis of 170 cases. *Cancer* 1996; (77):910–6.
14. Barth Jr RJ, Wells WA, Mitchell SE, Cole BF. A prospective, multiinstitutional study of adjuvant radiotherapy after resection of malignant phyllodes tumors. *Annals of Surgical Oncology* 2009; 16(8):2288–9415.
15. Soumarova R, Seneklova Z, Horova H, et al. Retrospective analysis of 25 women with malignant cystosarcoma phyllodes-treatment results. *Archives of Gynecology and Obstetrics* 2004; 269(4):278–81.
16. Christensen L, Schiødt T, Blichert-Toft M, et al. Sarcomas of the breast: a clinico-pathological study of 67 patients with long term follow-up. *European Journal of Surgical Oncology* 1988; 14(3):241–7.
17. Chaeny AW, Pollack A, McNeese MD, et al. Primary treatment of cystosarcoma phyllodes of the breast. *Cancer* 2000; 89(7):1502–11.
18. Cohn-Cedermark G, Rutqvist LE, Rosendahl I, et al. Prognostic factors in cystosarcoma phyllodes. A clinicopathologic study of 77 patients. *Cancer* 1991; 68(9):2017–22.
19. Pandey M, Mathew A, Kattoor J, et al. Malignant phyllodes tumor. *The Breast Journal* 2001; 7(6):411–6.
20. Morales-Vasquez F, Gonzalez-Angulo AM, Broglio K, et al. Adjuvant chemotherapy with doxorubicin and dacarbazine has no effect in recurrence-free survival of malignant phyllodes tumors of the breast. *The Breast Journal* 2007; 13(6):551–6.
21. Rao CR, Narasimhamurthy NK, Jaganathan K, Mukherjee G, Hazarika D. Cystosarcomaphyllodes. Diagnosis by fine needle aspiration cytology. *Acto Cytol* 1992; (32):203–7.
22. Kanouni L, Jalil A, Saâdi I, Sifat H, Hadadi K, Errihani H, et al. Management of phyllodes tumors of the breast at the National institute of oncology of Rabat Morocco. *Gynecol Obstet Fertil* 2004; (32):293–301.
23. Bennett IC, Khan A, De Freitas R, et al. Phyllodes tumours: a clinicopathological review of 30 cases. *Aust N Z J Surg* 1992; (62):628–33.
24. BenHassouna J, Damak T, Gamoudi A, et al. Phyllodes tumors of the breast: A case series of 106 patients. *Am J Surg* 2006; (192): 141–147.

25. Roa JC, Tapia O, Carrasco P, et al. Prognostic factors of phyllodes tumor of the breast. *Pathol Int* 2006; (56):309–314.
26. Eroglu E, Irkkan C, Ozsoy M, et al. Phyllodes tumor of the breast: Case series of 40 patients. *J Gynaecol Oncol* 2004;25: 123–125.
27. Asoglu O, Ugurlu MM, Blanchard K,etal. Risk factors for recurrence and death after primary surgical treatment of malignant phyllodes tumors. *Ann Surg Oncol* 2004; (11):1011–1017.
28. Yonemori K, Hasegawa T, Shimizu C, et al. Correlation of p53 and MIB-1 expression with both the systemic recurrence and survival in cases of phyllodes tumors of the breast. *Pathol Res Pract* 2006; (202):705–712.
29. Zurrida S, Bartoli C, Galimberti V, et al. Which therapy for unexpected phyllode tumor of the breast? *European Journal of Cancer* 1992; 28(2/3):654–7.
30. Chen WH, Cheng SP, Tzen CY, et al. Surgical treatment of phyllodes tumors of the breast: retrospective review of 172 cases. *Journal of Surgical Oncology* 2005; 91(3):185–94.
31. Barrio AV, Clark BD, Goldberg JL, et al. Clinicopathologic features and long-term outcomes of 293 phyllodes tumors of the breast. *Annals of Surgical Oncology* 2007; 14(10):2961–70.
32. Gianluca Spitaleri Breast phyllodes tumor: A review of literature and a single center retrospective series analysis. *Critical Reviews in Oncology/Hematology* 2013; (88) 427–436.