



GESDAV

Journal of Experimental and Integrative Medicine

available at www.scopemed.org

Original Article

Effect of methanolic extract of *Physalis minima* on gastric inflammation and gastric ulcers formation

Umi Kalsum¹, Mulyohadi Ali¹, M. Aris Widodo¹, Handono Kalim²¹Department of Pharmacology, Faculty of Medicine;²Department of Internal Medicine, Saiful Anwar General Hospital, Faculty of Medicine;
University of Brawijaya, Malang, East Java, Indonesia

Received May 12, 2013

Accepted July 22, 2013

Published Online September 20, 2013

DOI 5455/jeim.220713.or.083

Corresponding AuthorUmi Kalsum
Department of Pharmacology,
Faculty of Medicine,
University of Brawijaya,
Malang, East Java, Indonesia.
dr.umikalsum@gmail.com**Key Words**Aspirin; Gastric ulcer; Indomethacin;
Inflammation; Steroids**Abstract****Objective:** This study aimed to investigate the effect of methanolic extract of *Physalis minima* L (MEPM) in gastric inflammation and gastric ulcer formation.**Methods:** For anti-inflammatory activity, we divided 30 male rats into five groups (n = 6), including the control group, gastric inflammation group, and gastric inflammation + MEPM groups (600, 1200 and 1800 mg/kg BW). Gastric inflammation was performed by oral administration of indomethacin at dose 30 mg/kg BW six hour prior to administration of MEPM. Phospholipase A2 was analysed by Western blotting. For gastric ulcer study, we compared the formation of ulcers between nonsteroidal anti-inflammatory drugs (aspirin) and MEPM. We divided 42 rats into seven groups (n = 6), including the control, aspirin (250, 500 and 750 mg/kg BW) and MEPM (600, 1200 and 1800 mg/kg BW) groups. Twenty four hours later the rats' gastric and duodenal tissues were removed and ulcers formation were analysed histologically.**Results:** MEMP inhibit phospholipase A2 at the dose of 1200 mg/kg. The gradation of gastric ulcers was higher in aspirin compared to MEMP. At the dose of 600 mg/kg, MEMP does not induce gastric ulcers, but aspirin induces ulcers just at 250 mg/kg.**Conclusion:** Methanolic extract of *Physalis minima* L exerts anti-inflammatory action due to its effect to inhibit phospholipase A2 expression. In addition, the gastric ulcers formation side effect of MEMP was lower compared to aspirin.

© 2013 GESDAV

INTRODUCTION

Inflammation is a pathophysiologic process mediated by various signaling molecules produced mainly by leukocytes, macrophages and plasma cells [1]. Steroids are known to be the best medicine used in treating acute inflammation, but have side effects when used for long periods of time, such as lowering the resistance of infection. Non-steroidal anti-inflammatory drugs (NSAIDs) are also used to treat inflammation, but they bring about side effects such as gastrointestinal bleeding [2].

Over-activation of the inflammatory mediators may contribute to gastric and intestinal mucosal damage [3]. Inflammation of the gastrointestinal (GI) tract can affect the functioning of the mucosal barrier, thereby influencing its protective activity. Drug-induced

damage to the GI tract has become a global problem due to widespread as well as the indiscriminate use of NSAIDs. Therefore, effective management of GI ulceration would primarily depend on the reduction of the aggressive factors, improved generation of protective factors or a combination of both. Advances in natural product chemistry have led to the purification and characterization of a number of chemical compounds with potent anti-ulcer activity [4].

Physalis minima L (Indonesian name as ciplukan) is wild vegetation found in the garden or wetland. This herb is commonly known as the bladder cherry and belongs to the Solanaceae family [5]. *P. minima* is an annual herb found throughout India, Baluchistan and Afghanistan, Tropical Africa and Australia, and is reported as one of the important medicinal plants in an

Indian traditional system of medicine. The plant majorly contains phenols, alkaloids, steroids and flavonoids [6]. Steroids of *P.minima* are physalin, resin, alkaloids, saponin and sterol. It contains also fatty acid. Several steroid compounds were found in the leaves of this plant, such as 13,14-seco-16,24-cyclosteroid consisted of physalin B, 5, 6 β -epoxyphysalin B, withaphysalin A, withaphysalin B, physalin D and physalin L [7].

Phospholipase A2 (PLA2) catalyzes hydrolysis of the sn-2 fatty acyl ester bond of phosphoglycerides, releasing free fatty acids and lysophospholipids. One of the fatty acids that can be released from membrane stores by the activity of PLA2 is arachidonic acid, the critical precursor for biosynthesis of diverse eicosanoids, including prostaglandins, thromboxanes, and leukotrienes. At least 15 human genes encode different PLA2 isoenzymes, including both secreted and cytosolic forms [8]. PLA2 is now generally considered playing a major role in various inflammatory diseases including *Helicobacter pylori*-associated gastritis or duodenitis [9]. Damage to the gastrointestinal surface protection system and the breakdown of complex membrane lipids activate PLA2, a key enzyme in the production of inflammatory lipid mediator. High concentrations of PLA2 have been reported in gastric mucosa [10].

None of the previous studies mentioned above revealed the potential effects of *Physalis minima* L as an gastric anti-inflammatory agent or its ulcer formation potential. Therefore, this study will attempt to analyze the potential effects of *P.minima* to reduce PLA2 activity as a marker of gastric inflammation. Besides, this study also compared the potential side effect (ulcer formation) of *P.minima* with aspirin as a standard NSAID. The hypothesis of this study is that the methanolic extract of *Physalis minima* L (MEPM) can reduce inflammation in the gastric mucosa and have minimal side effects compared to NSAIDs.

MATERIALS AND METHODS

Extraction

Methanolic extract was obtained in three steps, including drying, extraction, and evaporation. The drying process was done by cutting clean leaves and stem of *Physalis minima* L into small pieces, and then heated at 60-70°C. The drying samples were then blended and filtered using a mesh at size 60. A hundred grams of powder were added to 900 ml methanol in a 1 l Erlenmeyer jar. To obtain maximal evaporation, the mixture was incubated overnight. Then the upper layer was collected and connected to an evaporation apparatus. After separation, gas chromatography analysis was conducted to the MEPM.

Gas chromatography

Gas chromatography was performed using Rtx[®]-5MS columns (Restek Corporation, Bellefonte, PA, USA); length: 30 m x 0.25 mm; gas: helium; rate of column: 37.8 ml/min; injector temperature: 320°C; column temperature: 150°C; interface temperature: 320°C.

Animals

Seventy-two female Wistar rats, weighing 130-160 g, purchased from Central Animal House of Bandung were housed in an air-conditioned room at 24 \pm 2°C and 65-70% relative humidity with a 12 h light-dark cycle. The protocol used in this study was approved by the Ethic Committee for Animal Experimentation of the University of Brawijaya. Diets were prepared following American Institute of Nutrition (AIN) recommendations. The animals were given water *ad libitum* during the experimental period. The composition of diet is 66% comfeed PAR-s, 33% wheat powder and water.

Gastric inflammation

Gastric inflammation was performed according to Whiteley and Dalrymple [11]. We divided 30 rats into five groups (n = 6 each), including the control group, gastric inflammation group, and gastric inflammation + MEPM groups at doses of 600, 1200, and 1800 mg/kg body weight. Gastric inflammation was induced by indomethacin (30 mg/kg BW per oral) six hours prior to administration of MEPM.

Gastric ulcers

To examine the formation of gastric ulcers, we compared MEPM with aspirin, the standard non-steroidal anti-inflammatory drug. For this reason, 42 rats were divided into seven groups (n = 6 each), including the control, aspirin (250, 500 and 750 mg/kg BW) and MEPM (600, 1200 and 1800 mg/kg BW) groups. Twenty-hours after drugs administration the rats were killed by ether inhalation.

Phospholipase A2 analysis

The gastric tissue was digested and centrifuged at 6,000 rpm for 15 min at 4°C. The supernatant was then collected and added cold ethanol absolute at a ratio of 1:1. The samples were kept at 4°C overnight, then again centrifuged at 10,000 rpm for 15 min at 4°C. Pellet was dried until no smell of ethanol remained, then added to 20 mM Tris buffer and was ready for Western blotting procedure. SDS-PAGE electrophoresis was performed to separate protein with different molecular mass. Subsequently, this protein was transferred from gel polyacrilamide into nitrocellulose membranes. Labeling was performed by rabbit polyclonal PLA2 (ab58375; Abcam, Cambridge, UK). The binding between antigenic protein and antibody was then stained by Commasie blue.

Ulcer formation and histological analysis

The stomach was opened along the greater curvature, the lumen was rinsed with ice-cold saline, and the mucosa was examined macroscopically. The gastric and duodenal tissues were evaluated by gross examination and scored as follows (Lanza score): **0**, no evidence of ulceration; **1**, hyperemia and redness in mucosa; **2**, one until two ulcerations or hemorrhaging ulcers; **3**, 3-10 ulcerations or hemorrhaging ulcers; **4**, > 10 ulcerations or hemorrhaging ulcers. Erosions are defined as flat, white-based mucosal breaks of any size. Ulcers are defined as mucosal breaks of at least 3 mm or more [12]. Subsequently, the gastric and duodenal tissues were formalin-fixed, and paraffin-embedded tissue blocks were prepared for histopathological examination. The sections of these blocks were stained by hematoxylin and eosin (H&E) [13].

Statistical analysis

Lanza scores are presented as mean \pm SD and differences between groups were analyzed using one-way analysis of variance (ANOVA) with SPSS 17.0 software. Post hoc test was used if the ANOVA was significant; $P < 0.05$ was considered statistically significant.

RESULTS

Steroid compounds in *Physalis minima*

We identified several steroid compounds in *Physalis minima* including fucosterol (6.52%), campesterol (4.29%), stigmasterol (2.48%) and γ -sitosterol (1.8%).

Effect of MEPM on gastric inflammation

The level of PLA2 was analyzed by Western blotting as seen in Fig.1. MEPM inhibited PLA2 expression at the dose of 1200 mg/kg BW. There is no inhibition of PLA2 expression at doses of 600 and 1800 mg/kg BW.

Effect of MEPM on gastric ulcers formation

Histology of gastric tissue is given in Fig.2. Epithelial disruption identified as marker of ulcer formation was apparent. Table 1 shows the Lanza scores of study groups. The grade of gastric ulcers was significantly higher in aspirin-received groups than those of control animals ($P < 0.05$). At the dose of 600 mg/kg BW, MEPM did not induce gastric ulcers, but aspirin induced ulcers at just 250 mg/kg BW.

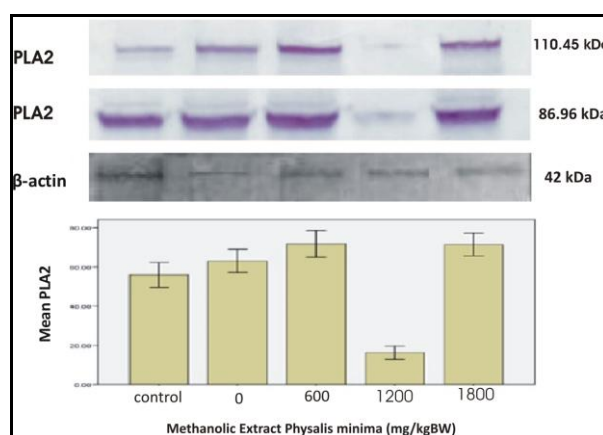


Figure 1. The level of phospholipase A2 was analyzed by Western blotting. MEPM inhibit the expression of phospholipase A2 at 1200 mg/kg BW. Interestingly, at lowest (600 mg/kg BW) or highest dose (1800 mg/kg BW), MEPM could not inhibit the expression of phospholipase A2.

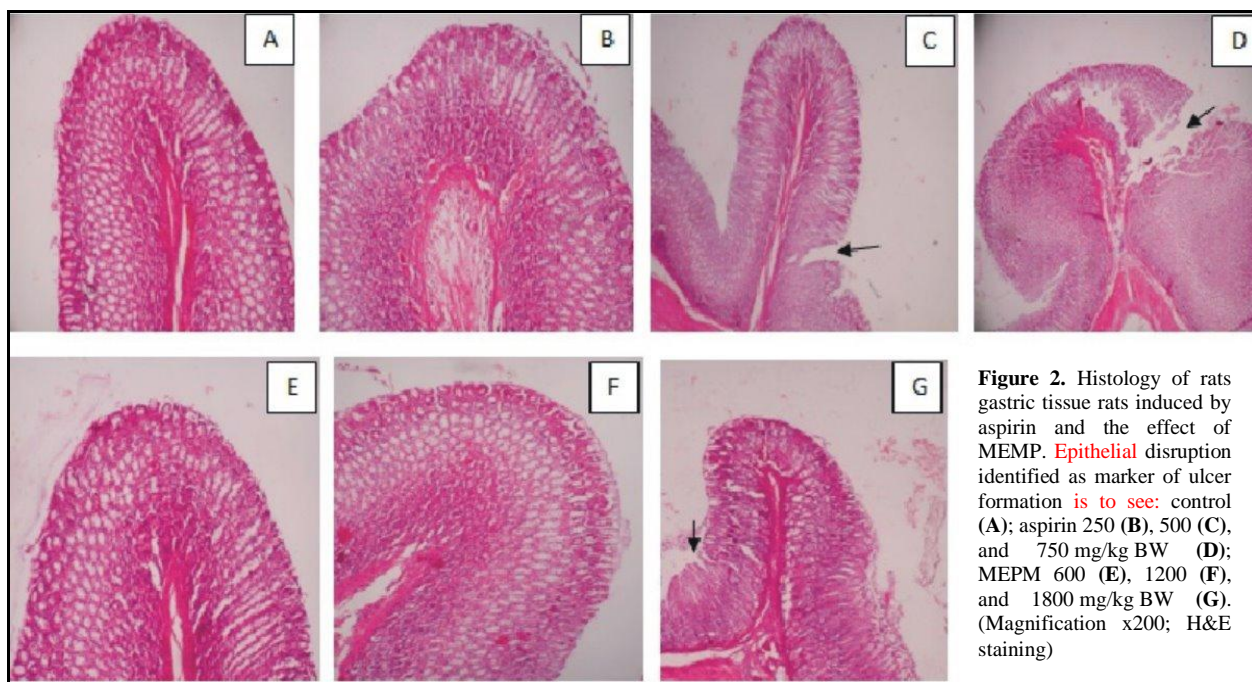

Figure 2. Histology of rats gastric tissue rats induced by aspirin and the effect of MEPM. Epithelial disruption identified as marker of ulcer formation is to see: control (A); aspirin 250 (B), 500 (C), and 750 mg/kg BW (D); MEPM 600 (E), 1200 (F), and 1800 mg/kg BW (G). (Magnification x200; H&E staining)

Table 1. Lanza scores of different groups

	Control	Aspirin (mg/kg BW)			MEPM (mg/kg BW)		
		250	500	750	600	1200	1800
Lanza score	0	1.6 ± 0.54 ^a	5 ± 0.7 ^{ab}	10.2 ± 0.83 ^{abc}	0 ^{bcd}	1.4 ± 0.54 ^{acde}	3.2 ± 0.83 ^{abcdef}

Values are presented as means ± SD; P < 0.05 in comparison with ^acontrol, ^baspirin 250, ^caspirin 500, ^daspirin 750, ^eMEPM 600, and ^fMEPM 1200 groups.

DISCUSSION

The gastric mucosa is continuously exposed to noxious substances and has specific defense mechanisms for maintaining its structural integrity. The epithelial surface secretes a barrier consisting of water, mucin bicarbonate and prostaglandins [14]. Phospholipids also play an important role in the preservation of gastrointestinal homeostasis. The enzyme PLA2 is capable of hydrolyzing membrane phospholipids, which in the presence of high gastric acidity lead to mucosal damage. PLA2 mediated hydrolysis of membrane lipids results in membrane perturbation, cell degranulation and stripping of cell surface receptors resulting in gastric ulcer. High concentrations of PLA2 have been reported in the gastric mucosa and PLA2 inhibitors are known to modulate proton conductance across cell membranes and thus can offer gastric mucus protection from enzymatic breakdown [15]. The expression of cytosolic PLA2 in cells of the intestinal tract has been thoroughly investigated and has also been correlated with the development of several inflammatory diseases [16].

In the present rat model of gastric inflammation, MEMP inhibits the expression of PLA2 at a dose of 1200 mg/kg BW. This finding might be due to active steroid compounds acting as anti-inflammatory agents. Based on chromatographic and spectroscopic analyses, previous studies showed that the extract of *Physalis minima* contains physalins B, F and K [6]. In the present study, steroid compounds analyzed by was chromatography on MEPM were found to be fucosterol, campesterol, stigmasterol, and γ -sitosterol. Fucosterol attenuates inflammatory cytokine expression by deactivating mitogen-activated protein kinases [17] and inhibiting the nuclear factor kappa-B (NF- κ B) [18]. Stigmasterol inhibits inflammation mediators via the blockade of NF- κ B distribution into the nucleus. Besides, campesterol also presented anti-inflammatory effects in a murine model of inflammation [19, 20]. Interestingly, at lowest or highest dose, MEMP could not inhibit the expression of PLA2; this may be due to the pro-inflammatory action of active compounds in MEPM as to see in Fig.1.

The gastric mucosa is one of the most important tissues in an organism, because of its function, structure, and the pathological processes that can take place in this tissue [21]. Gastric ulceration is related to more than

one factor, including *Helicobacter pylori* infection, stress, mucosal mucus secretion, gastric irritants and gastric acidity [22]. To compare side effects between aspirin and MEMP, we analyzed gastric ulcers formation in rats. MEMP did not induce gastric ulcers at 600 mg/kg BW, but aspirin induced ulcers at just 250 mg/kg BW. Aspirin induces gastric ulcer formation through the blockade of the cyclooxygenase pathway; thus, shifting the arachidonic acid metabolism to the 5-lipoxygenase pathway, which in turn led to enhanced production of leukotrienes, consequently leading to glandular disruption, decline in mucus production, excessive ulceration, and subsequent hemorrhagic ulcers [4, 7, 23]. Totally, the grade of gastric ulcers was significantly higher in aspirin-received groups compared to MEMP-administered groups.

In conclusion, methanolic extract of *Physalis minima* L possesses anti-inflammatory action due to an inhibitory effect on phospholipase A2 expression in gastric tissue. In addition, the gastric ulcer formation side effect of *Physalis minima* was lower compared to aspirin as an important member of NSAIDs.

ACKNOWLEDGEMENTS

The authors gratefully thank to Mrs. Husnul Khotimah, S. Si, M. Kes and all technicians in the Laboratory of Pharmacology (Mrs. Ferida & Mr. Moch Abuhari), Faculty of Medicine, University of Brawijaya, Malang for their valuable technical assistance.

COMPETING INTERESTS

The authors declare no conflicts of interest.

REFERENCES

- Jabit M, Wahyuni FS, Khalid R, Israf DA, Shaari K, Lajis NH, Stanslas J. Cytotoxic and nitric oxide inhibitory activities of methanolic extract of garcinia species. *Pharm Biol* 2009; 47:1019-26.
- Udani JK, Singh BB, Barret ML, Singh VJ. Evaluation of mangosteen juice blend on biomarkers of inflammation in obese subjects: a pilot, dose finding study. *Nutr J* 2009; 8:48.
- Zhang JX, Dang SC, Qu JG, Wang ZQ, Chen GZ. Changes of gastric and intestinal blood flow, serum phospholipase A₂ and interleukin-1 β in rats with acute necrotizing pancreatitis. *World J Gastroenterol* 2005; 11:3578-81.
- Mani Senthil Kumar KT, Puia Z, Samanta SK, Barik R, Dutta A, Gorain B, Roy DK, Adhikari D, Karmakar S, Sen T. Gastroprotective role of *Acanthus ilicifolius* - a study to unravel the underlying mechanism of anti-ulcer activity. *Sci Pharm* 2012; 80:701-17.
- Patel T, Shah K, Jiwan K, Shrivastava N. Study on the antibacterial potential of *Physalis minima* Linn. *Indian J Pharm Sci* 2011; 73:111-5.
- Leong OK, Muhammad TST, Sulaiman SF. Cytotoxic activities of *Physalis minima* L. Chloroform extract on human lung adenocarcinoma NCI-H23 cell lines by induction of apoptosis. *Evid Based Complement Alternat Med* 2011; 2011:185064.
- Sen G, Pathak HD. Physalin L, a 13,14-seco-16,24 cyclosteroid from *Physalis minima*. *Phytochemistry* 1995; 39:1245-6.
- Leung SY, Chen X, Chu KM, Yuen ST, Mathy J, Ji J, Chan AS, Li R, Law S, Troyanskaya OG, Tu IP, Wong J, So S, Botstein D, Brown PO. Phospholipase A₂ group IIA expression in gastric adenocarcinoma is associated with prolonged survival and less frequent metastasis. *Proc Natl Acad Sci USA* 2002; 99:16203-8.
- Choi KS, Kim EH, Hong H, Ock CY, Lee JS, Kim JH, Hahm KB. Attenuation of cysteamine-induced duodenal ulcer with *Cochinchina momordica* seed extract through inhibiting cytoplasmic phospholipase A₂/5-lipoxygenase and γ -glutamylcysteine activating synthetase. *J Gastroenterol Hepatol* 2012; 3:13-22.
- Tariq M, Elfaki M, Khan HA, Arshaduddin M, Sobki S, Moutaery MA. Bromophenacyl bromide, a phospholipase A₂ inhibitor attenuates chemically induced gastroduodenal ulcers in rats. *World J Gastroenterol* 2006; 12:5798-804.
- Whiteley PE, Dalrymple SA. Models of inflammation: measuring gastrointestinal ulceration in the rat. *Curr Protoc Pharmacol* 2001; 10:10.2.
- Soylu A, Dolapcioglu C, Dolay K, Ciltas A, Yasar N, Kalayci M, Alis H, Sever N. Endoscopic and histopathological evaluation of acute gastric injury in high-dose acetaminophen and nonsteroidal anti-inflammatory drug ingestion with suicidal intent. *World J Gastroenterol* 2008; 14:6704-10.
- Yelken B, Dorman T, Erkasap S, Dundar E, Tanriverdi B. Clonidine pretreatment inhibit stress-induced gastric ulcer in rats. *Anesth Analg* 1999; 89:159-62.
- deFonessa A, Kaunitz JD. Gastroduodenal mucosal defense. *Curr Opin Gastroenterol* 2010; 26:604-10.
- Nartey ET, Ofosuhune M, Kudzi W, Agbale CM. Antioxidant and gastric cytoprotective prostaglandins properties of *Cassia sieberiana* roots bark extract as anti-ulcerogenic agent. *BMC Complement Altern Med* 2012; 12:65.
- Nardone G, Holicky EL, Uhl JR, Sabatino L, Staibano S, Rocco A, Colatuoni V, Manzo BA, Romano M, Budillon G, Cockerill FR, Miller LJ. *In vivo* and *in vitro* studied of cytosolic phospholipase A₂ expression in helicobacter pylori infection. *Infect Immun* 2001; 69:5857-63.
- Kim MS, Oh GH, Kim MJ, Hwang JK. Fucosterol inhibits matrix metalloproteinase expression and promotes type-I procollagen production in UVB induced HaCaT cells. *Photochem Photobiol* 2013; 89:911-8.
- Yoo MS, Shin JS, Choi HE, Cho YW, Bang MH, Baek NI, Lee KT. Fucosterol isolated from *Undaria pinnatifida* inhibits lipopolysaccharide-induced production of nitric oxide and pro-inflammatory cytokines via the inactivation of nuclear factor- κ B and p38 mitogen-activated protein kinase in RAW264.7 macrophages. *Food Chem* 2012; 135:967-75.
- Gabay O, Sanchez C, Salvat C, Chevy F, Breton M, Nourissat G, Wolf C, Jacques C, Berenbaum F. Stigmasterol: a phytosterol with potential anti-osteoarthritic properties. *Osteoarthritis Cartilage* 2010; 18:106-16.
- Navarro A, De las Heras B, Villar A. Anti-inflammatory and immunomodulating properties of a sterol fraction from *Sideritis foetens* Clem. *Biol Pharm Bull* 2001; 24:470-3.
- Kim JH, Park SH, Nam SW, Choi YH. Gastroprotective effect of selenium on ethanol-induced gastric damage in rats. *Int J Mol Sci* 2012; 13:5740-50.
- Orhan YT, Karagozlu C, Sarioglu S, Yilmaz O, Murat N, Gidener S. A study on the protective activity of kefir against gastric ulcer. *Turk J Gastroenterol* 2012; 23:333-8.
- Rozza AL, Hiruma-Lima CA, Tanimoto A, Pellizzon CH. Morphologic and pharmacological investigations in the epicathecine gastroprotective effect. *Evid Based Complement Alternat Med* 2011; 2012:708156.

This is an open access article licensed under the terms of the Creative Commons Attribution Non-Commercial License which permits unrestricted, non-commercial use, distribution and reproduction in any medium, provided that the work is properly cited.