

ABNORMAL ORIGIN OF RIGHT SUBCLAVIAN ARTERY – A CADAVERIC STUDY

Hiren Chavda¹, Padma Varlekar¹, Chirag Khatri¹, SS Saiyad¹, Raksha Bhatt²

¹ Department of Anatomy, GMERS Medical College, Gandhinagar, Gujarat, India

² Department of Anatomy, Pramukh Swami Medical College, Karamsad, Gujarat, India

Correspondence to: Hiren Chavda (hiren_chavda2003@yahoo.com)

DOI: 10.5455/ijmsph.2013.220920131

Received Date: 08.09.2013

Accepted Date: 16.01.2014

ABSTRACT

Background: During early embryonic life, the aortic arch undergoes complex development and normally results in the formation of a left aortic arch from which three arteries arise: (1) the brachiocephalic artery, which divides into the right common carotid and right subclavian arteries, (2) the left common carotid artery and (3) the left subclavian artery. In the present study we found an aberrant right subclavian artery arising from the arch of aorta distal to the left common carotid artery.

Aims & Objective: Abnormalities of branches of arch of aorta are not uncommon and they have been identified more frequently with increasing use of imaging studies. However, the clinician should be aware of the wide range of anomalies that occur in the arch & the great vessels. This could help in adequately managing these variations in emergency approaches to the arch & the great vessels when imaging studies are not available. Our aim is to report the occurrence of the abnormal origin of right subclavian artery in a sample of western Indian population.

Material and Methods: Present study was conducted on embalmed cadavers in Anatomy Department at various medical colleges in Gujarat. Branches of arch of aorta were dissected & observed for any variation.

Results: A total of 70 cadavers were dissected. In one cadaver we found abnormal origin of right subclavian artery from the arch of aorta. The anomalous artery was passing behind the oesophagus. (1.43%, n = 70)

Conclusion: An aberrant right subclavian artery is a rare vascular anomaly & it is also an unusual cause of problems with the passage of solid food through the oesophagus. Recently it has been suggested that it occurs more frequently in patients with Down syndrome. Knowledge of this anomaly is important while evaluating feeding difficulties in patients with Down syndrome as well as in preventing vascular complications in patients with aberrant right subclavian artery.

Key-Words: Subclavian Artery; Aberrant; Cadaveric Study

Introduction

In approximately 80% of individuals, three branches arise from the aortic arch: the brachiocephalic trunk, the left common carotid artery and the left subclavian artery.^[1] Adachi first described this branching pattern as type A.^[2] Another 11% of reported cases exhibit Adachi's pattern type B, which consists of a common trunk for the left common carotid artery and the subclavian artery. This branching pattern results in only two trunks originating from the aortic arch. The third most common pattern, type C, is characterised by the vertebral artery, originating proximally to the left subclavian artery as a fourth branch of the aortic arch. The remaining 1% of cases are composed of numerous other aortic arch branching pattern variations.^[3] Thomson identified nine different variations in the mode of origin of the branches arising from the aortic arch in 500 specimens.^[4] He was able to identify a retrooesophageal right subclavian artery (RRSA) in five of the specimens (1%) and classified it as type D.

Normally right subclavian artery arises from brachiocephalic trunk and passes towards the arm. The

aberrant vessel arises from the aortic arch or proximal descending aorta distal to the left subclavian artery. Further course of ARSA (Aberrant right subclavian artery) can be variable. In 80% of the patients, it passes between the oesophagus and the spinal column. In 15% of patients, it runs between the oesophagus and the trachea and in 5%, it passes anterior to both trachea and oesophagus.^[5]

An aberrant right subclavian artery is a rare vascular anomaly that is believed to induce feeding and swallowing difficulties in 20% of the patients, caused by dorsal compression of the esophagus by the anomalous artery.

Recently it has been suggested that the prenatal occurrence of this vascular anomaly is substantially increased in Down syndrome where it can be found in up to 19–36% of cases.^[6] It may also be seen in patients with tetralogy of Fallot, pulmonary atresia, and major aorticopulmonary collateral arteries.^[7] Feeding problems in infants and young children with Down Syndrome are frequent and may lead to failure to thrive. The feeding problems may be caused by underlying conditions frequently associated with Down syndrome. These include congenital heart defects (present in 40–60% of Down

syndrome patients), gastrointestinal disorders such as duodenal web, gastro-esophageal reflux, endocrine disorders, or impaired oral motor function. In the absence of underlying disease conditions, feeding difficulties in Down syndrome may be due to the general hypotonia and related impaired oral motor function.

Failure to recognize such variations may lead to damage to this artery during esophageal surgery or vascular surgery with disastrous complications. Because of the rarity of the anomaly, pre-operative diagnosis may not be always possible. Further, dysphagia, if present, may well be because of the esophageal pathology and therefore may not help in diagnosis.

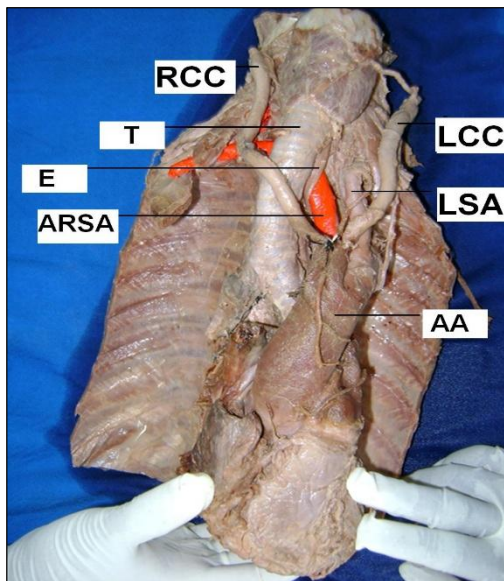


Figure-1: ARSA-aberrant right subclavian artery, LSA-left subclavian artery, RCC-right common carotid artery, LCC-left common carotid artery, AA-aortic arch, T-trachea, E-esophagus

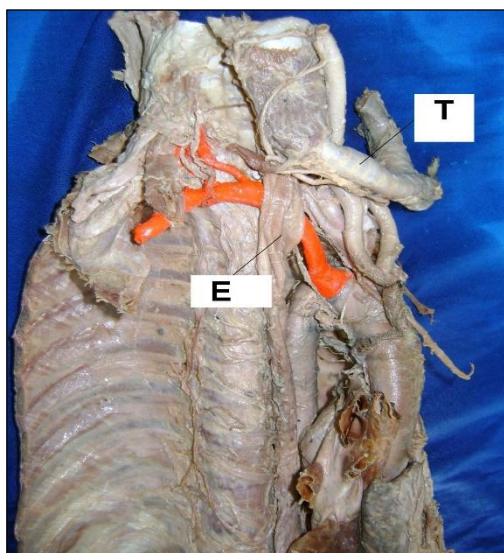


Figure-2: Right subclavian artery (red coloured) arising from the arch of aorta distal to the left subclavian artery. Trachea (T) is reflected to show the retroesophageal (E) course of the aberrant artery.

Materials and Methods

The present study was conducted on 70 embalmed cadavers over the period of four years. The cadavers were utilized for dissection for MBBS students at various medical colleges in Gujarat, West region of India. The aortic arch & its branches were exposed to observe any variation in the origin of right subclavian artery.

Results

Out of 70 cadavers, in one cadaver we found four branches arising from the aortic arch, from right to left, (1) Right common carotid artery (2) Left common carotid artery (3) Left subclavian artery and (4) Aberrant Right subclavian artery. The anomalous artery passed obliquely toward the right side behind oesophagus.

Discussion

The most common embryologic abnormality of the aortic arch is an aberrant right subclavian artery, which occurs in 0.5% to 1.8% of the population.^[8] The aberrant right subclavian artery arises from arch of aorta distal to the left subclavian artery and most frequently passes behind the oesophagus to the right arm. Rarely, it passes between the oesophagus and the trachea or in front of trachea.^[9-11] Therefore, the anomalous artery in the present study took the most common course.

In 1899 Holzapfel classified anomalous cases of the right subclavian artery into 10 types, and the present case belongs to Type 5.^[11] According to the Adachi-Williams-Nakagawa classification, the present case belongs to Type G.^[2,12,13] The incidence of the Adachi Type G variation in Japanese adults has been reported to be from 0.15 to 1.6%^[14,15] with an average of about 0.5%^[16,17]. Hara et al. studied the radiographic findings in 25 cases with pre-diagnosed aberrant artery on CT scans. On lateral radiographs, a posterior tracheal imprint was seen in 95% of the patients.^[18] Fockens et al. found an aberrant subclavian artery in 6/1,629 patients.^[19] However this study was directed towards picking up this particular vascular abnormality only and hence was very sensitive.

Normally, this anomaly causes no symptoms unless there is compression on the trachea or the esophagus. When present in isolation it may cause dysphagia (dysphagia lusoria). David Bayford (1761) was the first to note the association of dysphagia with oesophageal compression caused by an aberrant right subclavian artery.^[20] Dysphagia lusoria is the descriptive term for dysphagia

resulting from esophageal compression caused by an aberrant right subclavian artery (arteria lusoria).^[21] The dilated proximal ARSA is also known as diverticulum of Kommerell. In some patients this diverticulum may become aneurysmal. Almost all cases of distal arterial embolisation from an anomalous right subclavian artery have been associated with a right subclavian artery aneurysm. This anomaly is complicated by aortitis, dysphagia, chronic cough and intermittent dyspnoea. Dysphagia caused by this anomaly in older patients may be due to increased rigidity of the oesophagus itself or vessel wall and elongation of the aorta. Infant patients with arteria lusoria have symptoms of stridor or recurrent respiratory infections due to compression of trachea.^[22] In adults the trachea is more rigid, therefore, respiratory symptoms are rare. When symptoms occur in adults, oesophageal complaints (dysphagia) predominate. In addition, the risk of iatrogenic injury to the subclavian artery could increase. Therefore, an aberrant subclavian artery can sometimes be a challenging problem for surgical correction.

The incidence of ARSA in Down Syndrome has been reported in up to 16–39% of cases by Chaoui et al.^[6] Recognition of this association is of importance when evaluating feeding or swallowing difficulties in Down Syndrome patients. Most studies evaluating radiologic investigations have been performed on proven cases of an aberrant right subclavian artery or with an intention of finding this anomaly & therefore may not actually translate into picking this rare anomaly preoperatively. Previous reports document a 30% to 45% incidence of limb ischaemia in patients undergoing ligation (without reconstruction) of an aberrant right subclavian artery.^[23,24] Hence prompt reconstruction of the artery is necessary to prevent critical limb ischaemia.

Embryological Explanation

Normally right subclavian artery develops from right 4th aortic arch, a part of the right dorsal aorta caudal to the ductus caroticus & right 7th intersegmental artery. Sometimes the right subclavian artery arises from the junction of the definitive arch of aorta & descending aorta & courses upwards & to the right behind the trachea & oesophagus. This anomaly is caused by the degeneration of the right 4th aortic arch. So that the right 7th intersegmental artery & the right dorsal aorta caudal to it are continued as the aberrant right subclavian artery.

In this condition right recurrent laryngeal nerve reaches directly into the larynx and does not undergo a recurrent

course due to degeneration of the dorsal part of the right 6th aortic arch & entire right 4th aortic arch.^[25-27]

Conclusion

Most variations of the aortic arch and great vessels are not a reason for patient complaints. However clinicians performing imaging studies and catheter-based techniques for aortic arch and great vessels should be aware of this variation to decrease the risk of iatrogenic injury. Knowledge of this anomaly, pre-operative identification and careful dissection especially in a thoracoscopic mobilization, will help in preventing disastrous vascular complications in patients with an aberrant right subclavian artery.

References

1. Bergman RA, Thompson SA, Afifi AK, Saadeh FA. Compendium of Human Anatomic Variation: Catalog, Atlas and World Literature. Baltimore, Md, USA: Urban & Schwarzenberg; 1988. pp. 61–70.
2. Adachi B. Das Arterien system der Japaner. Vol. 1. Kyoto: Verlag der Kaiserlich-Japanischen Universitat, Kenyusha Press; 1928. pp. 29–41.
3. McDonald JJ, Anson BJ. Variations in the origin of arteries derived from the aortic arch, in American whites and negroes. *Am J Phys Anthropol*, 1940;27: 91–107.
4. Thomson A. Third Annual report of the committee of selective investigation of the Anatomical Society of Great Britain and Ireland for the year 1891–1892. *J Anat Physiol*. 1893;27: 183–194.
5. Quain R. Anatomy of the Arteries of the Human Body. London: Taylor and Walton; 1844. pp. 152–155.
6. Henle J. Handbuch der Systematischen Anatomie des Menschen 3 Abth. : Muskellehre. Braunschweig, F. Vieweg u. Sohn. 1871. pp. 247.
7. Janssen M, Breburda CS, Geuns RJ, Hermans WR, Klootwijk P, Bekkers JA, et al. Images in Cardiovascular Medicine. Aberrant right subclavian artery mimics aortic dissection. *Circulation*. 2000; 101:459–60.
8. Chaoui R, Heling K, Sarioglu N, Schwabe M, Dankof A, Bollmann R. Aberrant right subclavian artery as a new cardiac sign in second- and third-trimester fetuses with Down syndrome. *Am J Obstet Gynaecol*. 192:257–263
9. Rosa P, Gillespie DL, Goff JM, O'donnell SD, Starnes B. Aberrant right subclavian artery syndrome: a case of chronic cough. *J Vasc Surg* 2003; 37:1318
10. Carrizo GJ, Marjani MA: Dysphagia lusoria caused by an aberrant right subclavian artery. *Tex Heart Inst J* 2004; 31:168-71
11. Bayford D. An account of a singular case of obstructed deglutition. *Memoirs Med Soc London*. 1794;275–286.
12. Goldbloom AA. The anomalous right subclavian artery and its possible clinical significance. *Surg Gynecol Obstet*. 1922;34: 378–384.
13. Holzapfel Ungewöhnlicher Ursprung und Verlauf der Arteria subclavia dextra. *Anat Hefte*. 1899;12: 369–523.
14. Nakagawa M. On the branching pattern of the aortic arch. *J Juzen Med Soc*. 1939;44: 243–259 (in Japanese).
15. Williams GD, Affe HM, Scheckebier M, Edmonds HW, Gaul EG. Variations in the arrangement of the branches arising from the aortic arch in American whites and negroes. *Anat Rec*. 1932;54: 247–251.
16. Yoshitomi M, Kanemura E, Ohtomo G, Ishibashi K, Saiki H, Ariyoshi T. An anomalous case on four branches of the aortic arch. *J Kurume Med Ass*. 1977;40: 853–858 (in Japanese).
17. Horiguchi M, Yamada T, Uchiyama Y. A case of retroesophageal right subclavian artery — with special reference to the morphology of cardiac nerves. *Acta Anat Nippon*. 1982;57: 1–8 (in Japanese).
18. Takemura A, Matsumoto M, Mori T. A case of the right subclavian artery as the last branch of the aortic arch. *Okajima Fol Anat Jpn*.

- 1979;56: 317-328.
19. Yoshida Y, Fukuyama U. A case of an anomalous origin of the right subclavian artery and analysis of the right recurrent nerve fibers. Chiba Med J. 1975;51: 195-199 (in Japanese).
20. Hara M, Satake M, Itoh M, Ogino H, Shiraki N, Shibamoto Y. Radiographic findings of aberrant right subclavian artery initially depicted on CT. Radiat Med. 2003; 21: 161-5.
21. Fockens P, Kisman K, Tytgat GNJ. Endosonographic imaging of an aberrant right subclavian (lusorian) artery. Gastrointest Endosc. 1996; 43: 419.
22. Janssen M, Baggen MGA, Veen HF, et al. Dysphagia lusoria: clinical aspects, manometric findings, diagnosis and therapy. Am J Gastroenterol. 2000; 95: 1411-6.
23. Brown DL, Chapman WC, Edwards WH, Coltharp WH, Stoney WS. Dysphagia lusoria: aberrant right subclavian artery with a Kommerell's diverticulum. Am Surg. 1993; 59: 582-6.
24. Work WP. Unusual position of the right recurrent laryngeal nerve. Ann Otol Rhinol Laryngol. 1941; 50: 769-75.
25. Lee R, Maughan RE, Svensson LG. Elephant trunk reconstruction for aberrant right subclavian and aortic aneurysm. Ann Thorac Surg. 1997; 64: 547-8.
26. Esposito RA, Khalil I, Galloway AC, Spencer FC. Surgical treatment for aneurysm of aberrant subclavian artery based on a case report and a review of the literature. J Thorac Cardiovasc Surg. 1988; 95: 888-91.
27. Datta AK. Essentials of human embryology. 5th ed. Calcutta: Indian Press; 2005. pp. 188-190.

Cite this article as: Chavda HS, Varlekar PD, Khatri CR, Saiyad SS, Bhatt R. Abnormal origin of right subclavian artery – A cadaveric study. Int J Med Sci Public Health 2014;3:85-88.
Source of Support: Nil
Conflict of interest: None declared