

Posterior condylar foramen—anatomical variation

Usha Kothandaraman, Sadhu Lokanadham

Department of Anatomy, ESIC Medical College, Chennai, Tamil Nadu, India.

Correspondence to: Sadhu Lokanadham, E-mail: loka.anatomy@yahoo.com

Received October 9, 2014. Accepted October 25, 2014

Abstract

Background: The condylar canal opens at the base of the skull just behind the occipital condyles. The patency of the channel depends upon the condylar emissary vein that runs along its path.

Objective: To study the anatomical variation in posterior condylar foramen.

Materials and Methods: A total of 50 dry adult human skulls were used from the Department of Anatomy, ESIC Medical College, Chennai, to study the posterior condylar canal and its variations.

Results: The incidence of posterior condylar foramina was 26%, bilateral 16%, and unilateral 10%. Intrasinus form of posterior condylar foramina was in 20% and retrosinus form in 6% of the 50 skulls observed in our study.

Conclusion: Anatomical variations of posterior condylar foramina are important during the treatment of dural arteriovenous fistula. Our study gives basic knowledge to the clinicians and surgeons before planning a surgery in the occipital condylar regions.

KEY WORDS: Posterior condylar canal, bilateral, unilateral, variation

Introduction

Anterior part of the occipital condyle presents a canal called as hypoglossal canal or anterior condylar canal, whereas posterior to the occipital condyle, there is a depression known as posterior condylar fossa.^[1] The superior articular facet of the atlas is accommodated within this fossa during the movements of the atlantooccipital joint. Occasionally, within this fossa, a foramen may be present, which is called as the condylar canal or the posterior condylar canal.^[2] Posterior condylar canal is the largest emissary foramen of the posterior cranial fossa. It is apparent just posteroinferior to the jugular foramen and posterior to the hypoglossal canal. Condylar canal transmits an emissary vein to the sigmoid sinus and nerves, which supply the dura mater of the posterior cranial fossa. This emissary vein is called as the posterior condylar vein that connects the veins present in the suboccipital triangle with that of the sigmoid sinus.^[1,3] Posterior condylar canal also transmits meningeal branches of the occipital artery. The lateral transcondylar surgical approach for skull base surgery involves extensive dissection and may cause injury to the neurovascular structures.^[4,5]

Materials and Methods

We collected 50 dry adult skulls from the Department of Anatomy, ESIC Medical College and PGIMSR, Chennai, to study the unilateral or bilateral presence or absence of the posterior condylar canal. The occipital condyles were examined carefully for the condylar foramina and considered complete foramina as variation for the present study. We observed by passing a probe into the bilateral and unilateral posterior condylar foramina to find where they were opening into the posterior cranial fossae in their entire course.

Results

Of the 50 human dry skulls, we observed posterior condylar foramina in 13 skulls (bilaterally 8, unilaterally 5), with an incidence of 26%. The presence of bilateral posterior condylar foramina in 8 skulls (16%) and unilateral foramina in 5 (left 3, right 2) skulls (10%) of the 50 skulls was noted (Table 1). The intrasinus form of posterior condylar foramina was observed in 10 (20%) skulls and retrosinus form in 3 (6%) skulls (Table 2).

Table 1: Presence of posterior condylar foramina in human dry skulls

Type	Bilateral (16%)	Unilateral (10%)	
		Right	Left
Posterior condylar foramina	8	2	3

Access this article online

Website: <http://www.ijmsph.com>

DOI: 10.5455/ijmsph.2015.0910201445

Quick Response Code:



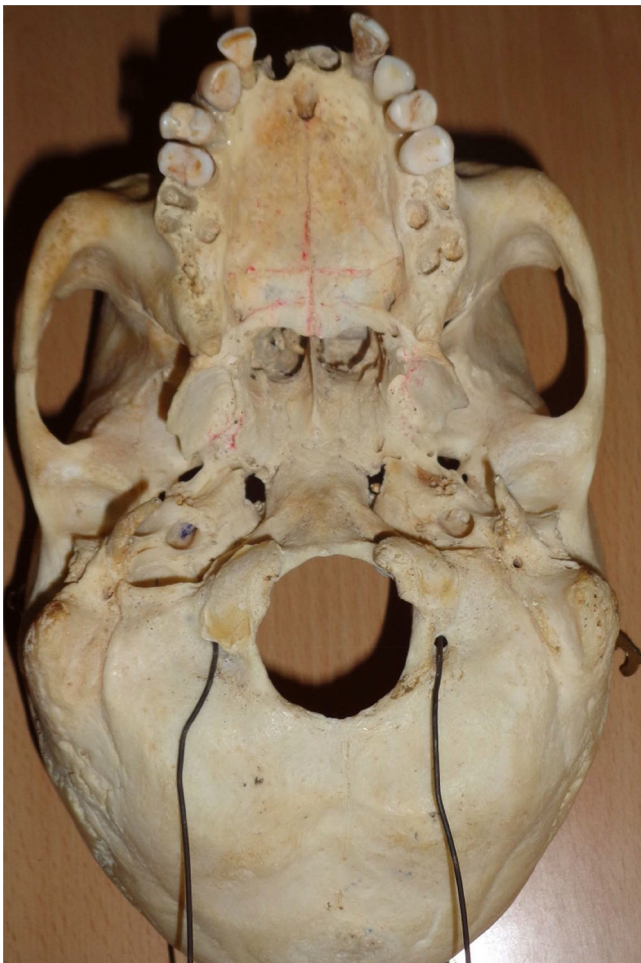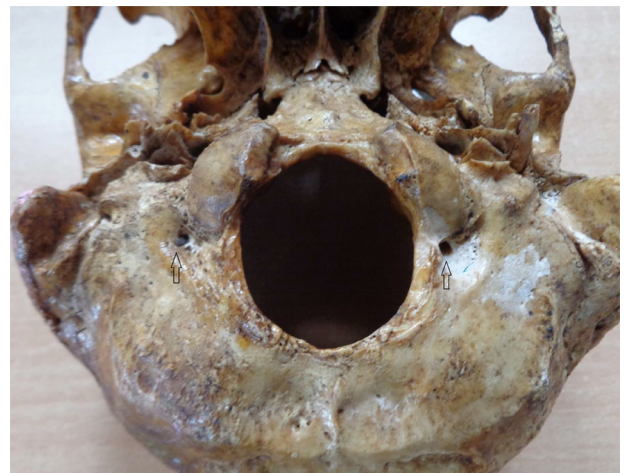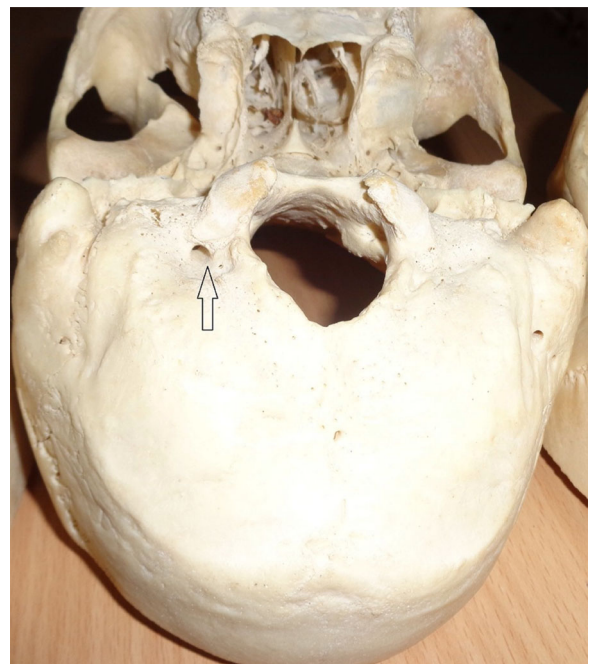
Table 2: Incidence of posterior condylar foramina in relation with sigmoid sinus

Type	Intrasinus (20%)		Retrosinus (6%)	
	Right	Left	Right	Left
Posterior condylar foramina	8	2	2	1

Discussion

The posterior condylar canal opens at the groove for sigmoid sinus, posterolateral to the jugular foramen in the posterior cranial fossa. These anomalous foramina also open at the same location in the posterior cranial fossa.^[6] This leads to the speculation that these anomalous foramina might be acting as additional source of drainage of the intracranial veins into extracranial veins. Ginsberg observed the posterior condylar canal to be bilateral in 55.9% and unilateral in 17.6%.^[7] Boyd found the posterior condylar canal with an

incidence of 77% unilaterally.^[8] Galarza et al. found intrasinus form in 24.6% bilaterally, 17.8% on the right side and 13.5% on the left side, whereas retrosinus form of the posterior condylar foramina in 1.2% bilaterally and 1.2% unilaterally on the right side.^[9] Krause discovered that condylar canal was present bilaterally in 21% and unilaterally in 38%.^[10] In our study, we observed posterior condylar foramina in 13 skulls of the 50 dry skulls. The incidence of posterior condylar foramina was 26%: bilateral incidence was 16%, whereas unilateral was 10% (Figures 1–3). Intrasinus form of posterior condylar foramina in 20% and retrosinus form in 6% were observed in

**Figure 1:** Bilateral posterior condylar foramina (probed).**Figure 2:** Bilateral posterior condylar foramina.**Figure 3:** Unilateral posterior condylar foramina.

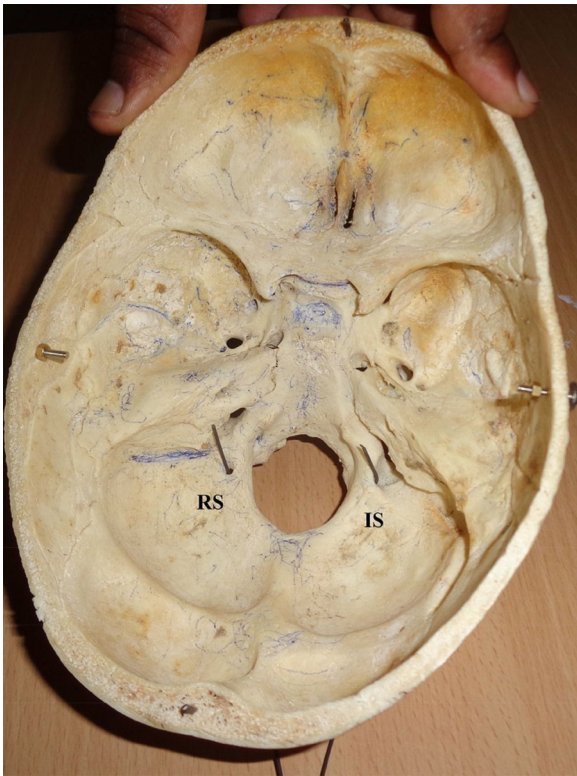


Figure 4: Posterior condylar foramina type in relation with sigmoid sinus: retrosinus form (RS), left; intrasinus (IS) form, right.

our study (Figure 4). The incidences of our study were in agreement with that of some literature. The number of skulls used for this study was less compared with the previous studies because of the less availability of dry skulls in our newly established ESIC Medical College.

Conclusion

The condylar veins can be used as access routes to hypoglossal dural arteriovenous fistulas.^[11] Anatomical variations of the posterior condylar foramina are important during the treatment of dural arteriovenous fistula. Our study gives basic knowledge to the clinicians and surgeons before planning a surgery in the occipital condylar regions.

Acknowledgments

The authors acknowledge the help received from Kirubakaramoorthy during this study. They are also grateful to authors, editors, and publishers of all those articles, journals, and books from where the literature for this article has been reviewed and discussed.

References

1. Williams PL, Warwick R, Dyson M, Bannister L. *Gray's Anatomy*, 37 edn. New York, NY: Churchill Livingstone, 1989. pp. 286–7.
2. Hacker H. Normal supratentorial veins and dural sinuses. In: Newton TH, Potts DG, eds. *Radiology of the Skull and Brain: the Skull*. St. Louis, MO: Mosby, 1971. Vol 2. pp. 1851–77.
3. Matsushima T, Natori Y, Katsuta T, Ikezaki K, Fukui M, Rhoton AL. Microsurgical anatomy for lateral approaches to the foramen magnum with special reference to transcondylar fossa approach. *Skull Base Surg*. 1998;8(3):119–25.
4. Kiyosue H, Okahara M, Sagara Y, Tanoue S, Ueda S, Mimata C, et al. Dural arteriovenous fistula involving the posterior condylar canal. *AJNR Am J Neuroradiol*. 2007;28(8):1599–601.
5. Avci E, Dagtekin A, Ozturk AH, Kara E, Ozturk NC, Uluc K, et al. Anatomical variations of the foramen magnum, occipital condyle and jugular tubercle. *Turk Neurosurg*. 2011;21(2):181–90.
6. Hollinshead WH, Rosse C. *Textbook of Anatomy*, 4th edn. New York, NY/Philadelphia, PA: Harper and Row, 1985. p 871.
7. Ginsberg LE. The posterior condylar canal. *AJNR Am J Neuroradiol*. 1994;15(5):969–72.
8. Boyd GI. The emissary foramina of the cranium in man and the anthropoids. *J Anat*. 1930;65(Pt 1): 108–21.
9. Galarza M, Yun jong H, Merlo A. Chilean. *J Anat*. 1998;16(1): 83–7.
10. Krause W. The posterior condylar canal. In: Testut L, Latarjet A, eds. *Treaty of Human Anatomy*. Barcelona, Spain: Salvat; 1988. Vol 1. pp. 152–8.
11. Kiyosue H, Hori Y, Okahara M. Dural arteriovenous fistula involving the hypoglossal canal: case reports and literature review. 8th World Federation of Interventional and Therapeutic Neuroradiology. *Interv Neuroradiol*. 2005;11(Suppl 2): 127.

How to cite this article: Kothandaraman U, Lokanadham S. Posterior condylar foramen—anatomical variation. *Int J Med Sci Public Health* 2015;4:222-224

Source of Support: Nil, **Conflict of Interest:** None declared.