

Outcome and predictors in simple decompression of ulnar nerve entrapment at the elbow

Ilka Anker¹, Malin Zimmerman¹, Gert S Andersson², Helene Jacobsson³, Lars B Dahlin⁴

ABSTRACT

Objectives: Simple decompression is an accepted surgical treatment of ulnar nerve entrapment at the elbow (UNE). Our purpose was to evaluate the outcome and potential predictors for the outcome after simple decompression in UNE.

Methods: All surgically treated UNE cases (from 2004-2008) at our department were studied retrospectively. Out of 285 primary surgeries, 242 primary simple ulnar nerve decompressions were included. Medical records, including electrophysiologic protocols, were reviewed and postoperative outcome was graded: 1) cured/improved and 2) unchanged/worsened symptoms, based on surgeon-evaluated outcome.

Results: Of the 242 simple decompressions (122 males and 120 females; median age 50.5 years), 101 cases were students, retired, un-employed, or on a long-term sick-leave and 112 had manual, blue-collar type of work. 189 cases were cured or improved, while 53 cases had no change in, or even worsened, symptoms. Gender, presence of smoking, or associated diseases did not affect outcome, while a tendency was observed for higher age, a manual occupation and constant symptoms. Out of 196 cases electrophysiologically examined, 155 cases showed signs of ulnar nerve affection (56 reduced conduction velocity; 19 conduction block; 80 axonal degeneration; latter two groups significantly worse outcome).

Conclusion: Patients with a preoperatively electrophysiologically diagnosed nerve conduction block or axonal degeneration have higher risk of not being cured or improved after simple decompression in UNE. Older patients, those with a manual profession, and constant symptoms of UNE tend to be less improved after surgery.

Key words: Decompression, electrophysiology, outcome, predictor, ulnar nerve

Introduction

Ulnar nerve entrapment at the elbow (UNE; incidence 20.9/100 000 inhabitants and year [1]); is the second most common compression neuropathy after carpal tunnel syndrome (CTS) [2]. The condition is

mainly considered to be idiopathic, but risk factors, such as heavy manual, stationary and repetitive work, vibration exposure, concomitant CTS and multiple occasions of minor pressure exerted on the cubital tunnel (e.g. leaning one's elbow on hard surfaces), may pre-

Author affiliations : ¹Department of Translational Medicine, Hand Surgery, Lund University, Malmö, Sweden ²Department of Neurophysiology, Lund University, Skåne University Hospital, Lund, Sweden ³R&D Centre Skåne, Skåne University Hospital, Lund, Sweden ⁴Department of Translational Medicine, Hand Surgery, Lund University, Malmö, Sweden and Department of Hand Surgery, Skåne University Hospital, Malmö, Sweden

Correspondence : Lars B Dahlin, MD, Department of Translational Medicine, Hand Surgery, Lund University, Malmö, Sweden and Department of Hand Surgery, Skåne University Hospital, Malmö, Sweden. e-mail: lars.dahlin@med.lu.se

Received / Accepted : May 10, 2017 / June 14, 2017

dispose to UNE [2-4]. Gender, high body mass index (BMI), smoking and diabetes, have not consistently been found to increase the risk or being associated with UNE [2,3,5,6].

Diagnosis is based on patient history, symptoms and clinical signs. Common provocative clinical tests are the Tinel's test (sensitivity 62-70%) [7,8] and the elbow flexion-pressure test (sensitivity 61-98%) [7,8]. Weakness of the ulnar-innervated muscles may be detected through testing. There is, however, no consensus on which clinical tests to perform for the best support in diagnosing UNE. Electrophysiologic examinations are useful in supporting the diagnosis (sensitivity 73-96%), identifying the location of the lesion and estimating the severity of entrapment [9,10].

UNE can be treated either conservatively or surgically. Since there is no standardized, evidence-based process for taking care of patients with suspect UNE, treatment decisions are strongly doctor dependent [11]. A recent Cochrane review concluded that we still do not know when conservative treatment is superior to surgical treatment and vice versa [11]. The few studies conducted on conservative treatment of UNE show that 35-89% of patients with mild or moderate UNE [12-14] are improved by conservative treatment alone. Surgical treatment is generally recommended when conservative treatment has failed, or in more severe cases of UNE. The outcome after simple decompression, i.e. a simple release of structures affecting the ulnar nerve (e.g. Osbourne's ligament and the arcade at the two heads of flexor carpi ulnaris muscle, over a limited distance) [15] is equal to that of both subcutaneous and submuscular transposition [16-18], but with a lower risk of postoperative complications [16,17]. The less invasive, and surgically easier, simple decompression is by some therefore considered as the gold standard when treating the majority of primary UNE cases surgically.

Our purpose was to evaluate outcome after simple ulnar nerve decompression at the elbow, aiming to identify factors that can predict functional outcome.

Patients and Methods

All cases of UNE that were surgically treated between 2004-2008 at our department were retrospectively studied. A total of 343 cases (i.e. 281 patients) were found (Figure 1). Out of the 285 primary surgeries, 242 (i.e. six cases not included due to no outcome registered in the patient folders) were simple ulnar nerve decompressions (Figure 1), and they were included in the study.

Medical records of all cases were thoroughly reviewed and gender, age, associated diseases, occupation, previous trauma to the elbow, subjective symptoms, clinical signs, diagnostic methods used, possible conservative treatment employed, educational level of the surgeon and postoperative outcome were obtained and entered in a database. Comorbidities were defined as systemic disease.

If the patient reported constant symptoms, they were classified as constant. Symptoms that were reported as recurrent, but not constant, were classified as intermittent. Clinical diagnosis was only based on patient history, symptoms and examination, including Tinel's test, muscle strength in ulnar nerve innervated muscles, ulnar nerve subluxation and present muscle atrophies in ulnar nerve innervated muscles. Electrophysiologic protocols were revised, assessed and graded by one of the authors (GS.A; specialist in neurophysiology and based on reference values at our department) into four groups: normal findings, reduced conduction velocity, nerve conduction block or axonal degeneration. The most pathological parameter was used to grade the nerve; i.e. if both reduced conduction velocity and axonal degeneration was present the nerve was graded as the latter.

The postoperative outcomes were graded by one of the authors (IA; specialist in orthopaedic surgery (not hand surgery) but not treating surgeon in any of the cases). Due to the retrospective nature of the study postoperative outcome based on validated, standardized questionnaires could not be re-

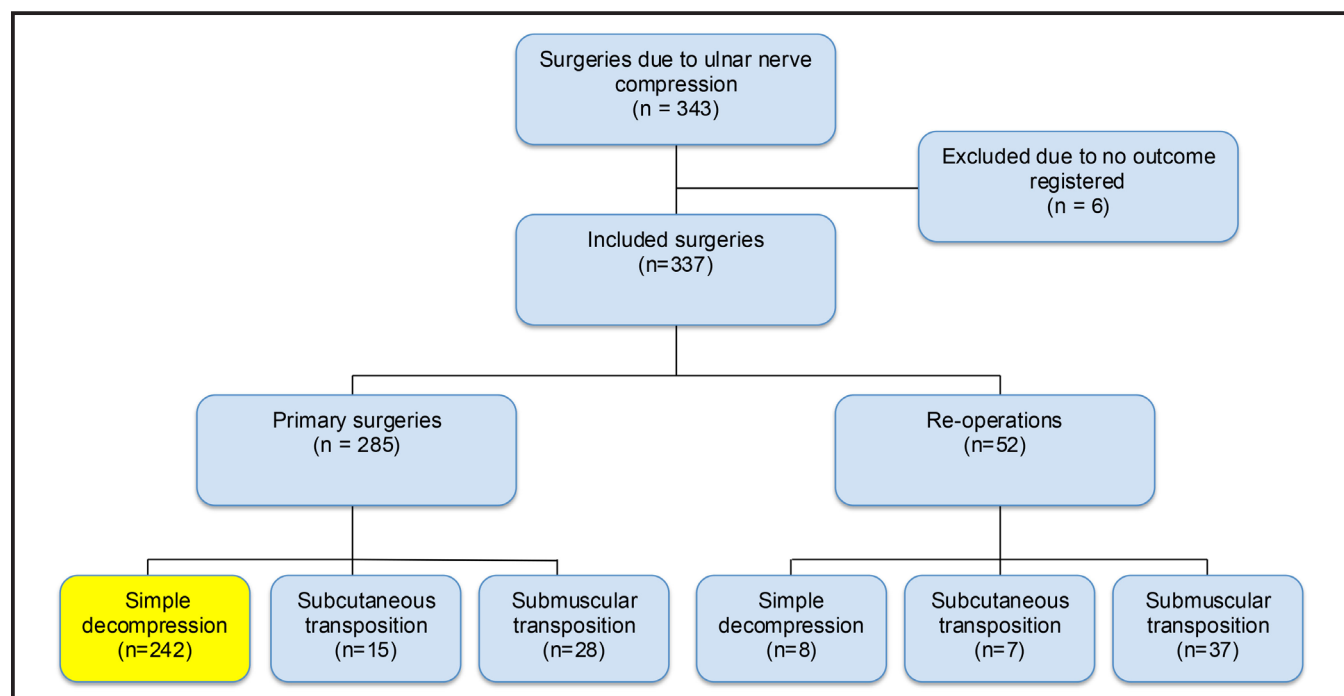


Figure 1. Flowchart of surgeries due to ulnar nerve compression at the elbow between 2004-2008. Included cases at bottom left.

produced. The outcomes were, therefore, based on patient-reported and surgeon-evaluated outcome registered in the patient files at the last out-patient visit and then divided into two groups for comparison and due to clinical reasons: cured/improved or unchanged/worsened [19]. During the study's time-frame, there were no standardized follow-up at our department, but it was done according to the decision of the treating surgeon.

Conservative treatment was defined as the use of an orthosis to keep the elbow semiflexed at around 30 degrees during the night. The general surgical indication at our department is constant numbness and paresthesia in the ulnar nerve innervated fingers with or without motor symptoms and if conservative treatment has failed. Simple decompression is the method of choice in ordinary cases, but if a clear luxation or hypermobility of the ulnar nerve is seen pre- or perioperatively a submuscular (or sometimes subcutaneous) nerve transposition is performed (these cases are not included in the present study). Simple decompression was performed through a 6-10 cm long curved incision,

slightly going ventral to the medial epicondyle avoiding exposure and scar directly over the nerve at sulcus level, along the course of the ulnar nerve. The ligament of Osbourne and the superficial and deep fascias of the flexor carpi ulnaris muscle were incised. The Struther's arcade or any aponeurosis were not released if the clinical findings did not indicate anything else. The ulnar nerve itself was then retained on its bed and not circumferentially dissected from the surrounding connective tissue. No data is presented concerning intraoperative findings of the ulnar nerve since such data were not consequently described in the patient folders and that such findings are difficult to judge. At the postoperative follow-up, we did not find any CRPS or neuroma requiring reoperation.

In some cases, the preoperative examination was supplemented with an x-ray of the elbow or MRI of the cervical spine if there was suspicion of another disorder or diagnosis. These cases were included as well.

Statistical analyses

All data are presented as cases (i.e. number of nerves) that underwent surgery. Data are presented

as median (minimum–maximum) values or numbers (%). Statistical differences were assessed with the Mann-Whitney U test or the Fisher's Exact test. A p-value of < 0.05 was considered significant. No statistical power analysis was performed due to the design of evaluating outcome, but the achieved number of patients evaluated for five years was considered sufficient. Statistical analyses were conducted with IBM SPSS Statistics 22 for Windows (IBM Corporation, New York, NY, USA).

Ethical considerations

The study protocol was presented to the regional Ethical Review Board (#2011/607). They found the study sound, without ethical problems, but judged that the study was not applicable to the law in geographical area deleted. They recommended that neither advertising nor formal informed consent by each patient was needed. Chief of service at our department approved the quality control. Therefore, no formal permission number has been attached to the study.

Results

Characteristics of the cases undergoing simple decompression

Characteristics of the included cases are presented in Table 1. A majority of the cases had manual, heavy, blue-collar type of work (Table 1). One hundred seventy-eight (74%) had developed UNE without preceding trauma to the ulnar nerve. One hundred seventy-two (71%) of the cases had comorbidity with other systemic conditions or concomitant CTS (Table 1). Most cases had numbness and paresthesia as their main symptom (Table 1). The time of symptom duration before the first medical consultation could not be derived from the patient folders in a satisfactory way and is therefore not presented.

Clinical signs of ulnar nerve entrapment

The treating surgeon examined all cases clinically and diagnosis was made according to the treating surgeon's preference (see below beneath electrophysiology). Indications for surgery were generally those

Table 1. Characteristics of 242 cases with simple ulnar nerve decompression at the elbow. Values are numbers (%) if not otherwise specified. Statistical differences are detected with Mann-Whitney U test or Fisher's Exact test.

	All cases (n=242)	Cured or improved (n=189)	Unchanged or worsened (n=53)	p-value
Age [median (min-max)]	50.5 (17-85)	49.0 (17-85)	53.0 (27-75)	0.09
Gender (M/F)	122 (50) / 120 (50)	92 (49) / 97 (51)	30 (57) / 23 (43)	0.35
Profession (manual/non-manual) ^a	112 (84) / 22 (16)	87 (81) / 20 (19)	25 (93) / 2 (7)	0.13
Smoking (yes/no) ^b	66 (68) / 31 (32)	53 (71) / 22 (29)	13 (59) / 9 (41)	0.31
Healthy (yes/no)	70 (29) / 172 (71)	56 (30) / 133 (70)	14 (26) / 39 (74)	0.73
Diabetes (yes/no)	25 (10) / 217 (90)	22 (12) / 167 (88)	3 (6) / 50 (94)	0.31
CTS (yes/no)	114 (47) / 128 (53)	91 (48) / 98 (52)	23 (43) / 30 (57)	0.64
CTS ipsilateral (yes/no) ^c	105 (43) / 137 (57)	83 (44) / 106 (56)	22 (42) / 31 (58)	0.88
Repetitive work load (yes/no)	153 (63) / 89 (37)	117 (62) / 72 (38)	36 (68) / 17 (32)	0.52
Symptom character (intermittent/constant)	133 (55) / 109 (45)	109 (58) / 80 (42)	24 (45) / 29 (55)	0.12
Numbness/paraesthesia (yes/no)	230 (95) / 12 (5)	179 (95) / 10 (5)	51 (96) / 2 (4)	1.00
Night splint pre-op (yes/no)	179 (74) / 63 (26)	138 (73) / 51 (27)	41 (77) / 12 (23)	0.60
Electrophysiology (yes/no)	196 (81) / 46 (19)	150 (79%) / 39 (21)	46 (87) / 7 (13)	0.32
Positive electrophysiology for UNE (yes/no) ^d	155 (79) / 41 (21)	118 (79) / 32 (21)	37 (80) / 9 (20)	1.00

^a 134 had a defined manual/non-manual profession; of them are 107 cured or improved and 27 are unchanged or worse.

^b 145 (n) are missing; 114 are missing in the group of cured or improved and 31 are missing in the group of unchanged or worse.

^c only cases that have ipsilateral or bilateral CTS.

^d In 196 cases electrophysiology was performed; of them are 150 cured or improved and 46 are unchanged or worse.

described above (see Patients and methods). Clinical signs are presented in detail in Table II. The elbow flexion-pressure test was not tested or described in a sufficient number of cases and this data is therefore not presented.

Electrophysiology

One hundred ninety-six (81%) of all cases underwent electrophysiologic examination [in 173 (72%) cases with the short-segment stimulation technique; i.e. “inching” technique]; hence in 46 (19%) cases the treating surgeon based the diagnosis purely on patient history and clinical examination. In 155 (79%) cases, the electrophysiologic examination showed signs of an ulnar nerve affection supporting the diagnosis UNE (Table III).

Conservative treatment and surgical procedure

In the majority of the cases (Table I), a conserva-

tive treatment, i.e. night split (generally for at least three months), was tried before surgery, with an unsatisfactory effect on symptoms. In this study, a specialist in hand surgery operated most of the cases [174 (72%)] and in the rest of the cases an experienced resident alone performed the surgery. Axillary plexus anesthesia was used most frequently [187 (78%)] and general anesthesia was used in the other cases [54 (22%)]. No ganglions were found during surgery (data not shown).

Outcome after simple decompression

After simple decompression, 189/242 (78%) of the cases reported an excellent or good outcome, where patients perceived a complete or partial recovery. In 53/242 (22%) of the cases, no change in, or even worsened (i.e. more pronounced symptoms compared to preoperatively), symptoms were reported postoperatively by the patients.

Table 2. Clinical signs of 242 cases with simple ulnar nerve decompression at the elbow. Values are numbers (%). Statistical differences are detected with Fisher's Exact test.

Clinical signs	All cases (n=221)	Cured or improved (n=170)	Unchanged or worsened (n=51)	p-value
Impaired sensibility				
Volar	26 (12)	21 (12)	5 (10)	0.37
Volar + dorsal	149 (67)	114 (67)	35 (68)	
Beyond ulnar	27 (12)	23 (14)	4 (8)	
No	19 (9)	12 (7)	7 (14)	
Tinel's sign	(n=213)	(n=165)	(n=48)	0.29
Positive	175 (82)	138 (84)	37 (77)	
Negative	38 (18)	27 (16)	11 (23)	
Weakened muscle strength^a	(n=216)	(n=166)	(n=50)	0.85
FDP 5	35 (16)	29 (18)	6 (12)	
ADM + IO	40 (19)	30 (18)	10 (20)	
FDP 5 + ADM + IO	86 (40)	65 (39)	21 (42)	
No	55 (25)	42 (25)	13 (26)	
Muscle atrophy	(n=142)	(n=104)	(n=38)	0.53
Yes	54 (38)	38 (36)	16 (42)	
No	88 (62)	66 (63)	22 (58)	
Subluxation tendency	(n=242)	(n=189)	(n=53)	0.10
Yes	15 (6)	9 (5)	6 (11)	
No	227 (94)	180 (95)	47 (89)	

^a FDP 5 = m. flexor digitorum profundus to 5th digit, ADM = m. abductor digiti minimi, IO = mm. interossei

Table 3. Documented results of electrophysiology tests among 242 cases with simple ulnar nerve decompression at the elbow. Values are numbers (%). Statistical differences are detected with Fisher's Exact test.

Electrophysiology	All cases (n=196)	Cured or improved (n=150)	Unchanged or worsened (n=46)	p-value
Normal	41 (21)	32 (21)	9 (20)	
Impaired conduction velocity	56 (29)	51 (34)	5 (11)	
Conduction block	19 (10)	11 (7)	8 (17)	
Axonal degeneration	80 (41)	56 (37)	24 (52)	0.004

No significant differences between the cases reporting cured/improved and unchanged/worsened were found in outcome regarding gender, presence of smoking or associated diseases. Higher age, cases with a manual occupation and cases with constant symptoms showed a tendency towards a worse outcome compared to younger age, cases with a non-manual profession or intermittent symptoms (Table I).

No significant differences in outcome were detected concerning subjective symptoms (Table I) and clinical signs, although cases with an ulnar nerve subluxation showed a tendency towards a worse outcome (Table II).

Cases, where UNE diagnosis was confirmed by electrophysiological findings, did not differ in outcome compared to cases where diagnosis solely was based on the patient's history and clinical findings (Table I). However, cases with electrophysiologically more severe pathology, i.e. nerve conduction block along the ulnar nerve or an axonal degeneration, showed a worse outcome (Table III). Cases, where conservative treatment with night-splint had been employed preoperatively, showed no significant difference in outcome compared to cases that had gone directly to surgery (Table I), but also among these 179 cases the ones with electrophysiologically detected nerve conduction block along the ulnar nerve or an axonal degeneration had a worse outcome (data not shown). Cases operated by a specialist in hand surgery were to a significantly higher degree cured or improved of their UNE ($p=0.009$; data not shown).

Discussion

In this study, our purpose was to analyze patients' outcome and to find potential predictors of func-

tional outcome after simple decompression of the ulnar nerve. A number of studies have been made through the years focusing on outcome after surgical intervention of UNE, where different types of surgical treatments have been compared [16-18], but few have focused on and evaluated potential predictors of surgical outcome.

We used a simple method to evaluate outcome in this study, dividing the patients in cured/improved and unchanged/worse outcome, after studying the surgeon-evaluated outcome registered in the patient files. This type of simple clinical outcome assessment by the treating surgeon has been shown to correlate well to improvement in the patient-rated outcome questionnaire QuickDASH at one year post-surgery [19]. The QuickDASH is suitable for evaluation of outcome in clinical studies [19,20].

A great majority of the present cases had done electrophysiologic examinations and tried conservative treatment with a night-splint before surgery. In our region, it is not standard that all patients undergo electrophysiological testing prior to surgery for UNE. In the present study, only 46 cases had not done electrophysiologic examination. Interestingly, we could not find a difference in outcome between these cases and the cases with electrophysiologically verified UNE diagnosis, which seemingly supports the notion that clinical symptoms should weigh heavily when diagnosing and treating UNE.

Cases with electrophysiologically more severe pathology, i.e. nerve conduction block or axonal degeneration, showed a worse outcome. Electrophysiologic examinations may, in accordance with previous studies

[9, 10], be useful in confirming UNE diagnosis and our results also show that electrophysiologic assessment of the degree of effect on the ulnar nerve is a good predictor on surgical outcome, which has been indicated in some previous studies as well [21,22]. This predictor can be of value when discussing patient expectations preoperatively. Patients with a preoperatively electrophysiologically confirmed more severe ulnar nerve pathology can be informed that they might not be cured of their UNE symptoms with simple decompression, or even other surgical procedure, hence lowering their surgical expectations to a more realistic level.

Cases with higher age, a heavy manual profession and constant symptoms, showed tendencies towards a worse outcome. Previous studies have indicated that heavy manual occupation with stationary and repetitive workload may predispose to UNE [2,3], but few report how specific risk factors influence outcome.

We detected no significant difference in outcome concerning subjective symptoms and clinical signs (apart from the presence of ulnar nerve subluxation). Hence, provocative tests are not only suboptimal in diagnosing UNE [8], but we conclude that clinical signs and the severity of them also are a poor predictor of surgical outcome. Ulnar nerve subluxation showed a tendency towards a worse outcome after surgical treatment with simple decompression. We found that some patients with ulnar nerve subluxation were treated with simple decompression despite the fact that transposition is the standard procedure at our department when pre- or perioperative subluxation exists. We can only speculate on the reasons for this, but it might be a definition issue or lack of preoperative agreement with the patient that a transposition will be performed if subluxation of the nerve is noted after simple decompression.

To summarize, the most predictable factor was electrophysiological analyses; where more severe ulnar nerve pathology was linked to worse outcome. From a clinical point of view this should be interpreted with

caution. We do not conclude that we should not treat UNE patients with more severe ulnar nerve pathology surgically. In contrast, these patients may even need surgical treatment more than patients with mild pathology, since surgical decompression of the ulnar nerve might be more efficient than conservative treatment in preventing further damage to the nerve in these patients. Further studies will be needed to analyze this relation closer.

Comments on analyses

The number of cases in the study was based on nerves rather than patients. This may cause an underestimation of the statistical uncertainty if a within-patient dependency was present. However, the bilaterally operated cases were only 28 out of 242 (11.6%); thus, the possible statistical dependence would just have a marginal effect on the results. Furthermore, removing the bilaterally operated patients would skew the results and to choose only one of the arms would induce a systematic error in data. Another possibility would be to involve a “mean value”, or judgment, from both arms, but that would level out any discrepancies between the two arms and is not possible with the present outcome method. However, it would be possible to use a “mean value” if e.g. scores from QuickDASH is used [20]. Thus, all simple decompression procedures were treated as independent cases.

Study limitations

The limitations of this study are mainly due to the retrospective nature of the analyses. Sufficient data was not available for all parameters in this “real world” study, as in most retrospective studies. Due to this factor, preoperative examinations as well as postoperative outcome have been assessed retrospectively and are not standardized. Validated questionnaires had not been used, therefore, the presently used outcome data are based on the patients’ subjective opinion of how successful the treatment was, but such judgment correlate well with validated questionnaires as QuickDASH [19,20].

Conclusions

We conclude that patients with a preoperatively and electrophysiologically diagnosed nerve conduction block or axonal degeneration have a significantly higher risk of not being cured or improved of their ulnar nerve entrapment after surgical treatment with simple decompression. Older patients, those who have a heavy manual profession, constant symptoms of UNE or a subluxating ulnar nerve may also tend to be less improved after simple decompression.

Conflict of interest statement

The authors have no conflicts of interest to declare.

References

- Mondelli M, Giannini F, Ballerini M, Ginanneschi F, Martorelli E. Incidence of ulnar neuropathy at the elbow in the province of Siena (Italy). *J Neurol Sci* 2005;234:5-10.
- Descatha A, Leclerc A, Chastang JF, Roquelaure Y. Study Group on Repetitive W. Incidence of ulnar nerve entrapment at the elbow in repetitive work. *Scand J Work Environ Health* 2004;30:234-40.
- Bartels RH, Verbeek AL. Risk factors for ulnar nerve compression at the elbow: a case control study. *Acta Neurochir (Wien)* 2007;149:669-74; discussion 74.
- Kakosy T. Tunnel syndromes of the upper extremities in workers using hand-operated vibrating tools. *Med Lav* 1994;85:474-80.
- Richardson JK, Green DF, Jamieson SC, Valentin FC. Gender, body mass and age as risk factors for ulnar mononeuropathy at the elbow. *Muscle Nerve* 2001;24:551-4.
- Stamboulis E, Vassilopoulos D, Kalfakis N. Symptomatic focal mononeuropathies in diabetic patients: increased or not? *J Neurol* 2005;252:448-52.
- Novak CB, Lee GW, Mackinnon SE, Lay L. Provocative testing for cubital tunnel syndrome. *J Hand Surg Am* 1994;19:817-20.
- Beekman R, Schreuder AH, Rozeman CA, Koe-
hler PJ, Uitdehaag BM. The diagnostic value of provocative clinical tests in ulnar neuropathy at the elbow is marginal. *J Neurol Neurosurg Psychiatry* 2009;80:1369-74.
- Visser LH, Beekman R, Franssen H. Short-segment nerve conduction studies in ulnar neuropathy at the elbow. *Muscle Nerve* 2005;31:331-8.
- Todnem K, Michler RP, Wader TE, Engstrom M, Sand T. The impact of extended electrodiagnostic studies in ulnar neuropathy at the elbow. *BMC Neurol* 2009;9:52.
- Caliandro P, La Torre G, Padua R, Giannini F, Padua L. Treatment for ulnar neuropathy at the elbow. *Cochrane Database Syst Rev* 2016;11:CD006839.
- Dellon AL, Hament W, Gittelshon A. Nonoperative management of cubital tunnel syndrome: an 8-year prospective study. *Neurology* 1993;43:1673-7.
- Svernlöv B, Larsson M, Rehn K, Adolfsson L. Conservative treatment of the cubital tunnel syndrome. *J Hand Surg Eur Vol* 2009;34:201-7.
- Shah CM, Calfee RP, Gelberman RH, Goldfarb CA. Outcomes of rigid night splinting and activity modification in the treatment of cubital tunnel syndrome. *J Hand Surg Am* 2013;38:1125-30e1.
- Cho YJ, Cho SM, Sheen SH, Choi JH, Huh DH, Song JH. Simple decompression of the ulnar nerve for cubital tunnel syndrome. *J Korean Neurosurg Soc* 2007;42:382-7.
- Biggs M, Curtis JA. Randomized, prospective study comparing ulnar neurolysis in situ with submuscular transposition. *Neurosurgery* 2006;58:296-304; discussion 296-304.
- Bartels RH, Verhagen WI, van der Wilt GJ, Meulstee J, van Rossum LG, Grotenhuis JA. Prospective randomized controlled study comparing simple decompression versus anterior subcutaneous transposition for idiopathic neuropathy of the ulnar nerve at the elbow: Part 1. *Neurosurgery* 2005;56:522-30; discussion 30.
- Gervasio O, Gambardella G, Zaccone C, Branca D.

- Simple decompression versus anterior submuscular transposition of the ulnar nerve in severe cubital tunnel syndrome: a prospective randomized study. *Neurosurgery* 2005;56:108-17; discussion 17.
19. Dahlin E, Dahlin E, Andersson GS, Thomsen NO, Bjorkman A, Dahlin LB. Outcome of simple decompression of the compressed ulnar nerve at the elbow - influence of smoking, gender, and electrophysiological findings. *J Plast Surg Hand Surg* 2017;51:149-55.
 20. Zimmerman M, Dahlin E, Thomsen NO, Andersson GS, Bjorkman A, Dahlin LB. Outcome after carpal tunnel release: impact of factors related to metabolic syndrome. *J Plast Surg Hand Surg* 2016:1-7.
 21. Beekman R, Wokke JH, Schoemaker MC, Lee ML, Visser LH. Ulnar neuropathy at the elbow: follow-up and prognostic factors determining outcome. *Neurology* 2004;63:1675-80.
 22. Shi Q, MacDermid J, Grewal R, King GJ, Faber K, Miller TA. Predictors of functional outcome change 18 months after anterior ulnar nerve transposition. *Arch Phys Med Rehabil* 2012;93:307-12.