

Benign soft tissue tumors of the hand: A retrospective review of 17-year experience

Fatih Irmak¹, Koray Basdelioglu², Selami Serhat Sirvan¹, Kamuran Zeynep Sevim¹, Aysin Karasoy Yesilada¹

ABSTRACT

Objective: Tumors of the hand are common and mostly benign. Benign soft tissue tumors of the hand can arise from the skin, tendons, vessels, nerve and subcutaneous tissue. Tumors can be removed by surgical excision for cosmetic reasons and a possibility of malignancy. The objective of this retrospective study was to evaluate the types of benign soft tissue tumors of the hand in comparison to the literature.

Materials and Methods: We conducted a retrospective review of all surgically excised benign soft tissue tumors of the hand at the University of Health Sciences Sisli Hamidiye Etfal Training and Research Hospital between March 2000 and October 2017. A total of 426 patients (208 males and 218 females) were included in this study. The mean age was 39.4 years (range, 4-61 years). 426 patients were evaluated according to their ages, genders, anatomic location and histopathology of tumors and their treatment modalities.

Results: The most common benign tumor of the hand was pyogenic granuloma (25%). The other diagnosed benign tumors of the hand with the decreasing percentage were ganglion cysts (15%), giant cell tumors of the tendon sheaths (GCTTS) (15%), other hand tumors (13%), hemangiomas (8%), neurinomas and schwannomas (6%), fibromas and fibroliopomas (5%), epidermal cysts (3%), glomus tumors (2%) and arteriovenous malformations (2%).

Conclusion: A comprehensive history and detailed physical examination performed by specialists are essential in the diagnosis of the tumor. The vast majority of hand tumors are benign, and if a tumor of the hand is suspected, a biopsy should be performed before definitive treatment.

Key words: Soft tissue tumors, benign tumor, the tumor of the hand

Introduction

Soft tissue tumors of the hand and wrist are mostly seen in hand surgery practice, and these are frequently benign masses [1]. 10-15 % of all soft tissue lesions in

the human body is localized in hand [2,3]. The most of the studies conducted on the diagnosis and treatments of these benign tumors of the hand were retrospective and in small series. Therefore, masses of the hand have

Author affiliations : ¹Department of Plastic and Reconstructive Surgery, ²Department of Hand Surgery, University of Health Sciences, Sisli Hamidiye Etfal Training and Research Hospital, Istanbul, Turkey

Correspondence : Koray Basdelioglu, MD, Department of Hand Surgery, University of Health Sciences, Sisli Hamidiye Etfal Training and Research Hospital, Istanbul, Turkey. e-mail: drkoraybasd@gmail.com

Received / Accepted: February 23, 2018 / May 07, 2018

been inadequately documented in the literature.

Benign soft tissue tumors of the hand can arise from the skin, tendons, vessels, nerve and subcutaneous tissue [4]. A detailed history, physical examination, baseline plain X-rays, if needed, ultrasound and advanced imaging, most commonly magnetic resonance imaging (MRI) plays an essential role in the diagnosis and management of benign tumors of the hand. Certain lesions with a specific characteristic of appearance can enable the clinician to make a diagnosis and develop an optimal plan of treatment without biopsy [5]. Soft tissue tumors of the hand typically present as masses which may or may not be differentiated by plain X-rays and neuropathy unless there is an effect on surrounding structures. However, if a lesion has a rapid growth or other atypical effects or both and causes pain, then malignancy must be considered [5].

Surgical treatment can be a treatment of choice for cosmetic reasons and possibility of malignancy [6,7]. This study addresses only the benign masses which affect soft tissue structures, and the objective was to evaluate benign soft tissue tumors of the hand.

Patients and Methods

We conducted a retrospective review of all surgically excised benign soft tissue tumors of the hand at the Sisli Hamidiye Etfal Training and Research Hospital in Istanbul, Turkey, over a 17-year period (2000 to 2017). A total of 426 patients (208 males and 218 females) were evaluated in this study.

The information obtained from medical records included patients' age, anatomical location of the tumor, gender, histopathology of the tumor and their treatment modality. Inclusion criteria were comprised of benign soft tissue tumors of the hand distal to the wrist crease. Only one exclusion criteria were the tumors which localized in hand proximal to the distal wrist crease. Demographic parameters of the patients were demonstrated in Table 1.

The identified benign tumors were glomus tumors, epidermal cysts, giant cell tumors of the tendon sheaths (GCTTS), pyogenic granulomas, neurinomas, schwan-

Table 1. Demographic parameters of the patients.

Mean Age	39.4
Female	32.5
Male	35.5
Age Range	4-61
Female	4-59
Male	8-61
Previous skin lesions	25.2 %

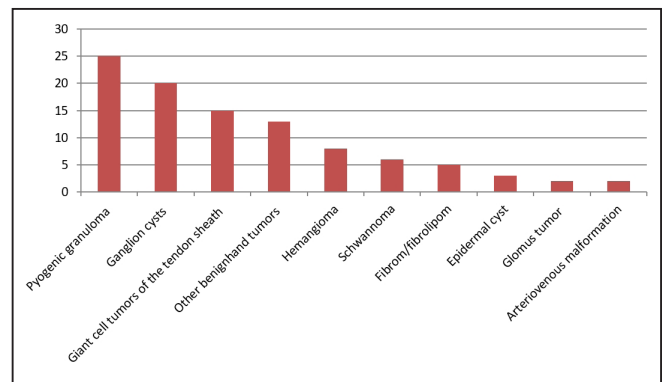


Figure 1. Distribution of benign hand tumors.

nomas, lipomas, cystic hygromas, hemangiomas, arteriovenous malformations, fibromas, fibrolipomas, ganglion cysts and the other benign tumors (infantile digital myofibroblastoma, dermatofibroma, verruca vulgaris etc.).

Results

Over the period of 17 years, 426 patients were evaluated for their age, gender, anatomic location of the tumor, histopathology of the tumor and their treatment modality. The incidence of benign soft tissue tumors of the hand was higher in female patients than male patients. 25% of the cohort had a previous history of soft tissue and skin lesion.

Pyogenic granuloma was the most common benign tumor (25%) of the hand. The remaining benign tumors were ganglion cysts (15%), giant cell tumors of the tendon sheaths (GCTTS) (15%), other hand tumors (13%), hemangiomas (8%), neurinomas and schwannomas (6%), fibromas and fibrolipomas (5%), epidermal cysts (3%), glomus tumors (2%) and arteriovenous malformations (2%) (Figure 1).

Table 2. Benign soft tissue tumors of the hand.

	Number of benign tumors	Most Frequent Location	Female-Male	Female: Male Ratio	Age (Range)
AVM	7	D2	4-3	1.33:1	31.5 (4-59)
Giant cell tumors of the tendon sheath	68	D3	36-32	1.12:1	38.2 (13-58)
Epidermal Cyst	14	Phalanx	6-8	1:1.33	33.7 (6-61)
Fibroma, Fibrolipoma	23	Phalanx	10-13	1:1.30	34.2 (12-55)
Glomus tumor	10	D4	8-2	4:1	30.7 (19-42)
Hemangioma	35	D2	19-16	1.18:1	11.4 (5-17)
Ganglion cyst	84	Left wrist	59-25	2.36:1	39.8 (8-60)
Lipoma	19	Dorsum of hand	11-8	1.37:1	28.3 (6-49)
Neurinoma, Schwannoma	28	Pulpa	13-15	1:1,15	27.6 (4-60)
Pyogenic Granuloma	108	D3	40-68	1:1.25	37.9 (22-61)
Others	30		12-18	1:1.5	31.3 (18-59)

Glomus tumors occurred four times more frequently in female than male patients, and ganglion cysts were seen 2.36 times more frequently in female than male patients. Besides, arteriovenous malformations, giant cell tumors of the tendon sheaths (GCTTS) and lipomas were more frequent in female patients than male patients. However, epidermal cysts, fibromas, fibrolipomas, neurinomas, schwannomas and pyogenic granulomas were more frequent in male patients than female patients (Table 2).

Discussion

According to our study, the most common benign soft tissue tumors of the hand was pyogenic granuloma [8-10]. Pyogenic granuloma is a benign vascular tumor that occurs on the mucosal membranes and skin. Pyogenic granuloma was mostly seen in fingertips, lips, the gingiva, face, and tongue. Less common sites were trunk, vulva, arms, legs, and conjunctiva [11-14]. These lesions could easily bleed when exposed to trauma. These lesions may have a polypoid form with a pedicle, or they may be as smooth as sessile. Most of them were in red or reddish-brown color. Darker lesions could mimic the nodular malignant melanoma [15].

A minority of the cases of the pyogenic granuloma follow a trauma, topical and systemic retinoid therapy,

granulocyte colony-stimulating factor therapy, reverse transcriptase inhibitor therapy, insect bite, burn, scald or cryotherapy although there is no cause for these lesions in the majority of cases [16-22].

In our study, we diagnosed 108 patients with a pyogenic granuloma (25 % of all benign tumors), most of them were localized on the third phalanx. All of them were treated by excision and primary suture. Alternative treatments of pyogenic granuloma were silver nitrate, electrocauterization, laser applications and plucking. However, the best treatment modality was excision [23-26]. If any tissue was left, pyogenic granuloma tended to recur. We must keep in mind amelanotic melanoma and squamous cell carcinoma for differential diagnosis [27].

According to other studies in the literature, the most common benign tumor of the hand was ganglion cysts, although pyogenic granuloma was the most common tumor in our study [27]. In our study, ganglion cyst was second common benign tumors of the hand. Although its underlying causes are unknown, mucinoid degeneration of colloid tissue is the best theory. Ganglion cysts mostly arise from the dorsal wrist, volar wrist, dorsal distal interphalangeal joint and volar metacarpophalangeal joint [27].

Angelides et al. [24] showed that 60-70% of ganglion cysts were localized in the dorsum of the hand and 18-20 % in the volar surface of the hand, and they mostly occurred in women in the 3rd and fourth decade. In our study, ganglion cysts were 20% of all benign soft tissue tumors of the hand. 70.2 % of patients were female, and 29.8% were male, and ganglion cysts were mostly localized in the dorsal surface of the left-hand wrist.

Pardini et al. [26] explained that, if ganglion cysts caused no pain and they did not restrict movement of the hand then, there was no indication for excisional biopsy. However, Uriburu et al. [27] recommended excision if there is recurrence in radiography. Although mostly asymptomatic, intraosseous ganglion cysts should be kept in mind during excisions. The rate of recurrence would be lower if ganglion cysts were excised accurately and carefully. The rate of recurrence was high if the treatment was made by compression, injection of a steroid or sclerosant, and aspiration. Injury of radial artery may be seen during excision, especially in the series of surgical excisions in which there is adherence of volar ganglion cysts to the radial artery [27].

According to our study, giant cell tumors of the tendon sheaths were the third most common soft tissue tumors of the hand. In the literature, some studies indicated that this tumor was described as the second most common tumor of the hand [28]. These tumors have been mostly seen on the volar side of the fingers [29]. In our study, index finger was the most affected site. Giant cell tumors of the tendon sheath could become painful if it impinged on digital nerves or interfered with joint function although they were generally painless. They could be differentiated from ganglion cysts by light. The light did not pass through the giant cell tumors of the tendon sheath [28].

Giant cell tumors had no risk of becoming malignant, but they could show locally aggressive behavior and could grow to a larger size. Complete surgical excision was curative. %5-50 recurrence could be seen if the tumor was not excised completely [28-30].

Our study had some limitations which have to be pointed out. We could include the benign bony tumors of the hand to our study. The other limitation of our study was that we could not evaluate the incidence of recurrence of benign soft tissue tumors of the hand that we performed surgical excision. The conflict with the literature of our study regarding the most common benign soft tissue tumors of the hand may be due to the treatment of ganglion cyst patients by the orthopedic surgeons.

As a conclusion, benign soft tissue tumors are the most common tumors of the hand. A comprehensive history and detailed physical examination performed by a specialist are important in the diagnosis and management of the tumor. The vast majority of hand tumors are benign. If a tumor of the hand is suspected, the surgical biopsy of the benign soft tissue tumor should be performed before definitive treatment.

Conflict of interest statement

The authors have no conflicts of interest to declare.

References

1. Teh J, Whiteley G. MRI of soft tissue masses of the hand and wrist. *Br J Radiol* 2007;80:47-63.
2. Martinez JC, Otley CC. The management of melanoma and nonmelanoma skin cancer: A review for the primary care physician. *Mayo Clin Proc* 2001;76:1253-65.
3. Garcia J, Bianchi S. Diagnostic imaging of tumors of the hand and wrist. *Eur Radiol* 2001;11:1470-82.
4. Wolfe S, Pederson W, Kozin SH. Bone and Soft Tissue Tumors. In: Athanasian EA (ed.) *Green's Operative Hand Surgery*. Elsevier Churchill Livingstone, Pennsylvania, 2005;2211-63.
5. Payne WT, Merrell G. Benign bony and soft tissue tumors of the hand. *J Hand Surg* 2010;35:1901-10
6. Ingari JV, Faillace JJ. Benign Tumors of Fibrous Tissue and Adipose Tissue in the Hand. *Hand Clin* 2004;20:243-9.
7. Posch JL. Tumors of the Hand. *J Bone Joint Surg* 1956;38:517-40.

8. Mills SE, Cooper PH, Fechner RE. Lobular capillary hemangioma: The underlying lesion of pyogenic granuloma. A study of 73 cases from the oral and nasal mucous membranes. *Am J Surg Pathol* 1980;4:471-9.
9. Shimizu K, Naito S, Urata Y, Sekine I, Kondo T, Katayama I. Inducible nitric oxide synthase is expressed in granuloma pyogenicum. *Br J Dermatol* 1998;138:769-73.
10. Grosshans E. Pyogenic granuloma: Who are you? *J Eur Acad Dermatol Venereol* 2001;15:106-7.
11. Kerr DA. Granuloma pyogenicum. *Oral Surgery* 1951;4:158-76.
12. Pagliai KA, Cohen BA. Pyogenic granuloma in children. *Pediatr Dermatol* 2004;21:10-3.
13. Kaur T, Gupta S, Kumar B. Multiple pyogenic granuloma involving female genitalia: A rare entity? *Pediatr Dermatol* 2004;21:614-5.
14. Patrice SJ, Wiss K, Mulliken JB. Pyogenic granuloma (lobular capillary hemangioma): A clinicopathologic study of 178 cases. *Pediatr Dermatol* 1991;8:267-76.
15. Leyden JL, Master GH. Oral cavity pyogenic granuloma. *Arch Dermatol* 1973;108:226-8.
16. De Kaminsky AR, Otero AC, Kaminsky CA, Shaw M, Formentini E, Abulafia. Multiple disseminated pyogenic granuloma. *Br J Dermatol* 1978;98:461-4.
17. Naimer SA, Cohen A, Vardy D. Pyogenic granuloma of the penile shaft following circumcision. *Pediatr Dermatol* 2002;19:39-41.
18. Williams LH, Fleckman P. Painless periungual pyogenic granulomata associated with reverse transcriptase inhibitor therapy in a patient with human immunodeficiency virus infection. *Br J Dermatol* 2007;156:163-4.
19. Lenczowski JM, Cassarino DS, Jain A, Turner ML. Disseminated vascular papules in an immunodeficient patient being treated with granulocyte colony-stimulating factor. *J Am Acad Dermatol* 2003;49:105-8.
20. Teknetzis A, Ioannides D, Vakali G, Lefaki I, Minas A. Pyogenic granulomas following topical application of tretinoin. *J Eur Acad Dermatol Venereol* 2004;18:337-9.
21. Momeni AZ, Enshaieh S, Sodifi M, Aminjawaheri M. Multiple giant disseminated pyogenic granuloma in three patients burned by boiling milk. *Int J Dermatol* 1995;34:707-10.
22. Cecchi R, Giomi A. Pyogenic granuloma as a complication of cryosurgery for venous lake. *Br J Dermatol* 1999;140:373-4.
23. Plate AM, Lee SJ, Steiner G, Posner MA. Tumorlike Lesions and Benign Tumors of the Hand and the wrist. *J Am Acad Orthop Surg* 2003;11:129-41.
24. Wolfe S, Pederson W, Kozin SH. Ganglions of the Hand and the Wrist. In: Angelides AC (ed.) *Green's Operative Hand Surgery*. Churchill-Livingstone, New York, 1999:2171-83.
25. Shapiro PS, Seitz WH Jr. Non-neoplastic Tumors of the Hand and Upper Extremity. *Hand Clinics* 1995;11:133-60.
26. Pardini AG, Freitas AD, Gusmao NS. The natural history of wrist ganglion. *IFSSH, Vancouver, Canada* 1998;89
27. Uriburu JF, Levy VD. Intraosseous Ganglia of the scaphoid and Lunate Bones. *J Hand Surg* 1999;24; 508-15.
28. Hsu CS, Hentz V, Yao J. Tumors of the hand. *Lancet Oncol* 2007;8:157-66.
29. Nahra ME, Bucchieri JS. Ganglion cysts and other tumor related conditions of the hand and wrist. *Hand Clin* 2004;20:249-60.
30. Glowacki KA, Weiss AP. Giant cell tumors of tendon sheath. *Hand Clin* 1995;11:245-53.