

Hydrothorax caused by catheter malposition misdiagnosed via using plain radiography

Ayşe Betül Ergül¹, Alper Özcan¹, Yasemin Altuner Torun²

¹Department of Pediatric Intensive Care Unit, University of Health Sciences, Kayseri Training and Research Hospital, Kayseri, Turkey

²Department of Pediatric Hematology, University of Health Sciences, Kayseri Training and Research Hospital, Kayseri, Turkey

Abstract

We report the case of a child with hydrothorax caused by the misidentification of catheter malposition using plain radiography. A 9-month-old girl underwent central venous catheterization via the right subclavian vein. Catheter tip was evaluated mistakenly as in the right atrium by plain radiography. The catheter was retracted 2 cm and 1/3 normal saline infusion was initiated at 15 ml/hr. The patient became hypoxemic at the 20th hour of fluid infusion. On radiography, the right lung was completely opaque and the catheter tip was positioned in the right lung. Bedside sonography revealed a massive pleural effusion in the right lung and the catheter tip in the right pleural space. The catheter was removed and the pleural effusion was drained via chest tube. The location of the catheter tip should be determined by an accurate technique before infusing fluid. Plain radiography can be misleading for the detection of malposition.

Keywords: Child; Hydrothorax; Complication; Central Venous Catheterization; Malposition.

INTRODUCTION

Central venous catheters (CVCs) are widely used for hemodynamic monitoring, fluid and drug administration, infusion of blood products, and interventional procedures such as hemodialysis and plasmapheresis. Moreover, CVCs are the most commonly used catheters to establish peripheral venous access in patients hospitalized for prolonged periods (1). Hydrothorax is a rare complication related to central venous catheterization (2). Jabeen et al. (3) reported that subclavian intervention can result in rupture of the vessel wall and subsequent misplacement of the catheter tip in the pleural space. Hydrothorax may result from fluid infusion into a CVC with the catheter tip located in the intra-pleural space (4).

Although chest radiographs are widely used to detect malposition of CVCs, recent studies have shown that echocardiographic assessment of CVC position using bedside sonography is more reliable (5). Here, we report a case of hydrothorax caused by a failure of plain radiography to detect catheter misplacement.

CASE REPORT

Central venous catheterization via the right subclavian vein was performed to obtain peripheral access to the central venous system in a 9-month-old girl, diagnosed

with nonketotic hyperglycinemia, who was receiving mechanical ventilation due to lack of spontaneous breathing in the pediatric intensive care unit. A 4 Fr double-lumen CVC was inserted according to anatomical landmarks using the Seldinger technique. Blood was aspirated from the puncture, and the guidewire was advanced. After placement, we couldn't obtain enough blood from the catheter and the chest radiograph revealed that the CVC was positioned in the right atrium by mistake. Blood gas analysis was not performed as to insufficient blood sample. The catheter was retracted 2 cm (Figure 1), and 1/3 normal saline fluid infusion was initiated at 15 ml/hr. The patient's general status deteriorated and her oxygen saturation decreased 20 h after catheterization. Transcutaneous oxygen saturation of the patient dropped off at 75% and tachycardia (180/min) was started. Breathing sounds were attenuated over the right lung, and a standing chest radiograph revealed that the right lung was completely opaque and the catheter was located in the right lung (Figure 2). Bedside sonography revealed diffuse pleural fluid on the right side and echogenicity consistent with transude. The fluid infusion was stopped and the catheter was removed. The pleural fluid was drained via a chest tube (Figure 3). The patient's clinical status completely improved and her saturation returned to normal after drainage of the fluid in the pleural space by the chest tube.

Received: 07.03.2017 **Accepted:** 08.05.2017

Corresponding Author: Yasemin Altuner Torun, Department of Pediatric Hematology, University of Health Sciences, Kayseri Training and Research Hospital, Kayseri, Turkey E-mail: yaseminaltuner@gmail.com

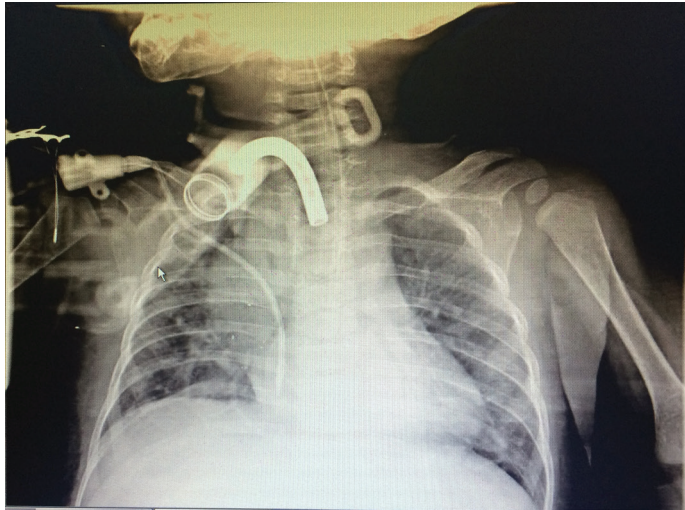


Figure 1. The appearance of catheter tip right after placing the catheter by plain radiography

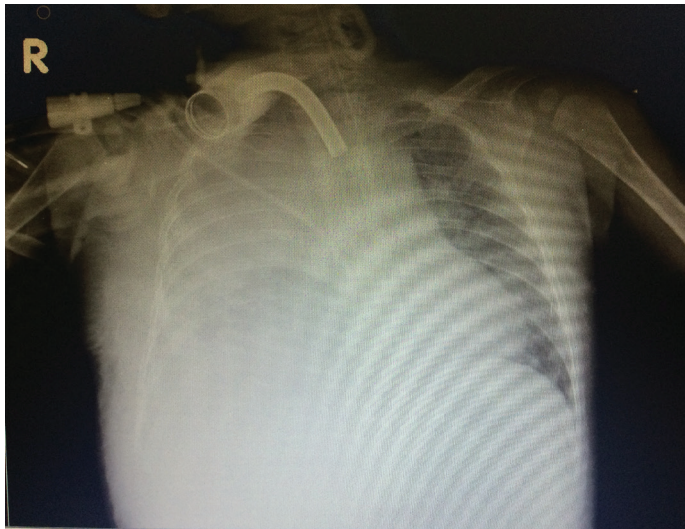


Figure 2. Radiograph showing hydrothorax in the right lung after fluid infusion and the misplaced catheter tip in the right pleural space

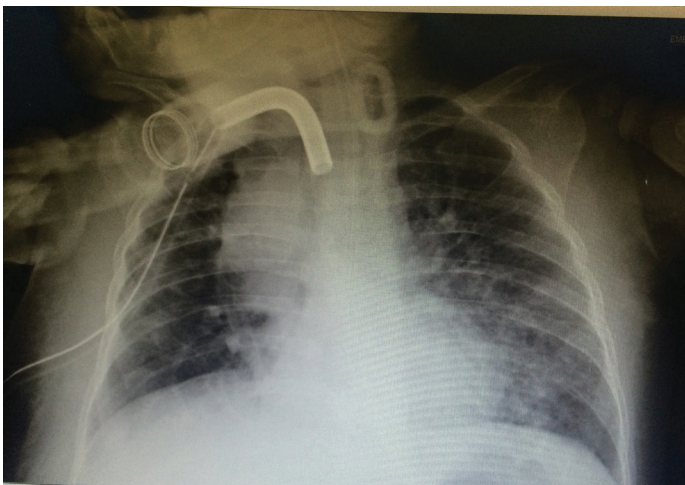


Figure 3. Radiograph showing the absence of opacity on the radiograph after the fluid was drained via a tube inserted into the right lung

DISCUSSIONS

In pediatric patients, CVCs are most frequently used to provide peripheral access to the central venous system. Moreover, CVCs offer safe access to the central venous system in chronic patients (1). Our patient, diagnosed with nonketotic hyperglycinemia and receiving mechanical ventilation in the pediatric intensive care unit, underwent central venous catheterization to obtain peripheral access nine times during her hospital stay. Although CVC placement is considered to be safe when performed by an experienced practitioner, a number of procedure-related complications have been reported. Common mechanical complications include arterial puncture, pneumothorax, arrhythmia, malpositioning, and thrombosis. Less common complications include bleeding as a result of great vessel injury, airway injury, medulla spinalis trauma, chylothorax, pleural effusion, cardiac tamponade, catheter rupture, guidewire entrapment, fistula formation, hemothorax, pulmonary embolism caused by a ruptured catheter, cardiac arrhythmia, nerve injury, mediastinal hematoma, and thrombosis (6).

Hydrothorax is a rare condition (2). Jabeen et al. (3) reported a case of fatal hydrothorax in a 1-week-old neonate caused by a catheter tip malpositioned in the pleural space as a result of superior vena cava perforation during catheterization of the external jugular vein. Moreover, despite accurate positioning of the catheter tip, mechanical changes due to respiration, blood flow, postural changes, and neck movements can cause vascular erosion and perforation resulting in catheter migration during the first intervention in younger children (7). Catheters inserted via the left subclavian vein tend to come in contact with the right wall of the superior vena cava at a more perpendicular angle and are at increased risk of perforating the venous wall (8). In our patient, the catheter penetrated the posterior wall of the vein and entered the pleural space during catheterization, suggesting that interventions using a right sided approach are safer (8).

The optimal CVC tip location is just above the junction of the right atrium and superior vena cava. Catheters in other locations are considered to be malpositioned. Central venous catheterization via the subclavian vein has the highest incidence of malpositioning (9), and the most common malposition is in the right atrium. Malpositioning may be the result of an inappropriate catheter size or excessive advancement of the catheter. Stroud et al. (10) derived a formula based on body surface area to determine the optimal catheter length to prevent placement distal to the junction of the right atrium and vena cava. Malposition is less common in sonography-assisted catheterization (5,9).

Resistance when advancing the guidewire, or failure to aspirate blood after catheter insertion, are signs of malposition (5). In our patient, the Seldinger technique was used to insert the catheter, blood was aspirated following

the initial puncture, and the guidewire was advanced smoothly. However, we were unable to aspirate blood from the line after insertion. A chest radiograph revealed that the catheter was located in the right atrium. We retracted the catheter 2 cm and initiated the fluid infusion.

Most clinicians do not routinely perform chest radiography after catheterization. Sonography is useful for the assessment of catheterization complications such as pneumothorax and hemothorax (2). In our case, misplacement of the catheter tip into the pleural space was misjudged on plain radiography. The catheter that appeared in the pleural space on the chest X-ray was superimposed on the cardiac silhouette. Thus, the malposition was not accurately assessed. We recommend that the position of the catheter tip be confirmed before fluid is infused into the catheter. Bedside sonography is the most effective method for ensuring that the catheter tip is located at the junction of the right atrium and vena cava superior (3). Agitated saline bubble-enhanced transthoracic echocardiography is a highly reliable method for assessing the location of the catheter tip (2). Hydrothorax may result from the infusion of fluid into a CVC misplaced in the pleural space. Thus, the correct location of the catheter tip should be confirmed before commencement of an infusion. However, radiological evaluations should be used for a definitive diagnosis.

Finally, plain radiographs can be misleading for the detection of malposition. Bedside sonography is more reliable than chest radiography, and is the preferred method for assessing malposition and for identifying mechanical complications such as pneumothorax and hemothorax.

REFERENCES

1. R Isguder, Gulfidan G, Agin H, Devrim I, Karaarslan U, Unal N. Central venous catheterization in pediatric intensive care unit: a four-years experience. *CAYD* 2014;1014(1):31-8.
2. Badada V, Singh TK, Srivastava U. Accidental placement of central venous catheter in lung parenchyma causing hydrothorax. *Saudi J Anaesth* 2014;8(1):113-4.
3. Jabeen S, Murtaza G, Hanif MZ, Morabito A, Khalil B. Migration of indwelling central venous catheter and fatal hydrothorax. *European J Pediatr Surg Rep* 2014;2(1):32-4.
4. Kumar M, Singh A, Sidhu KS, Kaur A. Malposition of subclavian venous catheter leading to chest complications. *J Clin Diagn Res* 2016;10(5):16-8.
5. Wen M, Stock K, Heemann U, Aussieker M, Küchle C. Agitated saline bubble-enhanced transthoracic echocardiography: a novel method to visualize the position of central venous catheter. *Crit Care Med* 2014;42(3):231-3.
6. Lennon M, Zaw NN, Pöpping DM, Wenk M. Procedural complications of central venous catheter insertion. *Minerva Anesthesiol* 2012;78(11):1234-40.
7. Domino KB, Bowdle TA, Posner KL, Spitellie PH, Lee LA, Cheney FW. Injuries and liability related to central vascular catheters: a closed claims analysis. *Anesthesiology* 2004;100(6):1411-8.
8. Kunizawa A, Fujioka M, Mink S, Keller E. Central venous catheter-induced delayed hydrothorax via progressive erosion of central venous wall. *Minerva Anesthesiol* 2010;76(10):868-71.
9. Brass P, Hellmich M, Kolodziej L, Schick G, Smith AF. Ultrasound guidance versus anatomical landmarks for subclavian or femoral vein catheterization. *Cochrane Database Syst Rev* 2015;9:1.
10. Stroud A, Zalieckas J, Tan C, Tracy S, Zurakowski D, Mooney DP. Simple formulas to determine optimal subclavian central venous catheter tip placement in infants and children. *J Pediatr Surg* 2014;49(7):1109-12.