

# Hyperbaric oxygen therapy in peroneal nerve damage due to lithotomy position

Serkan Akan, Caner Ediz, Muhammed Cihan Temel, Omer Yilmaz

Sultan Abdulhamd Han Education and Research Hospital, Department of Urology, Istanbul, Turkey

Copyright © 2019 by authors and Annals of Medical Research Publishing Inc.

## Abstract

Peripheral neuropathies can be seen in patients who are operated in lithotomy position. In this case report, patient which had right drop foot after urethroplasty surgery in lithotomy position was treated. Electromyography (EMG) was performed at postoperative 1st day and demonstrated right peroneal nerve palsy. Physiotherapy (knee extension, cycling, and passive dorsiflexion), vitamin B complex (B1, B6, folic acid and B12) and daily hyperbaric oxygen treatment were started. Fifth day after surgery, improvement of moving the right foot was detected clinically. Patient was discharged on 7th postoperative day and neurologist suggested to continue physiotherapy and vitamin B complex for 3 weeks. After this period, control EMG showed the development of peroneal nerve functions. The patient had a fully functional right foot with all these treatments one month after surgery. Effectivity of hyperbaric oxygen in treatment of peripheral nerve degeneration was seen in several studies in literature (4). In a few studies, the effect of hyperbaric oxygen on peroneal nerve palsy has not been demonstrated (5). The patient recovered earlier than other patients in literature. In this case, the treatment difference was hyperbaric oxygen treatment from other cases in literature. Before the start of lithotomy operations, patients should be carefully evaluated for peroneal nerve palsy risk factors and appropriately positioned to prevent iatrogenic peroneal nerve palsy in the operation. After operation, if peroneal nerve palsy develops, physiotherapy should start as soon as possible. Hyperbaric oxygen is kept in mind as supplemental treatment even if it is not in standard treatment protocol in peroneal nerve palsy.

**Keywords:** Hyperbaric oxygen; peroneal nerve; urethroplasty; lithotomy position.

## INTRODUCTION

Peripheral neuropathies can be seen in patients by reason of operations in lithotomy position. Some risk factors are identified for lower extremity nerve palsy in lithotomy position such as diabetes mellitus, smoking, thin body habitus, anatomic anomalies, duration of surgery, presence of subclinical neuropathies, alcoholism, familial neuropathies (1,2). Most of the patients' recovery motor functions of feet in 3-6 months with conservative treatment were healed (3). Several studies have investigated the effect of hyperbaric oxygen treatment on peripheral nerve regeneration although hyperbaric oxygen treatment doesn't present in classical treatment protocol (4,5). In this case report, patient which had right drop

foot after urethroplasty surgery in lithotomy position was treated via physiotherapy, vitamin B complex (B1, B6, folic acid and B12) and 7 days hyperbaric oxygen earlier than expected.

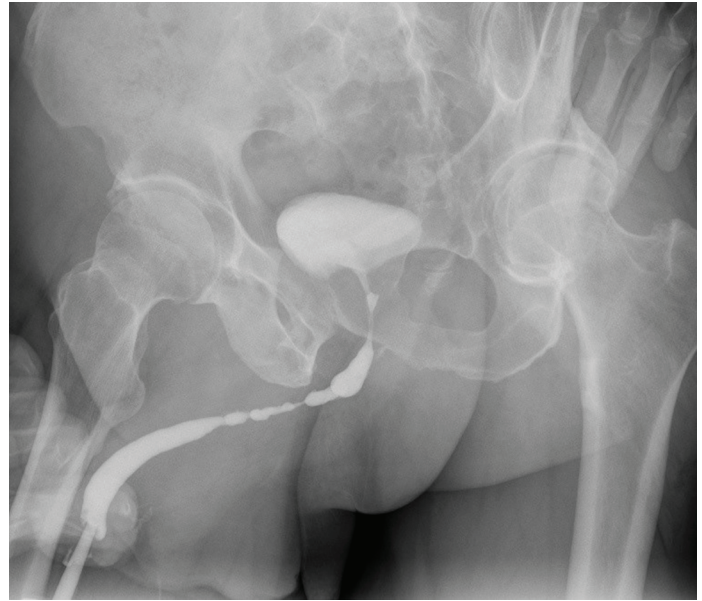
## CASE REPORT

A 62 years old male patient applied to our clinic with complaint of weak urination and incomplete bladder emptying. Patient had hypertension and lumbar disc herniation. After evaluation of the patient, urethral stricture was found from end of penil urethra to external sphincter about 40 mm by retrograde urethrography (Figure 1). Buccal mucosal graft urethroplasty was successfully performed in lithotomy position and continued about

**Received:** 09.07.2019 **Accepted:** 06.08.2019 **Available online:** 28.08.2019

**Corresponding Author:** Serkan Akan, Sultan Abdulhamd Han Education and Research Hospital, Department of Urology, Istanbul, Turkey, **E-mail:** drserkanakan@hotmail.com

200 minutes. Patient was immobile first 12 hours after operation. When the patient was mobilized on the first postoperative day, he noticed that he can't move his right foot effectively. On physical examination, the patient could not achieve dorsiflexion of the right foot. But plantar flexion and sensation were normal. After neurologic examination by an experienced neurologist, patient was diagnosed as peroneal neuropathy. Electromyography (EMG) was performed and demonstrated right peroneal nerve palsy (Table 1). Physiotherapy (knee extension, cycling, and passive dorsiflexion), vitamine B complex (B1, B6, folic acid and B12) and daily hyperbaric oxygen treatment were started. Fifth day after surgery, improvement of moving the right foot was detected clinically. Patient was discharged on 7th postoperative day and neurologist suggested to continue physiotherapy and vitamin B complex for 3 weeks. After this period, developments of peroneal nerve functions were showed in control EMG (Table 2). The patient had a fully functional right foot with physiotherapy, Vitamin B Complex and short-term hyperbaric oxygen treatments approximately 1 month after surgery.



**Figure 1.** Retrograde Urethrography, Urethral stricture was found from end of penile urethra to external sphincter about 40 mm by retrograde urethrography

**Table 1. Pathological EMG. In the nerve conduction study, motor response at right peroneal nerve was not taken and a significant low amplitude response was obtained at the left peroneal nerve. No significant pathology was detected in sensory conduction**

<b>Sensory CNS</b>					
Nerve/Sites	Rec. Site	Latency Ms	Peak Ampl. uV	Distance Cm	Velocity m/s
R SURAL – Lat Malleolus					
Calf	Lat Malleolus	2.4	18	13	54.2
L SURAL – Lat Malleolus					
Calf	Lat Malleolus	2.05	23	13	63.4
<b>Motor CNS</b>					
Nerve/Sites		Latency Ms	Ampl. mV	Distance Cm	Velocity m/s
R COMM PERONEAL - EDB					
Ankle		No Signs			
L COMM PERONEAL - EDB					
Ankle		6.8	0.9	8	
Fib Heat		12.95	1.1	30	48.8
Knee		14.9	1.1	10	51.3
R TIBIAL (KNEE) - AH					
Ankle		5.35	4.5		
Knee		15.25	4.1	40	40.4
L TIBIAL (KNEE) - AH					
Ankle		5.15	5.4		
Knee		14	4.3	39	44.1
R COMM PERONEAL - Tib Ant					
Fib Heat		4.55	3		
Knee		7.35	2.2	10	35.7

**Table 2. Normal EMG. In the nerve conduction study, bilateral motor response tends to improve**

<b>Sensory CNS</b>					
Nerve/Sites	Rec. Site	Latency Ms	Peak Ampl. uV	Distance Cm	Velocity m/s
R SURAL – Lat Malleolus					
Calf	Lat Malleolus	3.75	17.5	16	42.7
L SURAL – Lat Malleolus					
Calf	Lat Malleolus	2.8	16	13	46.4
<b>Motor CNS</b>					
Nerve/Sites		Latency Ms	Ampl. mV	Distance Cm	Velocity m/s
<b>R COMM PERONEAL - EDB</b>					
Ankle		4.0	4.4	9.5	
Fib Heat		10.3	4.2	28.5	45.2
Knee		12.15	4.2	8.5	45.9
<b>L COMM PERONEAL - EDB</b>					
Ankle		4.85	3.3	10.5	
Fib Heat		10.55	2.7	26	45.6
Knee		12.55	1.8	9.5	47.5
<b>R TIBIAL (KNEE) - AH</b>					
Ankle		4.85	8.8	11.5	
Knee		14.35	9.3	41	43.2
<b>L TIBIAL (KNEE) - AH</b>					
Ankle		5.3	8.4	13	
Knee		13.85	8.6	37	43.3

## DISCUSSION

Common peroneal nerve palsy is one of the relatively common nerve injuries related to the lithotomy position which are usually used for urologic, gynecologic and colorectal surgical procedures and it represents the most common lower-extremity nerve injury(6).

The most likely causes of perioperative neuropathies are pressure, stretching, and ischemia which can cause demyelination, or in severe cases they can cause axonal degeneration. Clinical manifestations range from transient paresthesia, such as numbness and pain, or muscle weakness to a permanent loss of sensory and motor function. It is recommended that external pressure loading to the skin surface be kept low level as much as possible. (7).

In the literature, one of the studies is a prospective study which 991 adults are operated in lithotomy position. In this study; Lower-limb neuropathies were developed in 15 patients (1.5%) and the peroneal nerve was involved in 3 patients (0.3%) (8). In another study which is include 377 patients operated in lithotomy position, lower extremity neuropathies developed in 5 (1.3%) postoperatively. Variables were age, height, weight, body mass index (BMI), smoking status, surgeon, date of surgery, and intraoperative times. Only increased intraoperative time was identified as a potential risk factor for the development of this complication (9).

In lithotomy position, prolonged operation time is identified as 2-4 hours (8,10). Warner and associates estimated that for each hour in the lithotomy position, the risk for motor neuropathy increases 100-fold (2). In this case it took

200 minutes. There was no risk factor except lumbar disc herniation at this patient.

Peroneal nerve palsy after lithotomy positioned operations can treat by conservatively and recovery totally between 3-6 months (3,8). In this case, peroneal nerve palsy which was proved by EMG, improved 1 month after operation. This patient recovered earlier than others. The treatment difference of this case from other cases and literatures was hyperbaric oxygen treatment.

Effectivity of hyperbaric oxygen in treatment of peripheral nerve degeneration is seen in several studies in literature (4). In a few studies, the effect of hyperbaric oxygen on peroneal nerve palsy has not been demonstrated (5). Ischemic process in pathophysiology of peripheral nerve palsy supports that hyperbaric oxygen treatment can be effective in peripheral neuropathies although there is no enough research about hyperbaric oxygen treatment in peripheral nerve palsy. Hyperbaric oxygen therapy has been shown to reduce oxidative stress under pathological conditions and to improve edema and hypoxic condition after spinal cord injury in experimental models (11). It has been reported that hyperbaric oxygen therapy increases axonal regeneration in peripheral nerve injuries and can similarly accelerate peripheral nerve healing in crush injury (12).

## CONCLUSION

Before the operations performed in the lithotomy position, patients should be carefully evaluated for peroneal nerve palsy risk factors and appropriately positioned to prevent iatrogenic peroneal nerve palsy in the operation. After operation, if peroneal nerve palsy develops, physiotherapy

should start as soon as possible. Hyperbaric oxygen should be kept in mind as supplemental treatment even if it is not in standard treatment protocol in peroneal nerve palsy.

*Competing interests: The authors declare that they have no competing interest.*

*Financial Disclosure: There are no financial supports*

*Serkan Akan ORCID: 0000-0002-6066-0401*

*Caner Ediz ORCID: 0000-0001-9717-1209*

*Muhammed Cihan Temel ORCID: 0000-0002-8677-8504*

*Omer Yilmaz ORCID: 0000-0002-4433-9431*

## REFERENCES

1. Mizuno J, Takahashi T. Factors that increase external pressure to the fibular head region, but not medial region, during use of a knee-crutch/leg-holder system in the lithotomy position. *Ther Clin Risk Manag* 2015;11:255-61.
2. Warner MA, Martin JT, Schroeder DR, et al. Lower-extremity motor neuropathy associated with surgery performed on patients in a lithotomy position. *Anesthesiology* 1994;81:6-12.
3. Nonthasoot B, Sirichindakul B, Nivatvongs S, et al. Common peroneal nerve palsy: an unexpected complication of liver surgery. *Transplant Proc* 2006;38:1396-7.
4. Bajrovic FF, Sketelj J, Jug M, et al. The effect of hyperbaric oxygen treatment on early regeneration of sensory axons after nerve crush in the rat. *J Peripher Nerv Syst* 2002;7:141-8.
5. Santos PM, Zamboni WA, Williams SL, et al. Hyperbaric oxygen treatment after rat peroneal nerve transection and entubulation. *Otolaryngol Head Neck Surg* 1996;114:424-34.
6. Barnett JC, Hurd WW, Rogers RM Jr, et al. Laparoscopic positioning and nerve injuries. *J Minim Invasive Gynecol* 2007;14:664-72.
7. Mizuno J, Namba C, Takahashi T. Measurement of external pressure of peroneal nerve tract coming in contact with lithotomy leg holders using pressure distribution measurement system BIG-MAT®. *Masui*. 2014; 63:1167-71.
8. Warner MA, Warner DO, Harper CM, et al. Lower extremity neuropathies associated with lithotomy positions. *Anesthesiology* 2000;93:938-42.
9. Koç G, Tazeh NN, Joudi FN, et al. Lower extremity neuropathies after robot-assisted laparoscopic prostatectomy on a split-leg table. *J Endourol* 2012;26:1026-9.
10. Irvin W, Andersen W, Taylor P, et al. Minimizing the risk of neurologic injury in gynecologic surgery. *Obstet Gynecol* 2004;103:374-82.
11. Topuz K, Colak A, Cemil B, et al. Combined hyperbaric oxygen and hypothermia treatment on oxidative stress parameters after spinal cord injury: an experimental study. *Arch Med Res* 2010;41:506-12.
12. Sanchez EC. Hyperbaric oxygenation in peripheral nerve repair and regeneration. *Neurol Res* 2007;29:184-98.