A CASE SERIES OF RIGHT SUBCOSTAL INCISIONAL HERNIA AFTER OPEN CHOLECYSTECTOMY: AN IMPORTANT LESSON FOR SURGICAL RESIDENTS

Hikeno K Yeptho [1,a], **Rituparna Dasgupta** [a], **Ramakrishnan. S** [a] **and Binay Kumar** [a]
[a] Department of General Surgery, RIMS, Ranchi, India. PIN-834009.

ABSTRACT Post-operative scars on the abdomen may predispose to the occurrence of ventral hernia through any musculofascial defect, which usually develops in the early postoperative period and is generally neglected or unnoticed, often leading to large incisional hernias with complications like dermatitis and ulceration of overlying skin, recurrent subacute intestinal obstruction and strangulation of bowel. Of all hernias, an incisional hernia can be the most challenging to treat. Although it is a very common complication of wound healing after surgery, it has been rarely found to develop after open cholecystectomy. We present a case series of four patients with an incisional hernia after open cholecystectomy done via Kocher incision who were diagnosed pre-operatively with the help of radiological investigations, following which laparotomy with mesh hernioplasty was done as a definitive treatment.

KEYWORDS Incisional hernia, cholecystectomy, bowel obstruction, ventral hernia

Introduction

An incisional hernia is defined as "any abdominal wall gap with or without a bulge in the area of a postoperative scar palpable or perceptible by clinical examination or imaging".[1] Risk factors like inappropriate surgical techniques, wound factors like surgical site infection, and patient factors like obesity may predispose to developing an incisional hernia. Ninety percent of incisional hernias occur within three years of surgery, the incidence being reported in up to 20.6%, but it has been rarely seen following open (5.9%) and laparoscopic (1.6%) cholecystectomy.[2] Four cases of subcostal incisional hernia post open cholecystectomy were encountered in four years and are discussed here.

Case - 1

A 60-year-old obese lady came to our outpatient department (OPD) with a painless lump in her right upper quadrant of the abdomen for 12 years (Figure 1). She underwent open cholecystectomy 15 years back with no post-operative complications, followed by the development of the lump at the same site three years later, which gradually increased in size. On examination, a 15 cm x10 cm non-tender, irreducible lump with a cough impulse and doughy consistency was palpable. An abdominal wall defect of four fingers could be appreciated underlying the previous scar of length 10 cm. An ultrasound confirmed a diagnosis of incisional hernia, which showed a single defect of width 8 cm containing omental fat and was classified according to the European Hernia Society (EHS) as a right-sided L1W2 incisional hernia. General and systemic examination was normal. The lady was prepared for open incisional hernia repair. Excision of the scar tissue was done through an incision overlying the old scar. The defect was appreciated in the previous cholecystectomy wound through which a large sac was found herniating (Figure 2). Sac was found to adhere to the defect's margins, and exploration of the sac revealed omentum and a part of the transverse colon, which was viable and reduced back into the abdomen. The redundant sac was excised. Hernioplasty was done with prolene mesh using 2-0 prolene suture via preperitoneal approach. Post-operative recovery was uneventful. There was no recurrence or complications at three months of follow-up.

DOI: 10.5455/ijsm.ACASESERIESOFRIGHTSUBCOSTALINCISIONALHERNIA-1
First Received: September 15, 2021
Accepted: January 3, 2022
Associate Editor: Ivan Inkov (BG);
[1]Corresponding author: Hikeno K Yeptho (hiksyeptho@gmail.com)

Figure 1 A lady presenting with painless lump in her right upper quadrant of abdomen with an overlying scar of previous cholecystectomy

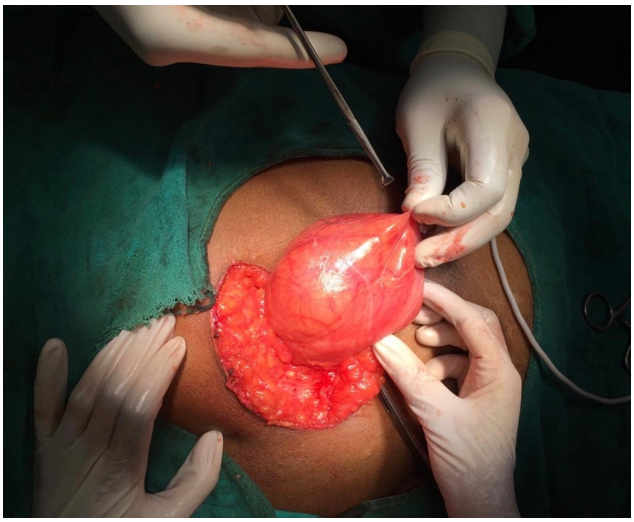

Figure 2 A large sac was found herniating through the defect in previous surgery scar

Case - 2

A 65-year-old lady who has had vitiligo with a history of hypertension and diabetes mellitus for the past 8 years presented to our OPD with the chief complaint of a significant swelling in her right upper quadrant of the abdomen for 20 years (Figure 3). She underwent open cholecystectomy 20 years back. No postoperative complications were reported by the patient. However, she developed a lump at the operated site after two months, gradually increasing in size.

The painless irreducible swelling, having a cough impulse, was 25 cm x15 cm with ill-defined margins, smooth surface and doughy consistency. A scar mark of the previous surgery length of 12 cm was present below the right subcostal margin. A defect of five finger width could be palpated along the previous incision site. General and systemic examination was normal.

Figure 3 Another lady with a large swelling in her right upper quadrant of abdomen with an overlying scar of open cholecystectomy done 20 years ago

Regular glycemic and blood pressure charting was done. A diagnosis of incisional hernia was confirmed by ultrasound imaging which showed a defect of width 10 cm with bowel and omentum as its contents and was classified as right-sided L1W2 incisional hernia. Open incisional hernia repair was decided for the lady. An incision was made through the previous scar. The defect was identified through which a sac was found containing greater omentum, a part of the transverse colon and some part of the small intestine as its content (Figure 4.). The contents were viable and were reduced back into the peritoneal cavity. The redundant sac was excised, and hernioplasty was done with prolene mesh using 2-0 prolene suture via preperitoneal approach (Figure 5.). A suction drain was placed, which was removed on the second postoperative day. Recovery was uneventful, and there were no complications at the two-month follow-up.

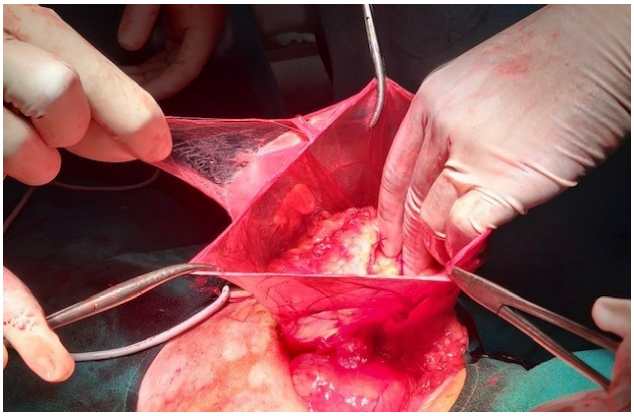

Figure 4 The sac is opened to check for viability of its contents

Case - 3

A 64-year-old obese lady came to our OPD with a lump in her right upper quadrant of abdomen for 7 months. She underwent open cholecystectomy 8 months back. Post operative period was uneventful. She then developed a swelling at the same site after one month, which gradually increased in size and attained the present size of 20 cm x15 cm. The painless and irreducible lump had ill-defined margins, a smooth surface and doughy consistency. A cough impulse was current. A scar mark of length 10 cm was present over the swelling. A defect of four finger

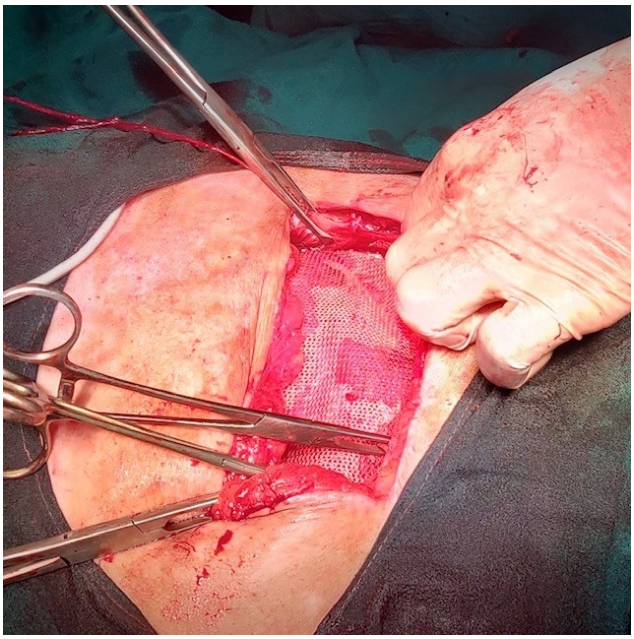

Figure 5 Preperitoneal sublay prolene mesh hernioplasty

width could be palpated along the incision site. General and systemic examination was normal. Ultrasound imaging helped in confirmation of the diagnosis, showing a defect of width 10 cm with bowel loops in the sac and was classified as Right-sided L1W2 incisional hernia. The lady was posted for open incisional hernia repair. The incision was made through the previous scar, and the defect was identified. The sac found herniating was opened to reveal greater omentum and a part of ileum as its content. The contents were found to be viable and were put back into the peritoneal cavity. Following excision of the redundant sac, hernioplasty was done with prolene mesh using 2-0 prolene suture via a preperitoneal approach. Postoperatively the patient recovered well, and no complications were present at the two-month follow-up.

Case - 4

A 38 yrs old obese lady was admitted to our ward with a complaint of swelling in her right upper quadrant of the abdomen for one year. She underwent open cholecystectomy one year back when she experienced redness and localised tenderness postoperatively at the surgical site. She was diagnosed with a surgical site infection and was treated with antibiotics. After one month, she developed a lump at the same site. The lady had a history of bronchial asthma and was under regular treatment. On examination, there was a non-tender, reducible swelling of size 6 cm x 5 cm in the right hypochondrium underlying the previous scar of length 8 cm with ill-defined margins, smooth surface and doughy consistency and a three-finger breadth defect could be appreciated along the incision site. A cough impulse was present. Ultrasound imaging suggested a defect of width 6 cm in the abdominal wall with omentum as its content. It was classified as an L1W2 incisional hernia. Open incisional hernia repair was planned. The sac was identified, and the content was found to be omentum viable and reduced back into the abdomen. The defect was then repaired using a prolene mesh in the preperitoneal space. The postoperative period was uneventful. The patient had recovered well at a one-month follow-up.

Discussion

One in every three abdominal wall closures is complicated by the failure of the fascial layers of the wound to heal, leading to the development of an incisional hernia. Although it is a common complication of wound healing after surgery, an incisional hernia through a Kocher incision is a rare presentation. Risk factors for developing incisional hernia may be modifiable, such as obesity, wound infections, straining activities, improper surgical techniques, smoking, and nutritional deficiencies, and non-modifiable, such as age, sex, family history and chronic illness. Our patients had risk factors like obesity, chronic illness like diabetes mellitus and bronchial asthma, and surgical site infection, which may have precipitated the development of an incisional hernia. The surgical technique of wound closure may also have been responsible. It has been reported that only 10% of surgical trainees know the correct suture to wound ratio, and only 40% know the correct method of abdominal wound closure.[3] Making the right incisions, using delayed absorbable monofilament sutures, applying simple continuous sutures with a minimum width of 1 cm from the wound margin and within 1 cm from the previous bite, avoiding big bites, ensuring a 4:1 suture to incision length, avoiding tension suturing, mass closure for midline incisions and standard layered closure for incisions other than midline, and using self-locking or Aberdeen knots are few important aspects which have been found to significantly reduce incisional hernia rates. This skill must be meticulously learnt by all the surgical residents during their initial training.[4,5,6]

For definitive treatment of this entity, laparoscopic incisional hernia repair is becoming popular due to less post-operative pain and wound infection rates, shorter hospital stay and increased patient comfort. It has been recommended for defects of 2-6 cm.[7] However, when recurrence rates are evaluated, there is a lack of evidence regarding the superiority of laparoscopic repair over the open technique for large-sized incisional hernias. Thus most surgeons still prefer the open technique for large and/or complex incisional hernias.[8] Open mesh hernioplasty includes the onlay, sublay and inlay techniques, out of which the sublay has been claimed to be the best.[9] Sublay among fascial and muscle planes is feasible only in midline ventral hernias. Therefore, since the subcostal region is an anatomical transition zone, a preperitoneal sublay approach was decided for our patients, which is reported to be an excellent technique with good long-term results, lower recurrence rates and reduced patient morbidity.[10] Although various techniques are available, repairing an incisional hernia is a major challenge faced by all surgeons. Its prevention should thus be prioritized before, during, and after any operative procedure. Emphasis must be given to lifestyle modification, proper pre-operative patient preparation, appropriate antibiotics, avoiding increased blood loss during surgery, prevention of peri-operative hypotension, reducing the duration of surgery, selection of appropriate sutures, applying correct surgical techniques for laparotomy wound closure and prevention of surgical site infection.[6]

In conclusion, a right subcostal incisional hernia may occur following open cholecystectomy, which can be treated with open or laparoscopic mesh hernioplasty. However, surgical management of an incisional hernia is not only arduous and technically demanding but also increases the patient's morbidity. Therefore the important take-home message is to treat or modify the precipitating factors for its prevention as well as adopt the good surgical practice to minimise its occurrence.

Patient informed consent

The patients have given written informed consent to publish this case series, including publication of the images.

Ethics committee approval

Written permission was duly taken from the Unit head of Dept. of General Surgery, RIMS, to publish this case report.

Conflict of interest

The authors declare no conflict of interests. There was no funding applied for this article.

References

1. Korenkov M, Paul A, Sauerland S, et al. Classification and surgical treatment of incisional hernia. Results of an experts' meeting. Langenbecks Arch Surg. 2001 Feb;386(1):65-73.

2. Sanz-López R, Martínez-Ramos C, Núñez-Peña JR, et al. Incisional hernias after laparoscopic vs open cholecystectomy. Surg Endosc. 1999 Sep;13(9):922-4.

3. Williams Z, Hope W. Abdominal wound closure: current perspectives. Open Access Surgery. 2015;8:89-94.

4. Chintamani. Editorial: Ten Commandments of Safe and Optimum Abdominal Wall Closure. Indian J Surg. 2018 Apr; 80 (2):105-108.

5. Jones MW, Guay E, Deppen JG. Open Cholecystectomy. 2021 Apr 30. In: StatPearls [Internet]. Treasure Island (FL): StatPearls Publishing; 2021 Jan–. PMID: 28846294.

6. Mutwali IM. Incisional hernia: Risk factors, incidence, pathogenesis, prevention and complications. Sudan Med Monit 2014;9:81-6.

7. Henriksen NA, Friis-Andersen H, Jorgensen LN, HelgstrandF. Open versus laparoscopic incisional hernia repair: nationwide database study.BJS Open.2021 Jan; 5(1):zraa010.

8. Luo Y, Mohammed Jinnaah S, Masood D, Hodgson R. Drain tube use in incisional hernia repair: a national survey. Hernia. 2021 Apr;25(2):427-433.

9. Kingsnorth A, Banerjea A, Bhargava A. Incisional hernia repair - laparoscopic or open surgery? Ann R Coll Surg Engl. 2009 Nov; 91(8):631-6.

10. Akruwala SD, Sharma VM, Study of incisional hernia repair by preperitonealmeshplasty. Nat J Med Res. 2013;3(4):328-31.