

KIKUCHI-FUJIMOTO DISEASE

Irami Araújo-Filho^{*,1}, Artur Dantas Freire^{**}, Irami Araújo-Neto^{**}, Carolina Chianca Dourado Lemos^{**}, Leticia Araújo Costa Uchôa^{**}, Amália Cíntia Meneses Rêgo^{**}, Marco Antônio Botelho Soares^{**}, José Francisco Correia-Neto[◇], Carlos André Nunes Jatobá[◇] and Ana Maria de Oliveira Ramos[◇]

^{*}Department of Surgery, Potiguar University – Laureate International Universities – Natal, Rio Grande do Norte, Brazil., ^{**}Potiguar University – Laureate International Universities – Natal, Rio Grande do Norte, Brazil., [◇]Department of Pathology, Potiguar University – Laureate International Universities, Natal, Rio Grande do Norte, Brazil.

ABSTRACT Objective:The development of associated febrile to lymphadenomegaly leads to several diagnostic hypotheses, among them the Kikuchi-Fujimoto disease.**Method:**This review was set up by searching PubMed/Medline, Web of Science and Scopus database using the following key words: “Kikuchi disease”, “Kikuchi-Fujimoto disease”, “histiocytic necrotizing”, “lymphadenitis”, “lymphadenopathy”. **Results:**We report a case in a young patient with a fever associated with the emergence of adenomegaly and weight loss in two months, associated with hepatosplenomegaly. In laboratory tests showed anaemia with erythrocyte sedimentation rate (ESH) and lactate dehydrogenase (LDH) test elevated, widened mediastinum, with bilateral pleural effusion. **Conclusion:**Excisional biopsy of supraclavicular lymph node showed Kikuchi-Fujimoto disease on microscopic examination. After histopathological confirmation, were other causes of febrile adenomegaly apart, starting dose corticosteroid immunosuppressive therapy.

KEYWORDS Kikuchi disease; Kikuchi-Fujimoto disease; histiocytic necrotizing lymphadenitis; lymphadenopathy.

Introduction

Kikuchi’s disease, also called Kikuchi-Fujimoto disease or Histiocytic Necrotizing Lymphadenitis, was initially described in young women. Is a rare pathology, of unknown cause, benign, generally characterised by cervical lymphadenopathy and fever. The histopathological examination of the lymph nodes involved differentiates Kikuchi disease of other more serious conditions.

Although the pathogenesis of Kikuchi disease is unknown, the clinical presentation is clear, and histological changes suggest an immune response of T cells and histiocytes to an infectious agent. Numerous agents urging the sickness have been proposed, including the Epstein-Barr Virus (EBV)[1,2] Human

Herpes virus type 6 and 8[3], Human Immunodeficiency virus (HIV), Parvovirus B19[4], paramyxovirus, parainfluenza viruses, Yersinia enterocolitis, and Toxoplasma[3].

Apoptotic cell death mediated by CD8 + cytotoxic T lymphocytes positive is the primary mechanism of cell destruction[5-7].

Although initially described in young women, the Kikuchi disease clearly also occurs in men. The proportion of men and women affected by three reviews was 1:4, 1:1,6 and 1:1,26, always with a predominance of women affected[8-10]. Most patients are under 40 years of age[11-14].

The most common clinical presentation of the disease is fever and cervical lymphadenopathy in a previously healthy young patient. Fever, usually low and persisted for about a week is a primary symptom in 30 to 50% of patients [8].

Methods:

This review was set up by searching PubMed, Web of Science and Scopus database using the following key words: “Kikuchi disease”, “Kikuchi-Fujimoto disease”, “histiocytic necrotizing”, “lymphadenitis”, “lymphadenopathy”.

Copyright © 2017 by the Bulgarian Association of Young Surgeons

DOI: 10.5455/IJMRCR.kikuchi-fujimoto-disease

First Received: April 04, 2017

Accepted: May 11, 2017

Manuscript Associate Editor: George Baytchev (BG)

Editor-in Chief: Cvetanka Hristova (BG)

Reviewers: Ivan Inkov (BG)

¹Prof. Dr. Irami Araújo Filho, Full Professor of the Department of Surgery, PhD in Health Sciences. Full Professor of the Post-Graduate Program in Biotechnology at Potiguar University – Laureate International Universities, Natal, Rio Grande do Norte, Brazil. E-mail: irami.filho@gmail.com

Case report

The woman, 20 years old, he began to rub the frame with symmetrical fists, knees and ankles and daily 39°C fever. Two months after the onset of symptoms, cervical tumour arose and painful. Associated to the feverish, she referred 7% of body weight in two months. Was admitted to the hospital with the symptoms described, showing Traube's space busy with splenomegaly (4cm of the costal edge left), hepatomegaly (6cm from the costal edge right) and generalized lymphadenopathy (axillary, supraclavicular chains left and cervical inguinal), being the largest lymph node found in the cervical region left measuring 0.6cm in your larger diameter, fibroblastic, painful, not acceded to plans. The laboratory tests revealed hemoglobin 9.2 g/dL; hematocrit 26.3%; leukocytes 3900/mm³ with 84% segmented and 8% of lymphocytes; 119000 platelets/mm³; erythrocyte sedimentation rate (ESR) 110 mm; 1.7 mg creatinine/dL; total protein 5 g/dL; albumin 2.4g/dL; AST 220 U/L; ALT: 79 U/L, GGT: 247 U/L, LDH:2046 IU/ML; alkaline phosphatase 551 U/L, 0.6% reticulocytes and direct Coombs test negative. The serology for hepatitis B, C and HIV negative. Had an antinuclear factor (ANF) profile with core: no reagent; metaphase chromosomal plate reagent and antibody ribonucleoprotein no reagent. The chest x-ray showed a widening of the mediastinum, pleural effusion and bilateral pulmonary consolidation right. Antibiotic therapy was initiated with Cefepime for eight days. During the diagnostic investigation was prompted computed tomography (CT) of total abdomen whose result revealed moderate ascites and lymphadenopathy in the various chains of retroperitoneal and bilaterally iliac lymph nodes. The chest CT evicted small bilateral pleural effusion, with atelectasis, mediastinal lymphadenopathy, bilaterally axillary and left the supraclavicular region. Held left supraclavicular lymph node biopsy, showing histolytic necrotizing lymphadenitis compatible with Kikuchi-Fujimoto disease, represented in figures 1-4. Corticotherapy began in dose immunosuppressive therapy for 21 days. Evolved with dramatic improvement of the clinical picture, improvement of joint pain and significant reduction of adenomegaly.

Discussion:

We report a case of Kikuchi-Fujimoto disease. The actual incidence of this disease is estimated at between 0.5%, and 5% of all analysed lymph histologically; Not found any infectious microorganism (virus or bacteria) to the case reported, but it is possible that the antigenic stimulus has been triggered by one of these[15].

Clinical condition

After reviewing the literature on the topic, it was found that the most common symptoms were fever (35%), fatigue (7%) and joint pain (7%) [16]. The most common clinical and laboratory findings were lymphadenopathy (100%), rash (10%), arthritis (7%), hepatosplenomegaly (3%), leukopenia (43%), high sedimentation rate (40%) and anaemia (23%)[16].

Systemic symptoms may accompany fever and lymphadenopathy and seem to be more prominent in patients with extranodal involvement[17]. Systemic symptoms include night sweats, nausea, vomiting, weight loss (by about 10%) and diarrhea[15-17].

A variety of other symptoms and physical signs occur sporadically in patients with Kikuchi disease. These include chills, myalgia, arthralgia, pain in the chest and abdomen,

splenomegaly and hepatomegaly, which may be associated with abdominal lymphadenopathy, as was evidenced in the case reported[8].

The involvement of lymph nodes is usually cervical and located in Kikuchi disease[18]. The nodules are moderately increased in diameter (1-2cm) but occasionally are higher (≥ 7 cm)[18]. They are typically firm, fibroelastic, discreet and furniture. The increased lymph node is often associated with a mild pain[18].

The increase in the size of the mediastinal lymph nodes is minimal and only. However retroperitoneal nodules may be involved[19,20]. The diagnosis is unlikely to be confirmed until the completion of lymph node biopsy in such patients that present with fever of unknown origin.

Laboratory tests

Most patients with Kikuchi disease have a normal blood count[8], even though leukopenia is observed in 20-32%[9,21]. Atypical lymphocytes are reported in up to 25% of patients[18]. Other less common findings include thrombocytopenia, pancytopenia, and, in those with severe disease, chronic anemia[1,22].

The erythrocyte sedimentation rate can be normal but was elevated to more than 60 mm/h in 70% of patients in a series[19]. Other non-specific findings may include slightly abnormal liver function tests and high levels of lactate dehydrogenase[20].

Antinuclear antibodies (ANA), rheumatoid factor, lupus erythematosus and preparations are negative. Some patients initially diagnosed with Kikuchi disease presented later systemic lupus erythematosus (SLE)[8,23]. The FAN should be performed in patients with suspicion of Kikuchi disease that have features suggestive of LES to delete such a diagnosis. A study describes transient elevation anti-DNA antibody levels of protein anti-ribonuclear[9].

Diagnosis

Lymph node biopsy makes diagnosis of the disease of Kikuchi-Fujimoto. The biopsy should be performed, despite the self-limiting nature of this syndrome to rule out more serious conditions that require aggressive therapy such as lymphoma. Kikuchi disease patients were diagnosed as having lymphoma treated with cytotoxic agents when doctors and pathologists still did not know in detail this entity[8]. Other pathologies that were confused with Kikuchi disease tuberculous adenitis, venereum lymphogranuloma and Kawasaki disease[24-26].

Though excisional biopsy is often recommended because it often breaks up a framework of lymphoma, the fine needle aspiration is increasingly useful in the hands of the experienced pathologist, using colours and cell block preparations, allowing diagnosis[27,28].

Pathology

The histology of the lymph node in Kikuchi-Fujimoto disease can easily be differentiated from more well-known infectious conditions in the differential diagnosis of fever and Lymphadenopathy [8-11],[29]. Yellow necrotic foci can hardly be noticed in the cutting surface of the nodule. Microscopic examination usually shows outbreaks paracortical with necrosis and cellular infiltrate histiocytic. These outbreaks can be single or multiple. The capsule can be infiltrated, and perinodal inflammation is common. The necrotizing process is often confined to circumscribed areas

of fibrinoid Eosinophilic material with an irregular distribution of fragments of rubble nuclear[11].

The histological appearance changes as the disease progress. Early biopsies on "proliferative phase" show follicular hyperplasia and paracortical expansion by T cells, B cells and monocytes and miscellaneous plasmacytoid histiocytes with numerous deep down apoptosis[30].

In "the proliferative phase," the presence of several blastic cells raises the differential diagnosis of lymphoma, infection with Epstein-Barr virus (EBV), and herpes simplex infection. The preservation of nodal architecture, the mole, and polyclonal immunohistochemistry negative viral conditions exclude[30].

Subsequent biopsies on "Necrotizing phase" have shown without a neutrophilic infiltrate necrosis associated with the domain of histiocytes. The histiocytes often have nuclei in growing and contain dendrites phagocytosed. Immunohistochemical staining shows positive monocytes plasmacytoid and CD68 histiocytes with predominantly CD8 positive T lymphocytes[30]. The absence of neutrophils in "Necrotizing phase" is useful to distinguish this condition from LES and drug-induced lymphadenopathy.

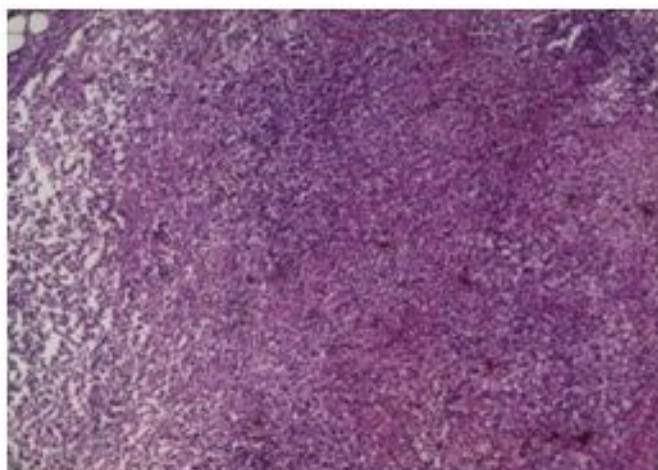


Figure 1: Axillary lymph node blade, representing necrotizing lymphadenitis with nuclear fragmentation and reactive hyperplasia - Image with a magnification of 100x.

Differential diagnosis

The differential diagnosis of the histological point of view includes LES, herpes simplex and lymphoma (non-Hodgkin's lymphoma and Hodgkin's Lymphoma). In the LES, bodies of hematoxylin and plasma cells are also seen. In herpes simplex, there are fewer surrounding mononuclear cells and neutrophils are commonly present. In contrast to the Kikuchi disease, necrosis associated with Hodgkin's lymphoma usually includes neutrophils and large atypical cells (cell variants of Reed-Sternberg cells), positive for CD30, CD15, CD45. It is suggested that the plasmacytoid dendritic cells infiltrate in lymph nodes with higher frequency in Kikuchi-Fujimoto disease when compared to any other reactive lymphadenitis or B or T cell lymphoma, regardless of the size of the lesion. Thus, the predominance of plasmacytoid dendritic cells can be a useful indicator in the diagnosis of hepatological disease of Kikuchi[31].

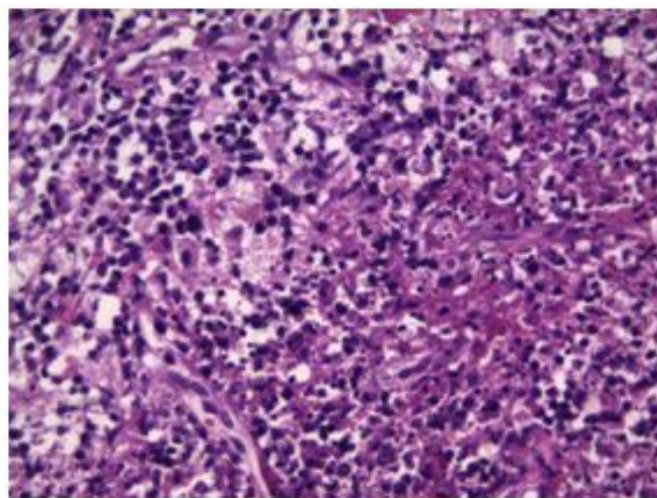


Figure 2: Axillary lymph node blade, representing necrotizing lymphadenitis with nuclear fragmentation - Image with a magnification of 400x.

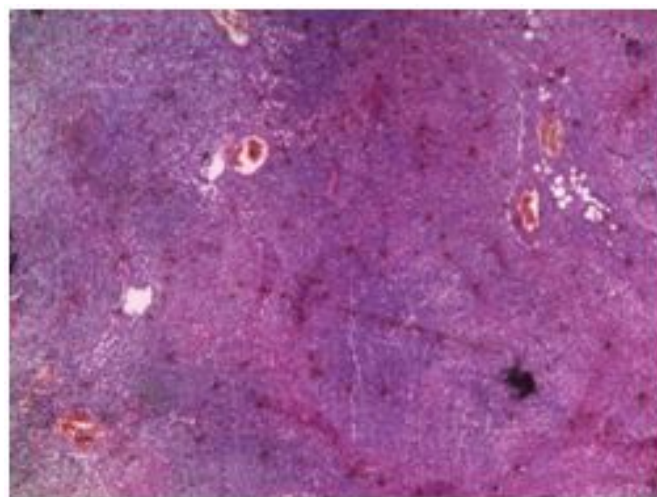


Figure 3: Axillary lymph node blade, representing necrotizing lymphadenitis with nuclear fragmentation and reactive hyperplasia - Image with a magnification of 50x.

Radiology

Computed tomography (CT) of the affected lymph nodes typically demonstrates perinodal infiltration (81%) and homogeneous enhancement (83%)[32]. On ultrasound, the lymph nodes can present radiological features of malignancy[33].

Treatment

No effective treatment for the disease has been established of Kikuchi-Fujimoto to the present. The signs and symptoms usually disappear within one to four months. Patients with severe or persistent symptoms are treated with high-dose glucocorticoids associated with intravenous immunoglobulin, or not showing results apparently promising[34,35]. There have been reports of success in the treatment of recurrent disease of Kikuchi-Fujimoto with hydroxychloroquine[36]. Affected patients should be followed for a few years because they may be affected of LES and relapses of the disease of Kikuchi-Fujimoto are applicants for several years, after the first episode of disease[22-26].

Conclusion

Excisional biopsy of supraclavicular lymph node showed Kikuchi-Fujimoto disease on microscopic examination. After histopathological confirmation, were other causes of febrile adenomegalias apart, starting dose corticosteroid immunosuppressive therapy.

Competing Interests

Written informed consent obtained from the patient for publication of this case report and any accompanying images.

References

1. Yen A, Fearneyhough P, Raimer SS, Hudnall SD. EBV-associated Kikuchi's histiocytic necrotizing lymphadenitis with cutaneous manifestations. *J Am Acad Dermatol* 1997; 36:342.
2. Hudnall SD, Chen T, Amr S, et al. Detection of human herpesvirus DNA in Kikuchi-Fujimoto disease and reactive lymphoid hyperplasia. *Int J Clin Exp Pathol* 2008; 1:362.
3. Huh J, Kang GH, Gong G, et al. Kaposi's sarcoma-associated herpesvirus in Kikuchi's disease. *Hum Pathol* 1998; 29:1091.
4. Yufu Y, Matsumoto M, Miyamura T, et al. Parvovirus B19-associated haemophagocytic syndrome with lymphadenopathy resembling histiocytic necrotizing lymphadenitis (Kikuchi's disease). *Br J Haematol* 1997; 96:868.
5. Iguchi H, Sunami K, Yamane H, et al. Apoptotic cell death in Kikuchi's disease: a TEM study. *Acta Otolaryngol Suppl* 1998; 538:250.
6. Ohshima K, Shimazaki K, Kume T, et al. Perforin and Fas pathways of cytotoxic T-cells in histiocytic necrotizing lymphadenitis. *Histopathology* 1998; 33:471.
7. Ura H, Yamada N, Torii H, et al. Histiocytic necrotizing lymphadenitis (Kikuchi's disease): the necrotic appearance of the lymph node cells is caused by apoptosis. *J Dermatol* 1999; 26:385.
8. Dorfman RF, Berry GJ. Kikuchi's histiocytic necrotizing lymphadenitis: an analysis of 108 cases with emphasis on differential diagnosis. *Semin Diagn Pathol* 1988; 5:329.
9. Asano S, Akaike Y, Jinnouchi H, et al. Necrotizing lymphadenitis: a review of clinicopathological, immunohistochemical and ultrastructural studies. *Hematol Oncol* 1990; 8:251.
10. Lin HC, Su CY, Huang CC, et al. Kikuchi's disease: a review and analysis of 61 cases. *Otolaryngol Head Neck Surg* 2003; 128:650.
11. Tsang WY, Chan JK, Ng CS. Kikuchi's lymphadenitis. A morphologic analysis of 75 cases with particular reference to unusual features. *Am J Surg Pathol* 1994; 18:219.
12. Lee KY, Yeon YH, Lee BC. Kikuchi-Fujimoto disease with prolonged fever in children. *Pediatrics* 2004; 114:e752.
13. Payne JH, Evans M, Gerrard MP. Kikuchi-Fujimoto disease: a rare but important cause of lymphadenopathy. *Acta Paediatr* 2003; 92:261.
14. Ray A, Muse VV, Boyer DF. Case records of the Massachusetts General Hospital. Case 38-2013. A 30-year-old man with fever and lymphadenopathy. *N Engl J Med* 2013; 369:2333.
15. Infante MJ, Lovillo C, Santaella IO, Checa RM, González MR. Enfermedad de Kikuchi-Fujimoto como causa de linfadenopatías. *An Pediatr (Barc)*. 2007;67(1):83-5.
16. Kucukardali Y, Solmazgul E, Kunter E, et al. Kikuchi-Fujimoto Disease: analysis of 244 cases. *Clin Rheumatol* 2007; 26:50.
17. Kuo TT. Cutaneous manifestation of Kikuchi's histiocytic necrotizing lymphadenitis. *Am J Surg Pathol* 1990; 14:872.
18. Kuo TT. Kikuchi's disease (histiocytic necrotizing lymphadenitis). A clinicopathologic study of 79 cases with an analysis of histologic subtypes, immunohistology, and DNA ploidy. *Am J Surg Pathol* 1995; 19:798.
19. Norris AH, Krasinskas AM, Salhany KE, Gluckman SJ. Kikuchi-Fujimoto disease: a benign cause of fever and lymphadenopathy. *Am J Med* 1996; 101:401.
20. Bailey EM, Klein NC, Cunha BA. Kikuchi's disease with liver dysfunction presenting as fever of unknown origin. *Lancet* 1989; 2:986.
21. Song JY, Cheong HJ, Kee SY, et al. Disease spectrum of cervical lymphadenitis: analysis based on ultrasound-guided core-needle gun biopsy. *J Infect* 2007; 55:310.
22. Smith KG, Becker GJ, Busmanis I. Recurrent Kikuchi's disease. *Lancet* 1992; 340:124.
23. Patra A, Bhattacharya SK. SLE Developing in a Follow-Up Patient of Kikuchi's Disease: A Rare Disorder. *J Clin Diagn Res* 2013; 7:752.
24. Mital D, Desai V, Chin K. Kikuchi-Fujimoto syndrome presenting to a sexual health clinic. *Int J STD AIDS* 2009; 20:140.
25. Dorfman RF, Warnke R. Lymphadenopathy simulating the malignant lymphomas. *Hum Pathol* 1974; 5:519.
26. Nieman RB. Diagnosis of Kikuchi's disease. *Lancet* 1990; 335:295.
27. Tsang WY, Chan JK. Fine-needle aspiration cytologic diagnosis of Kikuchi's lymphadenitis. A report of 27 cases. *Am J Clin Pathol* 1994; 102:454.
28. Mannarà GM, Boccato P, Rinaldo A, et al. Histiocytic necrotizing lymphadenitis (Kikuchi-Fujimoto disease) diagnosed by fine needle aspiration biopsy. *ORL J Otorhinolaryngol Relat Spec* 1999; 61:367.
29. Atwater AR, Longley BJ, Aughenbaugh WD. Kikuchi's disease: case report and systematic review of cutaneous and histopathologic presentations. *J Am Acad Dermatol* 2008; 59:130.

30. Ohshima K, Karube K, Hamasaki M, et al. Apoptosis- and cell cycle-associated gene expression profiling of histiocytic necrotising lymphadenitis. *Eur J Haematol* 2004; 72:322.
31. Kishimoto K, Tate G, Kitamura T, et al. Cytologic features and frequency of plasmacytoid dendritic cells in the lymph nodes of patients with histiocytic necrotizing lymphadenitis (Kikuchi-Fujimoto disease). *Diagn Cytopathol* 2010; 38:521.
32. Kwon SY, Kim TK, Kim YS, et al. CT findings in Kikuchi disease: analysis of 96 cases. *AJNR Am J Neuroradiol* 2004; 25:1099.
33. Youk JH, Kim EK, Ko KH, Kim MJ. Sonographic features of axillary lymphadenopathy caused by Kikuchi disease. *J Ultrasound Med* 2008; 27:847.
34. Jang YJ, Park KH, Seok HJ. Management of Kikuchi's disease using glucocorticoid. *J Laryngol Otol* 2000; 114:709.
35. Lin DY, Villegas MS, Tan PL, et al. Severe Kikuchi's disease responsive to immune modulation. *Singapore Med J* 2010; 51:e18.
36. Rezai K, Kuchipudi S, Chundi V, et al. Kikuchi-Fujimoto disease: hydroxychloroquine as a treatment. *Clin Infect Dis* 2004; 39:e124.