CANINE ASSAULT WITH BLUNT TRAUMA TO THE CHEST CAUSING ACUTE ISCHEMIC STROKE

Karen Greenberg[*,1], **Hirad Hedayat**[*], **Brandon Blakey**[**], **Shamira Munn**[**] **and Christina Canzanese**[**]
[*]Drexel Neurosciences Institute, Drexel University College of Medicine, 219 North Broad St 7th Floor, Philadelphia, PA 19102, USA., [**]Crozer Chester Medical Center, One Medical Center Boulevard, Upland, PA 19103.

ABSTRACT Ischemic stroke occurs in a significant subset of patients with blunt traumatic cerebrovascular injury (TCVI). The patients are most often victims of motor vehicle crashes or assaults and suffer an ischemic stroke due to injury of the extracranial carotid or vertebral arteries. A 60-year-old male described walking in a park when a large dog jumped up, striking him in the chest and causing forceful rotation of the neck, but no head injury was reported. Immediately after the incident, the patient complained of dizziness, clumsiness of the left arm, and difficulty seeing to the left. Computed tomography angiography of the neck demonstrated 50% stenosis of the proximal right internal carotid artery secondary to a mural thrombus. Before the event, the patient had no known history of carotid disease. Magnetic resonance imaging of the brain showed numerous subcentimeter foci of acute ischemia in the right cerebral hemisphere within the right middle and posterior cerebral artery distributions. Most literature about TCVI and stroke has been published in trauma, general surgery, and neurosurgery journals because these patients are generally primarily managed by trauma surgeons. Because of the increasing prevalence and awareness of TCVI, it is essential to bring this clinical entity to the attention of all medical providers.

KEYWORDS Traumatic Cerebrovascular Injury, Ischemic stroke, trauma, stroke, carotid thrombus

Introduction

Ischemic stroke occurs in a significant subset of patients with blunt traumatic cerebrovascular injury (TCVI). Extracranial TCVI is present in approximately 1-2% of patients admitted after blunt trauma. The patients are most often victims of motor vehicle crashes or assaults and suffer an ischemic stroke due to injury to the cervical carotid or vertebral arteries [1]. We describe a unique case of blunt trauma to the chest resulting in acute ischemic stroke from mural thrombus of the right internal carotid artery.

DOI:10.5455/IJMRCR.Canine-Assault-Blunt-Trauma-Chest
First Received: February 13, 2020
Accepted: March 03, 2020
Manuscript Associate Editor: Ivan Inkov (BG)

[1]Drexel Neurosciences Institute, Drexel University College of Medicine, 219 North Broad St 7th Floor, Philadelphia, PA 19102, USA.; Email:kjgreenb@gmail.com

Case report

A 60-year-old male with a history of hypertension, diabetes, and hyperlipidemia arrived with Emergency Medical Services (EMS) with complaints of dizziness, clumsiness of the left arm, and difficulty seeing to the left. These symptoms started immediately after the patient was struck in the chest by a large dog in the dog park which caused forceful rotation of the neck, but no impact to the head. EMS reported that the incident occurred 60 minutes before arrival in the Emergency Department (ED).

Initial vital signs obtained were temperature 98.0 orally, heart rate 83, blood pressure 160/97, respiratory rate 18, and pulse oximetry 99% room air. Patient's weight 104 kg and blood glucose 183. Neurological examination showed the patient to be awake, alert and oriented to person, place, and time. Pupils were equal and reactive with normal gaze, but positive field cut to bilateral left upper outer quadrants. He also noted decreased sensation to the left arm and abnormal finger to nose testing of the left upper extremity. National Institute of Health Stroke Scale (NIHSS) was calculated as 3.

Pertinent lab findings were as follows: hemoglobin 15.1 g/dL, platelets 159 K/uL, PT 13.1 s, INR 1.0, PTT 24 s, glucose 203

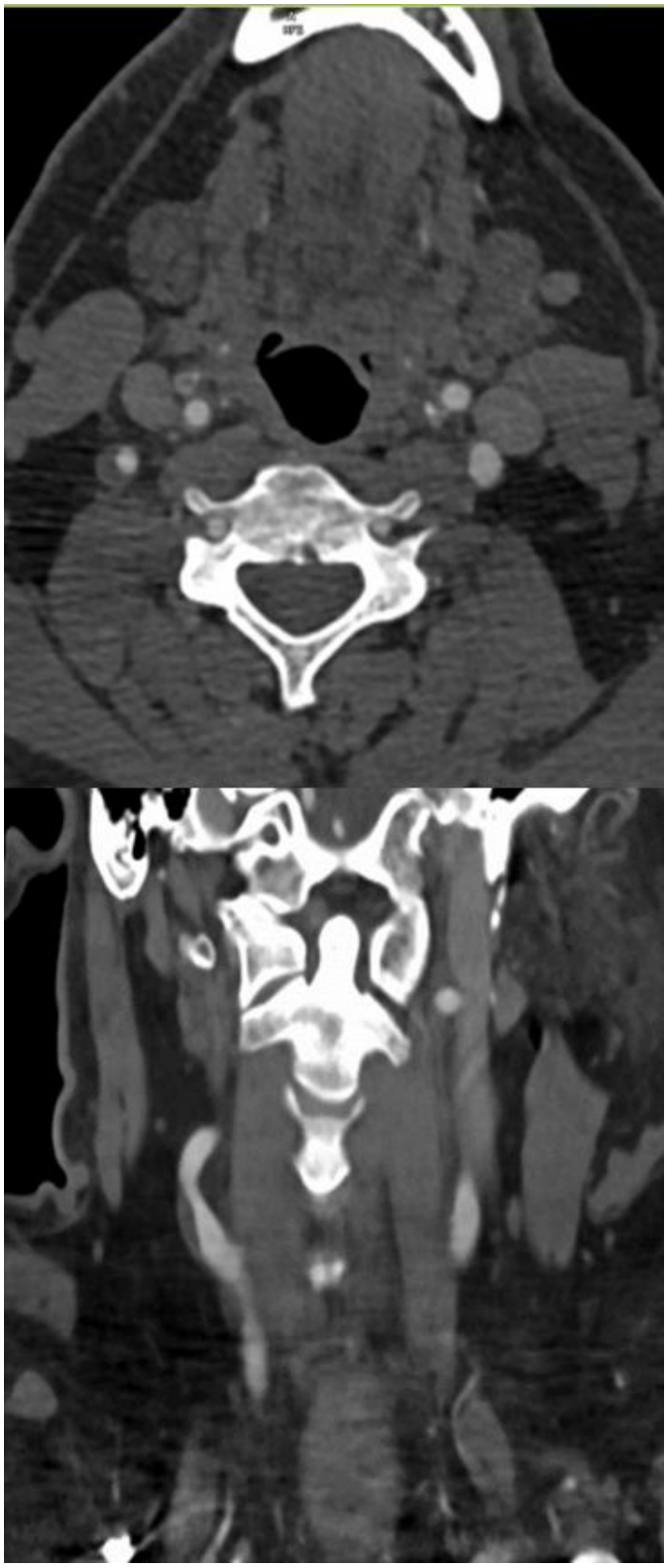

Figure 1: Axial CTA of the neck demonstrating right internal carotid artery stenosis of 50%.Coronal reconstruction CTA of the neck demonstrating right internal carotid artery stenosis of 50%.

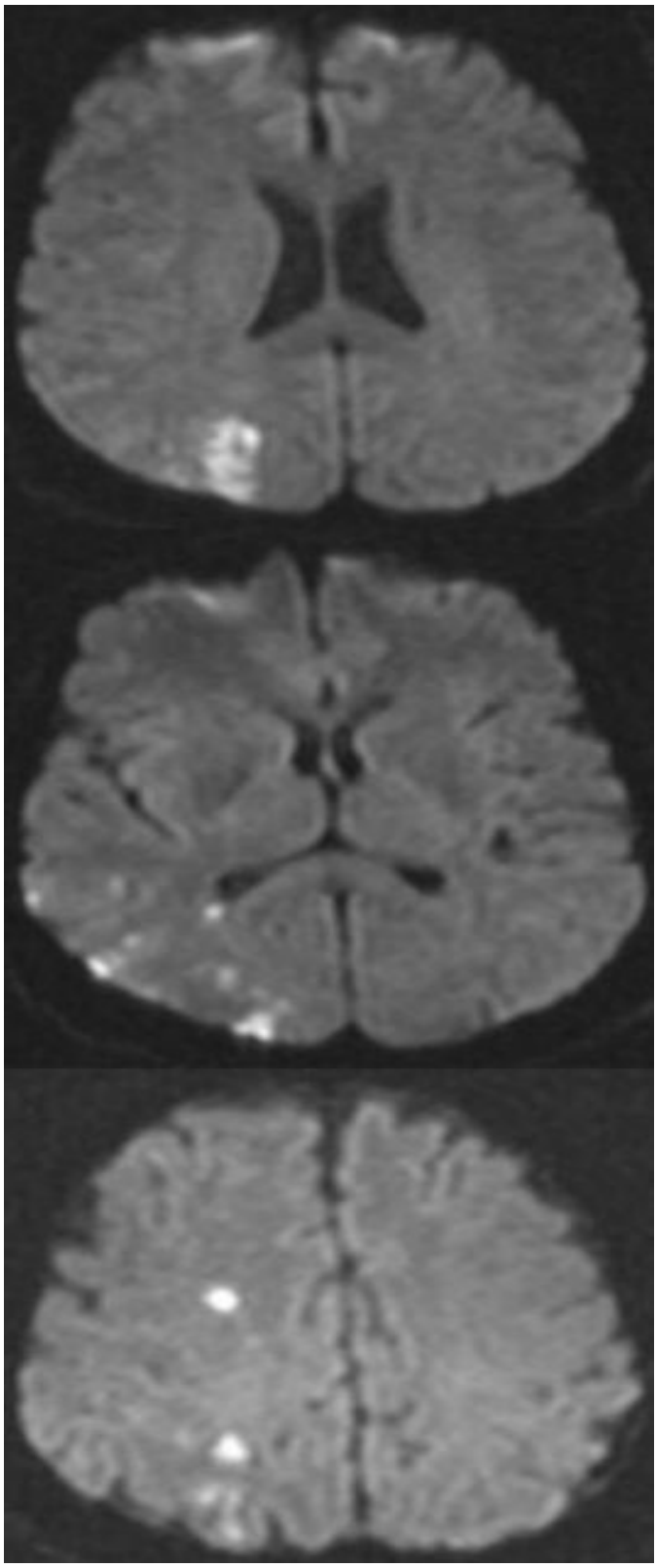

Figure 2: Diffusion-Weighted Image (DWI) axial sections are demonstrating restriction of diffusion in the posterior circulation as well as the MCA watershed territory.

mg/dL, creatinine 0.9 mg/dL, and no alcohol detected. Non-contrast head computed tomography (CT) showed no evidence of intracranial haemorrhage with some periventricular white matter microangiopathic changes. CT angiography of the head revealed patent vasculature while CT angiography of the neck demonstrated 50% stenosis of the proximal right internal carotid artery secondary to a mural thrombus. Before the event, the patient had no known history of carotid disease.

The patient had no apparent traumatic injuries and no contraindications to receive IV alteplase. After shared decision making with the ED team, the patient gave his consent to receive the fibrinolytic. The patient had improvement in his sensation to the left arm, but his visual field deficit and ataxia persisted. NIHSS was two upon transfer to the Neuroscience Intensive Care Unit. Magnetic Resonance Imaging (MRI) of the brain showed numerous subcentimeter foci of acute ischemia in the right cerebral hemisphere within the right middle cerebral and posterior cerebral distributions. The patient's paresthesias to his left arm resolved as well as his dysmetria. He still had a mild left field cut but was able to be discharged to home three days later with an NIHSS of 1. Given the concern for carotid etiology along with embolic phenomena shortly after the moment of impact, the patient was placed on dual antiplatelet therapy with aspirin and clopidogrel daily prior to discharge.

Discussion

An increasing number of patients with TCVI are being identified largely because of the expanding use of CT angiography for screening patients with blunt trauma. Most literature about TCVI and stroke has been published in the trauma, general surgery, and neurosurgery literature because these patients are generally primarily managed by trauma surgeons [1]. Because of the increasing prevalence and awareness of TCVI, it is essential to bring this clinical entity to the attention of other medical providers as well.

Extracranial TCVI is present in approximately 1-2% of patients admitted after blunt trauma. Based on studies reporting that 10-20% of patients with TCVI have a stroke, TCVI may be responsible for up to 9600 ischemic strokes in the United States per year [2,3]. TCVI would, therefore, account for about 1.2% of total strokes that occur annually in the United States [4]. Motor vehicle crashes are the most common cause of TCVI, followed by assaults, falls, and hanging [1].

TCVI is markedly different from spontaneous dissections or dissections occurring after low-energy trauma. Specifically, most trauma patients experience a hypercoagulable state soon after injury. Spontaneous cervical arterial dissections tend to primarily affect the outer arterial wall, whereas with TCVI intimal disruptions are more common [1]. The most common cause of ischemic stroke due to TCVI is thromboembolism. In one report of blunt trauma patients in two-level I trauma centers, 82% of patients with TCVI-related stroke had the stroke within 2 hours of injury [5].

According to literature data, there are no distinct guidelines regarding the proper diagnostic and therapeutic management of traumatic carotid artery dissection. Although most of the cases evaluated in research studies refer to spontaneous carotid artery dissection, traumatic cases demand special considerations as far as diagnosis and treatment are concerned. Patients with TCVI can present with several other concomitant injuries, as well as a higher bleeding risk, thus complicating decision making in such patients [6].

Regarding proper medical treatment for spontaneous carotid artery dissection, anticoagulation or antiplatelets should be initiated promptly to prevent further thromboembolic events. Both types of agents show similar efficacy in reducing neurological sequelae without increasing the risk of stroke. However, cases of traumatic causes demand a more interdisciplinary approach and show specific considerations concerning treatment [6].

When other concomitant injuries with a high risk for severe bleeding are present, then the optimal type and time of treatment should be considered in an interdisciplinary approach including consultation by a trauma surgeon, orthopaedic surgeon, neurosurgeon, vascular surgeon, radiologist, and/or neurologist. Medical treatment should be initiated as soon as possible, including the use of thrombolytics when indicated. Concerning the role of thrombolysis in TCVI, data are limited in the literature given the high bleeding risk in trauma patients [6].

The safety and efficacy of thrombolysis in even spontaneous cervical artery dissection (CAD) are controversial. One pooled analysis reviewed 180 patients, of which 67% received intravenous thrombolysis, and 33% received intra-arterial thrombolysis. The pooled symptomatic intracranial haemorrhage rate was 3.1%, the overall mortality rate was 8.1%, and 41% had an excellent outcome. Therefore, safety and outcome of thrombolysis in patients with cervical artery dissection stroke appears similar to those for stroke from all causes. This particular analysis concluded that thrombolysis should not be withheld after shared decision making with the patient and the medical team [7].For trauma patients as with all medical decision making, the risk versus benefit must always be weighed.

Conclusion

This case report discusses a 60-year-old male with known risk factors for ischemic stroke and thrombus of the right internal carotid artery that seems to have caused a thromboembolic event after a blunt traumatic episode to the chest leading to the watershed middle cerebral artery infarcts and posterior circulation territory infarcts of the right hemisphere. Medical providers need to have heightened awareness of this growing entity of TCVI as it would be elementary to think of the injury and stroke as unrelated initially. With CT angiography of the neck becoming more standard in the evaluation of trauma patients, cervical artery dissections are being reported more than ever before (8). This case report emphasizes that TCVI is an increasing diagnosis for medical providers and staff to be aware of and treat accordingly for best patient outcomes.

Disclosure Statement

There were no financial support or relationships between the authors and any organization or professional bodies that could pose conflict of interests.

Competing Interests

Written informed consent has been obtained from the patient for publication of this case report and any accompanying images.

References

1. Foreman PM, Harrigan MR: Blunt Traumatic Extracranial Cerebrovascular Injury and Ischemic Stroke. Cerebrovasc Dis Extra 2017;7:72-83

2. Franz, RW, Willette PA, Wood MJ, Wright ML, Hartman JF: A systematic review and meta-analysis of diagnostic screening criteria for blunt cerebrovascular injuries. J Am Coll Surg 2012;214: 313-327.

3. Stein DM, Boswell S, Sliker CW, Lui FY, Scalea: Blunt cerebrovascular images: does treatment always matter? J Trauma 2009;66: 132-143.

4. https://www.cdc.gov/stroke/facts.htm

5. Mayberry JC, Brown CV, Mullins RJ, Velmahos GC: Blunt carotid artery injury: the futility of aggressive screening and diagnosis. Arch Surg 2004;139: 609-612.

6. Galyfos, G, Filis, K, Sigala F, Sianou A: Traumatic Carotid Artery Dissection: A Different Entity Without Specific Guidelines. Vasc Specialist Int 2016; 32(1): 1-5.

7. Zinkstok, SM, Vergouwen MD, Engelter ST, et al.: Safety ad Functional Outcomes of Thromolysis in Dissection-Related Ischemic Stroke: a Meta-Analysis of Individual Patient Data. Stroke 2011: 42(9): 2515-20.

8. Schicho A, Luerken L, Meier R, Ernstberger A, et al.: Incidence of traumatic carotid and vertebral artery dissections: results of cervical vessel computed tomography angiogram as a mandatory scan component in severely injured patients. Therapeutics and Clinical Risk Management 2018(14): 173—178.