MANAGEMENT OF A MULTICYSTIC AMELOBLASTOMA: ABOUT A CONSERVATIVE AND MULTIDISCIPLINARY APPROACH

Salma Adnane [1,a], **Sofia Haitami** [b] **and Ihsane Ben Yahya** [c]

[a] Resident Dentist, Department of Oral Surgery, Dental Consultation and Treatment Center, Ibn Rochd University Hospital Center, Casablanca, Morocco , [b] Professor, Department of Oral Surgery, Dental Consultation and Treatment Center , Ibn Rochd University Hospital Center , Casablanca, Morocco , [c] Professor and Head of the Oral Surgery Unit, Dental Consultation and Treatment Center, Ibn Rochd University Hospital Center, Casablanca, Morocco

ABSTRACT Ameloblastoma is a benign odontogenic tumour of epithelial origin. It represents 1% of all tumours and cysts of the jaws. It is located in the mandible in 80% of cases and in the maxilla in 20% of cases. The WHO, in its classification of odontogenic tumours in 2017, divides ameloblastoma into 3 groups: unicystic ameloblastoma, peripheral ameloblastoma and conventional (or multicystic) ameloblastoma. The histological types of the latter include the follicular and the plexiform. The surgical management of these tumours represents a real challenge for the surgeon, who wants to be as conservative as possible. The treatment of ameloblastoma is surgical; enucleation, curettage or interruptive resection are applicable depending on the size and the type of lesion. The objective of this article is to report the diagnostic and therapeutic attitude toward mandibular plexiform ameloblastoma in a young 29-years-old patient treated in the oral surgery department of the dental consultation and treatment centre of Casablanca.

KEYWORDS Ameloblastoma, enucleation, dental implants, prosthetic rehabilitation, conservative approach

Introduction

The ameloblastoma is a benign odontogenic tumour of epithelial origin. However, it exhibits aggressive behaviour with a local invasive and evolutionary potential and a high level of recurrence.

It represents 1% of maxillary and 11% of odontogenic tumours[1].

Most ameloblastomas (up to 80%) are located in the mandible, usually in the posterior part of the horizontal branch. Only 20% are arising in the maxilla. They may occur at any age, but usually between the third and fifth decade and has an equal gender distribution[2].

In 2017, World Health Organization (WHO) divided ameloblastomas into 3 types: conventional (multicystic), unicystic and peripheral. Conventional ameloblastoma is the most common form, representing 85% of all ameloblastomas. Histologically it can be divided into follicular, plexiform, and other less common histological variants[3].

Clinically, the symptoms are non-specific, usually manifesting as swelling. Radiographically, these lesions appear as unilocular or multilocular radiolucencies with a soap-bubble or honeycombed appearance. The diagnosis is confirmed histologically.

The aim of this article is to report the case of plexiform ameloblastoma diagnosed in a young patient 29 years old who underwent surgical enucleation followed by dental implant placement in the Oral Surgery Department of the dental consultation and treatment centre of Casablanca and to underline the importance of the conservative approach in managing ameloblastomas.

Case Report

We report the case of a 29-years-old woman, received in the consultation of the Oral Surgery Department of the Dental Consultation and Treatment Center of Casablanca, complaining of oral swelling on the left side of the mandible evolving for 3 months. The patient was a non-smoker and had no underlying disease.

DOI: 10.5455/IJMRCR.172-1652908594
First Received: May 18, 2022
Accepted: August 20, 2022
Associate Editor: Ivan Inkov (BG);
[1]Corresponding author: Salma Adnane. sallyad993@gmail.com

The extraoral examination was unremarkable. The intraoral examination revealed a raised mass in the left mandibular lingual area, painless, non-tender, and covered with normal mucosa, extending from the lower first premolar (34) to the lower second molar (37). The 35 and 36 were mobile. [Figure 1]

A panoramic X-Ray revealed a well-circumscribed, multilocular radiolucency extending from the 33 to the mesial root of the 37. The 34, 35 and 36 were encased in the lesion with slight root resorption. [Figure 2]

Figure 1 Intraoral examination showing a lingual swelling.

Figure 2 Preoperative panoramic X-Ray showing a well-circumscribed, multilocular radiolucency extending from the 33 to the the mesial root of the 37.

A preoperative CT scan was carried out to show the true extent of the lesion and the relation with anatomic elements. The scan revealed an extensive hemi-mandibular lesion causing a rupture of both external and internal cortical layers. [Figure 3]

Surgical treatment was performed under local anaesthesia. It consisted of enucleation of the entire lesion with the extraction of premolars and the first molar. [Figure 4]

Antibiotics, analgesics and anti-inflammatory drugs were given to the patient postoperatively. The histological diagnosis was reported as plexiform ameloblastoma.

The patient has been kept under periodic follow-up since then.

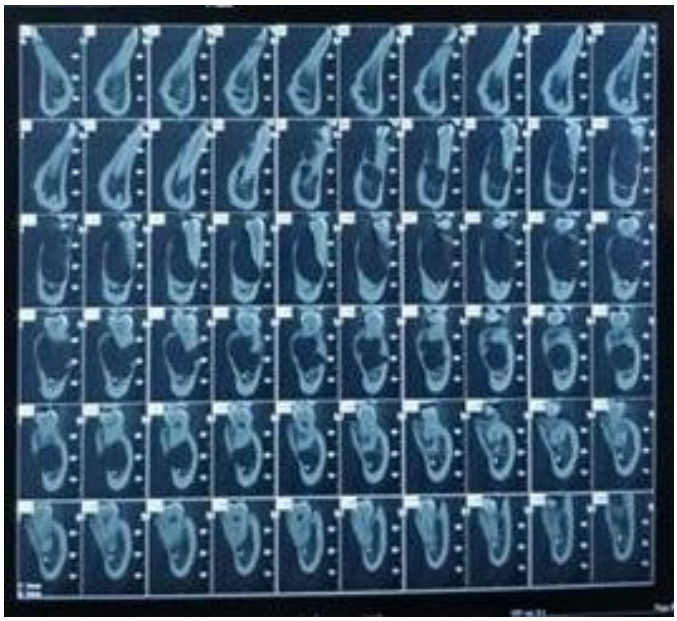

Figure 3 Preoperative CT scan showing an extensive hemi-mandibular lesion causing a rupture of both external and internal cortical layers.

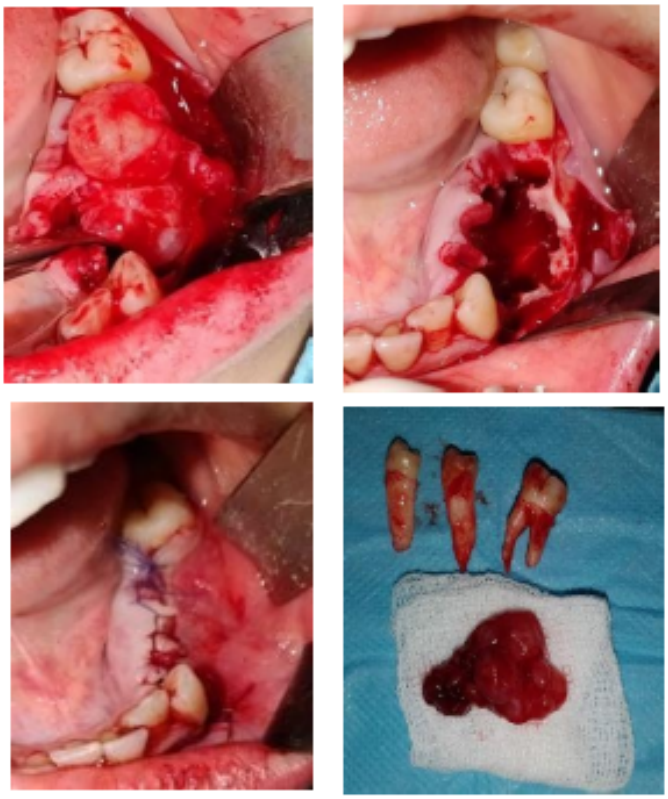

Figure 4 Intraoperative photographs.

After approximately 18 months of regular clinical and radiographic follow-up, no recurrence has been observed, and satisfactory bone healing was achieved.[Figure 5, 6]

Thus, dental rehabilitation was planned. Three dental implants were placed, replacing 34, 35 and 36. The prosthetic phase

Figure 5 6 months postoperative panoramic radiograph.

Figure 6 1 year postoperative panoramic radiograph.

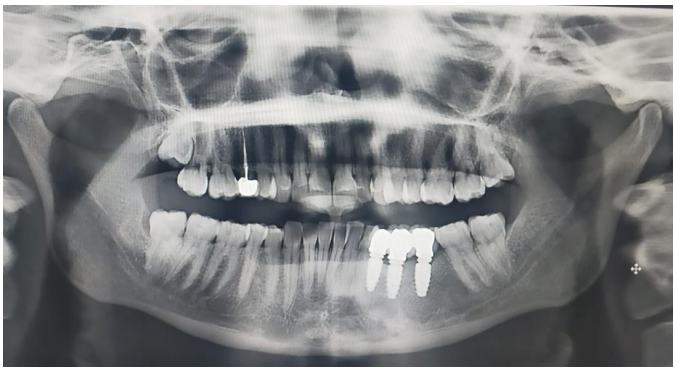

Figure 7 2 years postoperative panoramic radiograph showing a good osseointegration of the dental implants.

of restoration was initiated after 6 months of clinical and radiographic assessment of osseointegration. The implants were fitted with permanent crowns to restore the masticatory function of the patient.[Figure 7]

After 1 year follow-up, there was no sign of local recurrence.

Discussion

Ameloblastoma is an odontogenic tumour that grows slowly but is locally invasive and infiltrating. It represents 1% of all tumours and cysts that involve the maxillo-mandibular area and about 11% of odontogenic tumours.[4]

80% of ameloblastomas occur in the mandible, usually in the posterior part of the horizontal branch.

The etiopathogenesis is still poorly understood but has been linked to the enamel organ, remnants of odontogenic epithelium and faulty regulation of the genes involved in tooth development, which may also explain the potential for malignant transformation as metastasis. [5]

Several other causative factors have been proposed, including trauma, inflammation, nutritional deficiencies, non-specific irritation from extractions, and dental caries.[6]

Ameloblastoma is most commonly found in young adults, reaching around 35. It has no predominance in terms of gender or race.[7]

Clinically, the symptoms are non-specific. They include painless swelling that may cause severe facial deformity, teeth loss, ulcers or periodontal problems. Our patient complained of oral swelling on the left side of the mandible.

Radiographically, the lesions appear as unilocular or multilocular radiolucencies with a soap-bubble or honeycombed appearance. In some cases, ameloblastomas appear as a circumscribed radiolucency surrounding the crown of an unerupted tooth, mimicking a dentigerous cyst.

Diagnosis is confirmed through the radiographic appearance of the lesion, its clinical behaviour, and histopathology.

In the case reported in this article, the patient was a woman and was in her 3rd decade. Clinically, she presented a swelling in the left mandibular lingual area, gradually increasing in size. Histopathological features revealed plexiform ameloblastoma.

The World Health Organization (WHO), in its latest classification of odontogenic tumours in 2017, divided ameloblastomas into 3 groups: unicystic ameloblastoma (13% of cases), peripheral ameloblastoma (1% of cases) and conventional (or multicystic) ameloblastoma (86% of cases). The main histological types of the latter include the follicular and the plexiform.[8]

This article will focus on the classic findings of multicystic ameloblastoma, especially the plexiform variant and will underline the importance of a conservative and multidisciplinary the approach to managing ameloblastomas to maintain our patient's quality of life.

The most common form of ameloblastomas is the solid/multicystic/conventional type, making up about 86% of all cases. It is slow growing but can infiltrate adjacent structures, recur, and even metastasize.

Histologically, it can be divided into 2 main patterns: the follicular and the plexiform type. In addition, other microscopic subtypes have been reported (cystic, granular, acanthomatous, spindle cell, basal cell. . .)

The term "plexiform" refers to the appearance of anastomosing islands of odontogenic epithelium in contrast to a follicular pattern. It is not uncommon for ameloblastoma to display both histological patterns.

The plexiform pattern is more aggressive and has a significantly high recurrence rate.

In a series of 78 cases, Nakamura et al. reported a higher recurrence rate for follicular (26.3%), plexiform (21.7%) and mixed (follicular and plexiform) (33.3%) ameloblastomas, regardless of the type of treatment. [9]

The average period to recurrence has been reported to be around 5 years. [10]

The appropriate management strategy for ameloblastoma remains controversial due to its locally invasive and aggressive nature and high recurrence rate. The treatment modalities are influenced by the age of the patient, the extension, duration, and position of the lesion, as well as the histopathological variants.[11]

In the case of solid and multicystic ameloblastoma, the treatment recommended by most authors is radical surgery with margins of 1 cm and resection of adjacent soft tissue.

However, radical techniques bring with them serious inconvenience to the patient, including masticatory dysfunction, change of mandibular movements, facial mutilation and deformity, as well as psychological sequelae that require a reconstruction procedure to restore the patient's quality of life.

Therefore, some authors propose combined conservative surgery, which consists of enucleation or curettage and long-term follow-up, as a possible alternative, especially when the patient has good patient compliance and a low risk of involvement of adjacent structures.[12] [13] [14]

A study by Nakamura in 2002 compared the long-term results of different approaches to 78 patients with ameloblastomas. It revealed that conservative treatments, including marsupialization and enucleation with or without Carnoy's solution, followed by sufficient bone curettage, were useful and reduced the need for jaw resection.[9]

Huang et al. conducted a study on 15 patients with ameloblastoma, concluding that good results can be obtained with conservative surgery and that a second surgery can succeed in recurrence. However, a long-term follow-up is necessary. [15]

Another study by Hresko in 2021 confirmed that the radical approach is associated with a significantly higher risk of post-surgical complications, a lower rate of prosthetic rehabilitation, and the necessity of multiple surgical interventions compared to the patients treated conservatively. [16]

These findings follow the results of Hendra in 2019, who suggests that the radical treatment strategy has severe consequences for patients and reduces their quality of life. Thus, it should be reserved for recurrent cases.

In developing countries where resources allocated to the health system are limited, these factors significantly impact decision-making: conservative methods are associated with a higher risk of recurrence but lower risks of other complications and fewer surgical interventions for esthetic and functional rehabilitation. Consequently, this strategy is getting better feedback from patients.[17]

In the Oral Surgery Department of Casablanca, our philosophy has always been to provide a treatment that is as minimally invasive as possible and to employ less aggressive methods when treating ameloblastomas after carefully considering the individual clinical, radiographic and histopathological variables of each case and establishing a long and intensive follow up program.

Hirschhorn recommended a 5 to 20-year follow-up period. [18]

The case reported in this article illustrated an interdisciplinary treatment approach provided by cooperation between oral surgeons and prosthodontists.

A staged approach was conducted. After the enucleation, our patient underwent implant placement after regular follow-up and review for almost 2 years. Prosthetic phase of restoration was initiated after 6 months of clinical and radiographic assessment of osseointegration.

The follow-up has revealed excellent stability of the dental implants and prosthetic restorations.

It was demonstrated that conservative therapy in a young patient not only preserves the bone structures in good condition but also saves the patient from psychological trauma and prevents or delays the need for aggressive surgery.

After two years of treatment, our patient had no evidence of tumour recurrence, completely reconstructed soft and hard tissues, restored function, and ultimately improved quality of life.

Conclusion

Managing ameloblastomas will probably remain controversial for a long time. The need to balance a conservative approach in the treatment with a low recurrence rate is a difficult goal to achieve.

Appropriate treatment should be individualized, considering clinical and radiological outcomes, histopathological variants, and the patient's age.

A long-term follow-up is recommended at least for the first 10 years, including periodic radiographic monitoring.

Conflict of Interest

The authors declare that they have no conflict of interest.

References

1. Celur S, Babu KS. Plexiform Ameloblastoma. Int J Clin Pediatr Dent 2012;5(1):78-83.

2. Gandhi N, Gandhi S, Kurian N. Implant-supported rehabilitation of unicystic ameloblastoma: A 2 years follow-upclinical report. CHRISMED J Health Res 2017;4:132-5.

3. Kashyap B, Reddy PS, Desai RS. Plexiform ameloblastoma mimicking a periapical lesion: a diagnostic dilemma. J Conserv Dent. 2012; 15:84–86.

4. Lee JH, Kim SH, Yoon HI, Yeo IS, Han JS. Implant assisted removable prosthetic rehabilitation after distraction osteogenesis in a patient with ameloblastoma recurrence: A case report. Medicine 2019;98:49

5. Sweeney RT, McClary AC, Myers BRet al(2014). Identification of recurrent SMO and BRAF mutations in ameloblastomas.Nat Genet46: 722–725.

6. O.A. Effiom, O.M. Ogundana, A.O. Akinshipo, S.O. Akintoye, Ameloblastoma: current etiopathological concepts and management, Oral Dis. 24 (2018)307–316.

7. T. Milman, G.S. Ying, W. Pan, V. LiVolsi, Ameloblastoma: 25, year experience at a single institution, Head and Neck Pathology 10 (2016) 513–520.

8. A.M.H. Cadavid, J.P. Araujo, C.M. Coutinho-Camillo, et al., Ameloblastomas:current aspects of the new WHO classification in an analysis of 136 cases,Surg. Exp. Pathol. 2 (2019) 17

9. Nakamura N, Higuchi Y, Mitsuyasu T, Sandra F, Ohishi M. Comparison of long-term results between different approaches to ameloblastoma. Oral Surg OralMed Oral Pathol Oral Radiol Endod 2002;93:13– 20.

10. Seintou A, Martinelli-Klay CP, Lombardi T: Unicystic ameloblastoma in children: A systematic review of clinicopathological features and treatment outcomes. Int J Oral Maxillofac Surg 43:405, 2014

11. A. Laborde, R. Nicot, T. Wójcik, J. Ferri, G. Raoul, Ameloblastoma of the jaws:management and recurrence rate, Eur. Ann. Otorhinolaryngol. Head Neck Dis.134 (2017) 7–11.

12. Hammarfjord O, Roslund J, Abrahamsson P, Nilsson P, Thor A, Magnusson M, et al. Surgical treatment of recurring ameloblastoma, are there options? Br J Oral Maxillofac Surg. 2013;51:762-6.

13. Dandriyal R, Gupta A, Pant S, Baweja HH. Surgical management of ameloblastoma: Conservative or radical approach. Natl J Maxillofac Surg. 2011;2:22-7.

14. Hasegawa T, Imai Y, Takeda D, Yasuoka D, Ri S, Shigeta T, et al. Retrospective study of ameloblastoma: the possibility of conservative treatment. Kobe J Med Sci. 2013;59:112-21.

15. Huang IY, Lai ST, Chen CH, Chen CM, Wu CW, Shen YH. Surgical management of ameloblastoma in children. Oral Surg Oral Med Oral Pathol Oral Radiol Endod. 2007;104:478-85.

16. Hresko A, Burtyn O, Pavlovskiy L, Snisarevskyi P, Lapshyna J, Chepurnyi Y, et al. Controversies in ameloblastoma management: evaluation of decision making, based on a retrospective analysis. Med Oral Patol Oral Cir Bucal. 2021 Mar 1;26 (2):e181-6.

17. Hendra FN, Natsir Kalla DS, Van Cann EM, de Vet HCW, Helder MN, Forouzanfar T. Radical vs conservative treatment of intraosseous ameloblastoma: Systematic review and meta-analysis. Oral Diseases. 2019;25:1683-96.

18. A.I. Hirschhorn, M. Vered, A. Buchner, G. Greenberg, R. Yahalom, Unicysticameloblastoma in an infant: a management dilemma, J. Craniomaxillofac.Surg. 41 (2013) e226–e230.