



ORIGINAL RESEARCH

Medicine Science 2019;8(1):93-6

The better choice for measuring the gonial angle of different skeletal malocclusion types: Orthopantomograms or lateral cephalograms?

Tugba Haliloglu Ozkan¹, Selim Arici¹, Enes Ozkan²

¹Ondokuz Mayıs University, Faculty of Dentistry, Department of Orthodontics, Samsun, Turkey

²Bafra Oral and Dental Health Hospital, Department of Oral and Maxillofacial Surgery, Samsun, Turkey

Received 21 June 2018; Accepted 26 August 2018

Available online 10.01.2019 with doi:10.5455/medscience.2018.07.8907

Copyright © 2019 by authors and Medicine Science Publishing Inc.

Abstract

The aim of this study was to highlight the current dilemma of gonial angle measurement on orthopantomograms and lateral cephalograms of adults with different skeletal malocclusion types. The sample consisted of 50 Class I, 50 Class II and 50 Class III (25 males and 25 females for each group) orthopantomograms and cephalograms obtained from previously treated orthodontic patients. For each malocclusion group, the angle between Tweed's mandibular plane and the tangent from the line running along the gonion to the distal point of the condyle was measured on the right and left sides on orthopantomograms and the superimposed images of the mandible on cephalograms. Paired t-test demonstrated no significant difference between the values of gonial angles determined by cephalograms and orthopantomograms in CI I patients. Pearson correlation also showed a high correlation between gonial angle values measured on the two diagnostic tools in CI I patients. In CI II and CI III patients, statistical analysis showed a significant difference between the gonial angles defined by cephalograms and orthopantomograms. Orthopantomograms can be used for determining gonial angle as accurately as cephalograms in CI I patients. However, orthopantomograms are not appropriate tools for measuring the gonial angle in CI II and CI III patients.

Keywords: Gonial angle, orthopantomogram, cephalogram

Introduction

Evaluation of growth pattern is of critical importance in orthodontic diagnosis and treatment planning. The gonial angle is a significant indicator to assess mandibular steepness and the growth pattern in patients; giving deserving information about vertical positions of the jaws and facial asymmetry. [1] It is a valuable marker while giving distinctive decision of orthodontic treatment or orthognatic surgery in an orthodontic patient. The downward and backward rotation of the mandible is called as a high angle in patients who showed increase of gonial angle. A low angle describes upward and forward rotation of mandible that appears decreased of gonial angle on patients. [2] The gonial angle is one of the determinative factor while specifying treatment approaches like extraction decision in CI II patients and surgery decision in CI III patients. [3]

The gonial angle can be measured on both orthopantomograms and cephalograms. Orthopantomogram is frequently used in orthodontic practice to provide important information about the teeth, their axial inclinations, maturation periods and surrounding tissues [4]; and also has relatively low radiation exposure. [5] Cephalograms can provide information about vertical, sagittal and transversal relations of the upper and lower jaws according to the skull base; the relationship between the upper and lower jaws, and the inclination of the teeth. However, the right and left sides can not be displayed separately in these x-rays, so it is insufficient to give definite information. [6] Although the gonial angle is usually measured from cephalograms, panoramic radiographs is being used gradually for jaw evaluation. [7] Some studies have shown that the left and right gonial angles can be separately measured by orthopantomogram which is a simple and repeatable radiographic method. [4] However, there is a lack of research in the literature examining orthopantomograms' ability of determining skeletal patterns. If proven, the accuracy of orthopantomograms to determine gonial angle would provide clinicians to evaluate growth pattern of a patient without the need for an extra x-ray; and also helps general dentists while directing the patients to specialists.

*Corresponding Author: Tugba Haliloglu Ozkan , Ondokuz Mayıs University, Faculty of Dentistry, Department of Orthodontics, Samsun, Turkey
E-mail: dtuuba@gmail.com

Therefore, the aim of this study was to compare the efficiency of orthopantomograms and cephalograms in the measurement of gonial angles for all skeletal malocclusion types.

Material and Methods

Patients

A total of 150 orthopantomograms and 150 cephalograms (50 CI I, 50 CI II, 50 CI III for each group) of patients referred to our orthodontic department were selected. The study was approved by the Institutional Ethical Committee of Ondokuz Mayıs University. Subjects with a craniofacial malformation or a facial asymmetry; or radiographs with technical or exposure faults were excluded from the study. All radiographs were obtained with the same digital machine (Sirona, XG 3, Munchen, Germany) at the Oral and Maxillofacial Radiology department of OMU Dental Faculty. The radiographs had to be taken by the same apparatus and same technician, and patients in natural head position. The skeletal pattern of the subjects were detected measuring SNA, SNB and ANB angles on the cephalograms in the sagittal plane; and then grouped with respect to skeletal malocclusion types.

In both radiographs, the gonial angle is determined from two tangents which were drawn from the inferior border of the mandible (Tweed's mandibular plane) and posterior borders of condyle and ramus of both sides, considering that the symphysis was not visible on orthopantomograms (Figure 1-Figure 2) The gonial angles were measured by using a software programme (Turcasoft, Samsun, 2012) and recorded. To determine the intraexaminer error, all measurements were repeated by the same examiner 2 weeks apart, and Dahlberg's formula was used. Error variance was found not to exceed $0,24^\circ$ in all the measurements.

Statistical analyzes

The SPSS for Windows statistical package version 23.0 (SPSS Inc., Chicago, IL) was used for all descriptive statistics and analyses. The level of significance was set to $P < .05$. Since the data were normally distributed, multiple comparison tests (ANOVA) and Tukey tests were used to determine differences among and between the three groups. Independent t-test was performed for comparison of orthopantomogram and cephalometric measurements. Mean values and standard deviations were calculated for all the parameters. Pearson correlation was applied for comparing the correlation of different variables. Statistical power analysis was performed to calculate the number of samples for %96 confidence interval.

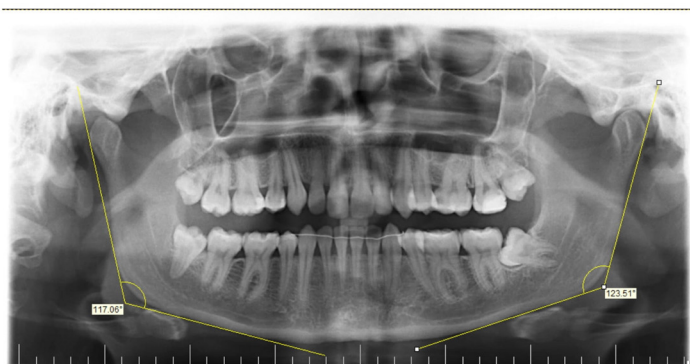

Figure 1. Measurement of the gonial angle in orthopantomogram

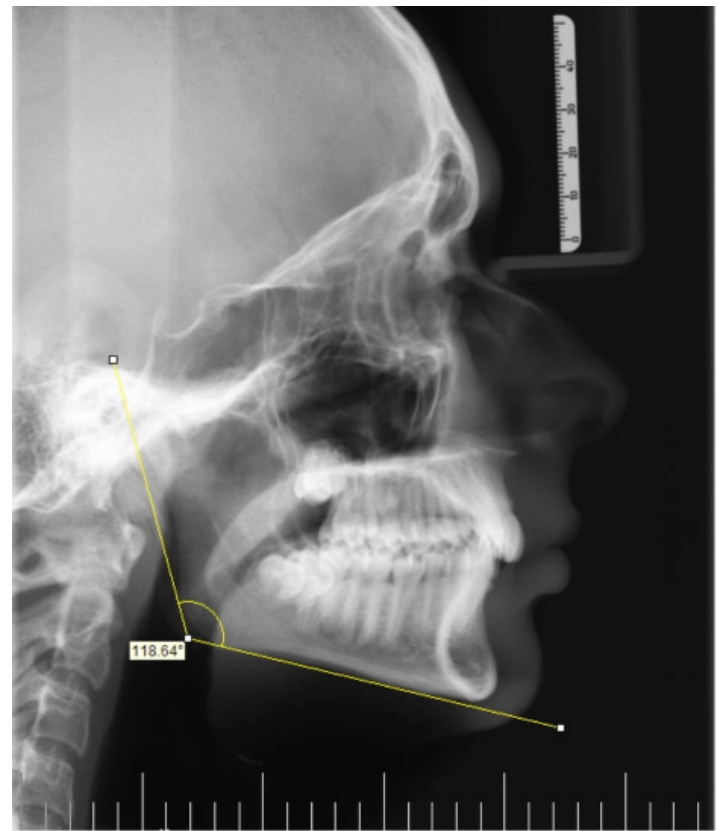


Figure 2. Measurement of the gonial angle in cephalogram

Results

Statistical power analysis was used to determine the required number of samples as the power of the test at 97%. The study sample consisted of 150 subjects that were distributed homogenous into three groups in terms of age and gender. The groups were classified as follows: CI I 50 subjects (mean age: $17,77 \pm 2,42$), CI II 50 subjects (mean age: $17,81 \pm 2,52$), CI III 50 subjects (mean age: $17,50 \pm 2,43$). Each group consisted of 25 males and 25 females. Tables 1, 2 and 3 compare the mean value and standard deviation of the gonial angle measured by orthopantomogram and cephalogram in different genders and different types of malocclusion.

Comparison of the Gonial Angle Between Right and Left Sides of Orthopantomograms

In orthopantomograms, the mean value of the right gonial angle was $127,93^\circ$, with a standard deviation of $8,22^\circ$, and the mean value of the left gonial angle was $127,84^\circ$ with a standard deviation of $8,24^\circ$ in CI I patients; with no statistically significant difference (Table 1). Similarly, no significant difference was found between the right and left gonial angles measured in orthopantomograms of CI II and CI III patients ($P = 0.712$)

Comparison of the Gonial Angle Between Orthopantomograms and Cephalograms

In CI I patients, the mean value of the gonial angle was measured $127,89 \pm 7,96^\circ$ in orthopantomogram and $127,77 \pm 7,87^\circ$ in cephalogram. No statistically significant difference was observed with respect to the diagnostic tool used. ($p=0,774$) In addition, a high correlation was found between the orthopantomogram and cephalogram gonial angle measurements ($r=0,931$). In CI II patients,

the mean value of gonial angle was measured $127,07 \pm 6,42^\circ$ in orthopantomogram and $129,75 \pm 7,30^\circ$ in cephalogram. In CI III patients, the mean value of gonial angle was measured $131,97 \pm 6,31^\circ$ in orthopantomogram and $132,92 \pm 6,95^\circ$ in cephalogram. The differences between the measurements were found statistically significant for both CI II ($p=0,00$) and CI III ($p=0,41$) patients. (Table 2)

Comparison of the Gonial Angle Between Genders

In CI I patients, the mean values of the external gonial angle in orthopantomogram measured between females and males were $127,49 \pm 7,76^\circ$ and $128,28 \pm 8,30^\circ$, respectively. The difference was not statistically significant. ($p=0,686$) There was also no gender difference in the gonial angle value in cephalograms. Further, no statistically significant difference was observed between females

and males in the gonial angle measured using these 2 diagnostic tools in both CI II and CI III patients. (Table 3)

Table 1. Comparison of the gonial angle between right and left sides of orthopantomograms

		N	Mean-st.dv	p value
CI I	Right	50	127.93±8.22	0.881
	Left	50	127.84±8.24	
CI II	Right	50	126.24±6.39	0.208
	Left	50	127.89±6.65	
CI III	Right	50	131.58±6.62	0.563
	Left	50	132.36±6.83	

Table 2. Comparison of the gonial angle between orthopantomograms and cephalograms

	CI I		CI II		CI III	
	Mean-st.dv	p value	Mean-st.dv	p value	Mean-st.dv	p value
OPG	127.89±7.96	0.774	127.07±6.42	0.000	131.97±6.31	0.041
CEPH	127.77±7.87		129.75±7.30		132.92±6.95	

st.dv: standart deviation

Table 3. Comparison of the gonial angle between genders

		CI I		CI II		CI III	
		Mean-st.dv	p value	Mean-st.dv	p value	Mean-st.dv	p value
OPG	Male	128.28±8.30	0.686	126.90±6.96	0.853	132.06±6.55	0.916
	Female	127.49±7.76		127.24±5.96		131.87±6.20	
CEPH	Male	128.33±8.53	0.279	128.64±7.39	0.287	132.75±7.54	0.860
	Female	127.20±7.28					

st.dv: standart deviation

Discussion

This study was performed to assess and compare the measurement of the gonial angle in orthopantomograms and cephalograms in adult patients with different skeletal malocclusion types. There is a certain variation in the size of the gonial angle depending on the measurement method used. [7] Gonial angle can be measured either by drawing the horizontal side of the gonial angle formed by the tangent to the lower border of the mandible or a line passing through the gnathion. Because of the limited visibility of the gnathion in an orthopantomogram, it might result in an inaccurate measurement of the gonial angle. [8]

Although the majority of studies have shown that orthopantomogram is a reliable and accurate method to determine the gonial angle [4,6,8], the majority of the samples used in these studies were not allocated according to their skeletal malocclusions. Okşayan et al. [9] concluded that orthopantomogram results were as reliable as lateral cephalograms in all Angle classifications. However, in the present study, orthopantomogram measurements were similar

with the cephalometric measurements just in CI I patients. The gonial angle value showed a significant difference between the two radiographs in CI II and CI III patients. Researchers revealed a great individual variation in gonial angle distortion and showed that the gonial angle differs by age and different types of malocclusion. [10-12] In orthopantomograms, magnification does change from the anterior region to the posterior region of the dentition and the object depth. [13] Considering the sagittal relationship in CI II and CI III patients viewing from the frontal plane, it could be suggested that the changing depth of the mandible could affect the gonial angle size. Therefore, significance between the gonial angle measurements in CI II and CI III patients may be due to the distortion in radiographs.

In our study, gender did not have a considerable effect on the gonial angle in both radiographs. Similar results were obtained by Shahabi et al. [14] and Upadhyay et al. [15]; who concluded that no gender differences was found between the two type of radiographs. Some previous studies have reported a difference in gonial angle value between genders. [9,16,17] Larazabal et

al. [18] stated that gender differences in the gonial angle value depended on the age of the patients. Ghosh et al. [19], Bhardwaj et al. [20], Huuonen et al. [21], and Xie and Ainamo [22] reported that females had a larger gonial angle, which might be due to the impact of masticatory forces. As a result of our study, the gonial angle value was not statistically significantly different between the right and left sides of orthopantomograms, which is in agreement with the results of the previous studies. [4,8,14]

Orthopantomograms are useful tools to determine growth direction through the measurement of the gonial angle and therefore to establish vertical growth problems. Orthopantomograms also provide more accurate information about both right and left sides of gonial angles of a patient avoiding the influence of the superimposed images found on cephalograms. [9] The ability to detect the growth direction from the orthopantomograms will be beneficial because the majority of dentists require this diagnostic tool during routine dental examinations.

Conclusion

Orthopantomograms, which is an already available tool, can be recommended for the determination of the gonial angle just in CI I patients. However, cephalograms still appears the better choice for the accurate measurement of the gonial angle in CI II and CI III patients.

Competing interests

The authors declare that they have no competing interest

Financial Disclosure

The financial support for this study was provided by the investigators themselves.

Ethical approval

This work has been approved by the Institutional Review Board.

Tugba Haliloglu Ozkan ORCID: 0000-0003-1180-8534

Selim Arici ORCID: 0000-0001-8890-2065

Enes Ozkan ORCID: 0000-0002-8182-9042

References

- Xiao D, Gao H, Ren Y. Craniofacial morphological characteristics of Chinese adults with normal occlusion and different skeletal divergence. *Eur J Orthod.* 2011;33:198-204.
- Nanda SK. Growth patterns in subjects with long and short faces. *Am J Orthod Dentofacial Orthop.* 1990;98:247-58.
- Tahmina K, Tanaka E, Tanne K. Craniofacial morphology in orthodontically treated patients of class III malocclusion with stable and unstable treatment outcomes. *Am J Orthod Dentofacial Orthop.* 2000;117:681-90.
- Zangouei-Booshehri M, Aghili HA, Abasi M, et al. Agreement between panoramic and lateral cephalometric radiographs for measuring the gonial angle. *Iran J Radiol.* 2012;9:178-82.
- Gavala S, Donta C, Tsiklakis K, et al. Radiation dose reduction in direct digital panoramic radiography. *Eur J Radiol* 2009;71:42-8.
- Kumar SS, Thailavathy V, Srinivasan D, et al. Comparison of Orthopantomogram and Lateral Cephalogram for Mandibular Measurements. *J Pharm Bioallied Sci.* 2017;9:92-5.
- Mattila K, Altonen M, Haavikko K. Determination of the gonial angle from the orthopantomogram. *Angle Orthod* 1997;47:107-10.
- 8- Radhakrishnan PD, Sapna Varma NK, Ajith VV. Dilemma of gonial angle measurement: Panoramic radiograph or lateral cephalogram. *Imaging Sci Dent.* 2017;47:93-7.
- Okşayan R, Aktan AM, Sökücü O, Haştar E, Ciftci ME. Does the panoramic radiography have the power to identify the gonial angle in orthodontics? *ScientificWorld Journal.* 2012;2012:219708.
- Slagsvold O, Pedersen K. Gonial angle distortion in lateral head films: a methodologic study. *Am J Orthod.* 1977;71:554-64.
- Altonen M, Haavikko K, Mattila K. Developmental position of lower third molar in relation to gonial angle and lower second molar. *Angle orthod.* 1977;47:249-55-8.
- Ranta R, Altonen M. A comparative study of gonial angle and growth of the lower third molar in cleft lip and palate. An orthopantomographical study. *Scand J Plast Reconstr Surg.* 1978;12:273-8.
- Stramotas S, Geenty JP, Petocz P, Darendeliler MA. Accuracy of linear and angular measurements on panoramic radiographs taken at various positions in vitro. *Eur J Orthod.* 2002;24:43-52.
- Shahabi M, Ramazanzadeh BA, Mokhber N. Comparison between the external gonial angle in panoramic radiographs and lateral cephalograms of adult patients with Class I malocclusion. *J Oral Sci.* 2009;51:425-9.
- Upadhyay RB, Upadhyay J, Agrawal P, Rao NN. Analysis of gonial angle in relation to age, gender, and dentition status by radiological and anthropometric methods. *J Forensic Dent Sci.* 2012;4:29-33.
- Raustia AM, Salonen MA. Gonial angles and condylar and ramus height of the mandible in complete denture wearers--a panoramic radiograph study. *J Oral Rehabil.* 1997;24:512-6.
- Ceylan G, Yanikoglu N, Yilmaz AB, et al. Changes in the mandibular angle in the dentulous and edentulous states. *J Prosthet Dent.* 1998;80:680-4.
- Larrazabal-Moron C, Sanchis-Gimeno JA. Gonial angle growth patterns according to age and gender. *Ann Anat.* 2018;215:93-6.
- Ghosh S, Vengal M, Pai KM, et al. Remodeling of the antegonial angle region in the human mandible: a panoramic radiographic cross-sectional study. *Med Oral Patol Oral Cir Bucal.* 2010;15:802-7.
- Bhardwaj D, Kumar JS, Mohan M. Radiographic evaluation of mandible to predict the gender and age. *J Clin Diagn Res.* 2014;8:66-9.
- Huuonen S, Sipilä K, Haikola B, et al. Influence of edentulousness on gonial angle, ramus and condylar height. *J Oral Rehabil.* 2010;37:34- 8.
- Xie QF, Ainamo A. Correlation of gonial angle size with cortical thickness, height of the mandibular residual body, and duration of edentulism. *J Prosthet Dent* 2004;91:477-82.