



Testiculotoxicity activities of isopropyl alcohol-based air freshener on the testis of adult Wistar rats

Adebanji Modupe Akingbade¹, Abdulfatai Olakunle Ojewale²,
Akihoromotei Idhirhi¹, Oluwaseun Ruth Olasehinde³,
Oluwaseun Babatunde Ibitoye⁴, Stephen Okikioluwa Aladeyelu⁵

ABSTRACT

Background/Aim: The effects of several household materials containing toxic chemicals have been a focus point in recent studies concerning male infertility. In this study, we evaluated the testiculotoxic effect of isopropyl alcohol-based air freshener (IBA) on the testis of adult Wistar rats. **Materials and Methods:** About 20 adult Wistar rats were divided at random, to four groups, five in each group. Group A rats were exposed to natural air for 4 weeks. The study groups (B, C, and D) were exposed to different graded doses of IBA for 4 weeks. Group B rats were exposed to 2.5 ml, Group C to 5 ml, and Group D to 10 ml of IBA for 6 h/day via whole body inhalation. **Results:** The results of the study showed a statistically significant ($P < 0.05$) decrease in testis weight, testis relative body weight and testis volume in the IBA exposed groups as compared to the control group. Reduction in sperm concentration, sperm motility, normal sperm morphology and significant ($P < 0.05$) increase in abnormal sperm morphology was observed in the study groups when compared to that of the control group. Furthermore, in comparison to the control group, degeneration of testicular architecture was observed in the study groups. **Conclusion:** Exposure of IBA to adult Wistar rats causes testicular histology damage and deranged sperm parameters.

¹Department of Anatomy, College of Medicine and Health Sciences, Afe Babalola University, Ado Ekiti, Ekiti, Nigeria, ²Department of Anatomy, Obafemi Awolowo College of Health Sciences, Olabisi Onabanjo University, Ikenne, Ogun, Nigeria, ³Department of Medical Biochemistry, College of Medicine and Health Sciences, Afe Babalola University, Ado Ekiti, Ekiti, Nigeria, ⁴Department of Anatomy, Faculty of Basic Medical Sciences, College of Medicine, University of Ibadan, Ibadan, Nigeria, ⁵Department of Anatomy, Faculty of Basic Medical Sciences, College of Health Sciences, Nnamdi Azikiwe University, Awka, Nigeria

Address for correspondence:
Abdulfatai Olakunle Ojewale,
Department of Anatomy,
Obafemi Awolowo College
of Health Sciences, Olabisi
Onabanjo University,
Ikenne, Ogun, Nigeria.
E-mail: anaphato2001@
yahoo.com

Received: January 05, 2017

Accepted: March 27, 2017

Published: April 18, 2017

KEY WORDS: Inhalation, isopropyl alcohol-based air, sperm parameter, testiculotoxicity, testicular architecture, testis, Wistar rats

INTRODUCTION

Infertility is a reproductive system disorder defined by the failure to achieve a clinical pregnancy after a year or more of

regular unprotected sexual intercourse. This definition could be considered bias toward the male because his status relies on that of the female partner, who may have reproductive issues of her own [1].

Male infertility can be caused by low sperm count due to endocrine disorders [2]. Testicular malformation, hormone imbalance, or blockage of the man's duct system is also possible causes. Although many of these can be treated through medication, surgery or hormonal substitution, some may be infinite [3].

Many household materials such as; allethrin-based mosquito coil [4], rhodinol and musk-based incense [5,6], propoxur [7,8], perfume [9] containing fragrances have been shown to be testiculotoxic.

The gonad is usually the active site for destruction by endocrine toxins because of its susceptibility to injuries [10]. Oxidative stress and related sperm deoxyribonucleic acid (DNA) damage have been identified as the major causes of male infertility [11]. The gonad has polyunsaturated fatty acid rich membrane structures, highly sensitive to oxidative stress, manifested through lipid peroxidation, leading to loss of the membrane integrity [12].

Air fresheners are consumer end products used in homes or commercial products used in restrooms that typically emit fragrance. There are many different methods of air fresheners. There are different types of air fresheners include sprays, candles, oils, gels, beads, and plug-ins. Air fresheners do not significantly reduce the air pollution, but rather add more substances with a fresh odor strong enough to mask a bad odor. Chemicals that can be found in air fresheners include: Benzene, formaldehyde, limonene, phthalate, and isopropyl alcohol (IPA) [13,14].

IPA is an active ingredient in JOSOJIM air freshener. IPA and its metabolite, acetone, act to depress the central nervous system [15].

It has shown that exposure to IPA causes; headache, dizziness, nausea, vomiting, anesthesia, hypothermia, hypotension, shock, respiratory depression, and coma. Exposure to the chemical is by ingestion, inhalation, or skin absorption [15].

Furthermore, it has also shown that exposure to IPA can lead to liver disease aggravation. However, little is known about the testiculotoxic effects of IPA-based air freshener (IBA) on the testis [16].

The scientific confirmation of the testiculotoxic effect of IBA freshener on the testis appears to be lacking. Hence, this study is to investigate the possible testiculotoxic effect of IBA on adult Wistar male rats to validate the issues previously explained.

MATERIALS AND METHODS

Materials

Air freshener

A common brand of air freshener "JOSOJIM" containing 0.10% w/w IPA, 0.9% w/w texapon, 0.8% w/w perfume, and

water was purchased from a Chino Supermarket, Ado-Ekiti, Ekiti state, Nigeria.

Other chemicals and reagents used

Sodium citrate, sodium bicarbonate, 10% neutral buffered formalin, hematoxylin and eosin were the product of BDH Chemicals, Ltd Poole England (Table 1).

Absolute alcohol xylene, chloroform, normal saline were the product of Sigma-Aldrich Chemicals, Oakville Ontario, Canada. All other chemicals were of analytical grade.

Experimental design

About 20 male Wistar rats weighing 200-220 g were obtained from the Animal House of Federal Polytechnic, Ado-Ekiti, Nigeria. An approval was sought and obtained from the Departmental Ethical Committee on animal use. The rats were allowed to acclimatize for 2 weeks and were fed freely on standard commercial mouse pellets from ABUAD farm's livestock feed Limited, Ado-Ekiti, Ekiti State, Nigeria.

Relatively constant environmental condition was maintained with proper aeration and a good source of light (12 h light/12 h dark and $22^{\circ}\text{C} \pm 2^{\circ}\text{C}$). Pelletised chow and water *ad-libitum* were provided. The weighing's and observations were done before the rats were exposed to IBA freshener. The weights of the animals were estimated at procurement, during acclimatization, at the commencement of the experiments and twice within a week throughout the duration of the experiment, using an electronic analytical and precision balance (BA210S, d = 0.0001 g) (Sartorius GA, Goettingen, Germany).

Experimental procedures involving the animals and their care were conducted in conformity with International, National and Institutional Guidelines for the care of Laboratory Animals in Biomedical Research and use of Laboratory Animals in Biomedical Research as Promulgated by the Canadian Council on Animal Care [17]. Further, the animal experimental models used conformed to the guiding principles for research involving animals as recommended by the Declaration of Helsinki and the Guiding Principles in the Care and use of Animals [18].

Table 1: Animal groupings and imiprothrin exposure

Groups	Exposure
A	The animals in this group served as the control and were exposed to fresh air for 4 weeks
B	The rats in this group were exposed to 5 ml of imiprothrin via inhalation for 6 h (9 am-3 pm) every day, for a period of 3-week
C	The rats in this group were exposed to 5 ml of imiprothrin via inhalation for 6 h (9 am-3 pm) every day, for a period of 4-week [22]
D	The rats in this group were exposed to 10 ml of imiprothrin via inhalation for 6 h (9 am-3 pm) every day, for a period of 4-week

Methods

Animals grouping and IBA freshener exposure

Four groups of rats (A, B, C, and D) consisting of 5 animals each were housed separately in four undisturbed cages with cross ventilation to avoid the cross exposure to air freshener fragrance [19].

Animal sacrifice and sample collection

The rats at the time of sacrifice, the animals were first weighed and then anesthetized by placing them in a closed jar containing cotton wool soaked in chloroform. The abdominal cavity was opened up through a midline abdominal-pelvic incision to expose the reproductive organs. Then, the testes and epididymis were excised. The weight of the testes of each animal was evaluated. The testes were weighed with an electronic analytical and precision balance (BA 210S, $d = 0.0001$ - Sartorius GA, Goettingen, Germany). The volume of each testis was measured by water displacement method. The two testes of each rat were measured, and the average value obtained for each of the two parameters was regarded as one observation.

Determination of epididymal sperm parameters

Progressive sperm motility

This was performed immediately after the semen collection. Semen was squeezed from the caudal epididymis onto a pre-warmed microscope slide (27°C) and two drops of warm 2.9% sodium citrate were added, the slide was then covered with a warm cover slip and examined under the microscope using $\times 400$ magnification. 10 fields of the microscope were randomly selected, and the sperm motility of 10 sperms was assessed on each field. Therefore, the motility of 100 sperms was assessed randomly. Sperms were labeled as motile, sluggish, or immotile. The percentage of motile sperms was defined as the number of motile sperms divided by the total number of counted sperms (i.e., 100) [20].

Epididymal sperm concentration

Spermatozoa in the right epididymis were counted by a modified method of Yokoi and Mayi [21]. Briefly, the epididymis was minced with anatomic scissors in 5 ml physiologic saline, placed in a rocker for 10 min, and allowed to incubate at room temperature for 2 min. After incubation, the supernatant fluid was diluted 1:100 with a solution containing 5 g sodium bicarbonate and 1 ml formalin (35%). Total sperm number was determined using the new improved Neuber's counting chamber (hemocytometer). Approximately 10 μ L of the diluted sperm suspension was transferred to each counting chamber of the hemocytometer and was allowed to stand for 5 min. This chamber was then placed under a binocular light microscope using an adjustable light source. The ruled part of the chamber was then focused and the number of spermatozoa counted in five 16-celled squares. The sperm

concentration was calculated, multiplied by 5 and expressed as $[X] \times 10^6/\text{ml}$, where $[X]$ is the number of spermatozoa in a 16-celled square.

Sperm morphology

The sperm cells were evaluated with the aid of light microscope at $\times 400$ magnification. Caudal sperm was taken from the original dilution for motility and diluted 1:20 with 10% neutral buffered formalin (Sigma-Aldrich, Oakville, ON, Canada). 500 sperm from the sample were scored for morphological abnormalities [22]. Briefly, in wet preparations using phase-contrast optics, spermatozoa were categorized. In this study, a spermatozoon was considered abnormal morphologically if it had one or more of the following features: Rudimentary tail, round head and detached head and was expressed as a percentage of morphologically normal sperm.

Tissue preparation for light microscopy

This was done as essentially as described by Akpantah *et al.* [23]. The organs were cut in slabs of about 0.5 cm thick and fixed in Bouin's fluid for a day after which it was transferred to 70% alcohol for dehydration. The tissues were passed through 90% alcohol and chloroform for different durations before they were transferred into two changes of molten paraffin wax for 20 min each in an oven at 57°C. Every fifth serial section of 5 μ m thick were obtained from a solid block of tissue and were stained with hematoxylin and eosin stains, after which they were passed through a mixture of equal concentration of xylene and alcohol. Following clearance in xylene, the tissues were oven-dried. Light microscopy was used for the evaluations.

Statistical Analysis

All data were expressed as mean \pm standard deviation of a number of experiments ($n = 5$). The level of homogeneity among the groups was tested using analysis of variance as done by Snedecor and Cochran [24]. Where heterogeneity occurred, the groups were separated using Duncan multiple range tests. A value of $P < 0.05$ was considered to indicate a significant difference between groups [25]. Analysis of data was performed using both electronic calculator and Statistical Package for Social Sciences (SPSS)/PC computer program (version 19.0 SPSS, Cary, NC, USA).

RESULTS

Effects of IPA-based Air Freshener on Gross Anatomical Parameters of Wistar Rats

There was nonsignificant ($P > 0.05$) decrease in testis weight, testis weight/body weight ratio and testis volume in 2.5 ml IPA-based air freshener exposed group when compared to the control counterpart, whereas statistically significant ($P < 0.05$) decrease was observed in 5 and 10 ml IPA-based air freshener exposed group compared to the control counterpart [Table 2].

Key:

- Group A: The animals in this group served as the control and were exposed to fresh air for 4 weeks.
- Group B: The rats in this group were exposed to 5 ml of imiprothrin via inhalation for 6 h (9 am-3 pm) every day, for a period of 3-week.
- Group C: The rats in this group were exposed to 5 ml of imiprothrin via inhalation for 6 h (9 am-3 pm) every day, for a period of 4-week [22].
- Group D: The rats in this group were exposed to 10 ml of imiprothrin via inhalation for 6 h (9 am-3 pm) every day, for a period of 4-week.

Effect of IPA-based Air Freshener on the Sperm Parameters of Male Rat

Key:

- Group A: The animals in this group served as the control and were exposed to fresh air for 4 weeks.
- Group B: The rats in this group were exposed to 5 ml of imiprothrin via inhalation for 6 h (9 am-3 pm) every day, for a period of 3-week.
- Group C: The rats in this group were exposed to 5 ml of imiprothrin via inhalation for 6 h (9 am-3 pm) every day, for a period of 4-week [22].
- Group D: The rats in this group were exposed to 10 ml of imiprothrin via inhalation for 6 h (9 am-3 pm) every day, for a period of 4-week.

Sperm count

As shown in Table 3, the group of rats exposed to 2.5 ml of IPA-based air freshener showed nonsignificant ($P > 0.05$) decrease in sperm concentration ($112.84 \pm 2.4 \times 10^{-6}/\text{ml}$) compared to the control group ($129.2 \pm 2.9 \times 10^{-6}/\text{ml}$), 5 ml IPA-based air freshener exposed group provoked significantly ($P < 0.05$) decreased sperm concentration ($88.56 \pm 1.9 \times 10^{-6}/\text{ml}$) and 10 ml of IPA-based air freshener exposed group showed marked oligospermia ($69.72 \pm 1.4 \times 10^{-6}/\text{ml}$) with their sperm concentration being significantly lower ($P < 0.05$) compared to the control group.

Sperm motility

As shown in Table 3, although the sperm motility of 2.5 ml of IPA-based air freshener exposed group showed a lower nonsignificantly ($P > 0.05$) ($61.44 \pm 4.8\%$) compared to the control group ($83.4 \pm 6.2\%$). However, the 5 and 10 ml IPA-based air freshener exposed groups still had significantly lower ($P < 0.05$) ($50.62 \pm 3.5\%$) and ($39.8 \pm 2.0\%$) value compared to the control counterpart.

Sperm morphology

As shown in Table 3, the 2.5 ml IPA-based air freshener group showed evidence of nonsignificantly ($P > 0.05$) decrease in normal sperm morphology ($79.8 \pm 7.6\%$) and nonsignificantly ($P > 0.05$) increased in abnormal sperm morphology ($20.2 \pm 6.1\%$) compared to the control group ($84.1 \pm 9.2\%$, $15.9 \pm 5.8\%$), respectively. The 5 ml IPA-based air freshener group however, showed a significant ($P < 0.05$) decrease in normal sperm morphology ($58.82 \pm 2.2\%$) and a significant ($P < 0.05$) increase in abnormal sperm morphology ($41.18 \pm 1.7\%$) when compared to the control group. Moreover, the rats exposed to 10 ml IPA-based air freshener also had significant ($P < 0.05$) ($36.6 \pm 1.8\%$) decrease in normal sperm morphology and a significant increase in abnormal sperm morphology ($P < 0.05$) ($63.4 \pm 3.8\%$) when compared to the control group.

Effects of IPA-based Air Freshener on the Histological Profiles of the Testis

As shown in Figure 1, the cross-section of the seminiferous tubules of the control groups had a normal epithelia outline, intact interstitium, moderately circular or oval in outline with normal seminiferous epithelium and numerous spermatozoa within their lumen.

As shown in Figure 2, there was minimal damage in the testicular interstitium of Group B rats, exposed to 2.5 ml IPA-based air freshener. The outline of the seminiferous tubules was also moderately reduced, and the spermatozoa within their lumen were altered in this group, compared to the control group.

Table 2: Effect of imiprothrin on gross anatomical parameters of Wister rats treatment

Groups	Initial body weight (g)	Final body weight (g)	Body weight diff. (g)	Testis weight (g)	Testis volume (ml)	Testis weight/body weight ratio
Group A	210.0 \pm 2.2	230.0 \pm 1.2	20.0	1.30 \pm 3.1	1.25 \pm 0.3	0.006
Group B	228.0 \pm 4.9	200.0 \pm 1.5	28.0*	1.20 \pm 0.6	1.14 \pm 0.2	0.006
Group C	235.2 \pm 3.0	181.0 \pm 2.0	57.0*	1.9 \pm 0.7*	1.09 \pm 0.4*	0.005*
Group D	242.0 \pm 5.4	180.0 \pm 4.4	62.0*	0.62 \pm 0.5*	0.65 \pm 0.3*	0.003*

* $P < 0.05$ significantly different from control. Values are expressed as mean \pm SD for $n=5$ in each group. SD: Standard deviation

Table 3: Effect of imiprothrin on the sperm parameters of male rats

Treatment groups	Sperm count ($\times 10^6$ ml)	Sperm motility (%)	Sperm normal (%)	Morphology abnormal (%)
Group A	142.5 \pm 3.0	98.7 \pm 6.7	84.9 \pm 6.7	20.2 \pm 5.8
Group B	131.2 \pm 2.7	72.4 \pm 4.9	75.6 \pm 4.8	24.8 \pm 6.3
Group C	98.8 \pm 1.9*	64.8 \pm 3.6*	68.4 \pm 2.6*	29.7 \pm 1.8
Group D	75.9 \pm 1.5*	58.3 \pm 2.3*	53.8 \pm 1.9*	46.52 \pm 3.9*

* $P < 0.05$ significantly different from control, value are expressed as mean \pm SD for $n=5$ in each group. SD: Standard deviation

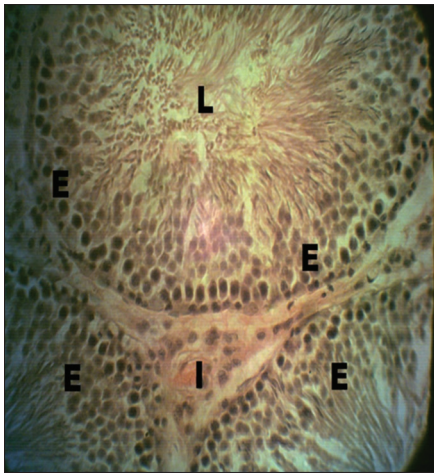


Figure 1: Cross-section of the testis of Group A rats (control). Treatment: Exposed to natural fresh air for 4 weeks (hematoxylin and eosin, $\times 400$), E: Seminiferous epithelium, L: Lumen of seminiferous tubule, I: Testicular interstitium

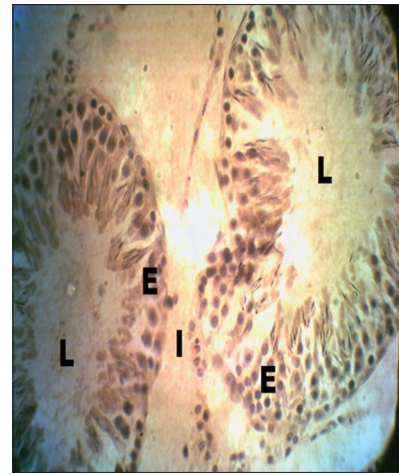


Figure 3: Cross-section of the testis of Group C rats. Treatment: Exposed to 5 ml of imiprothrin for 4 weeks (hematoxylin and eosin $\times 400$), E: Seminiferous epithelium, L: Lumen of seminiferous tubule, I: Testicular interstitium

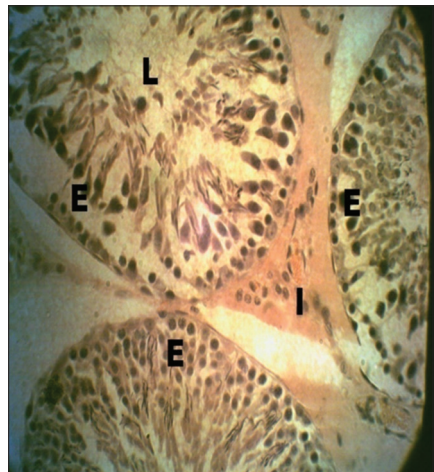

Figure 2: Cross-section of the testis of Group B rats. Treatment: Exposed to 5 ml of imiprothrin for 3 weeks (hematoxylin and eosin $\times 400$), E: Seminiferous epithelium, L: Lumen of seminiferous tubule, I: Testicular interstitium

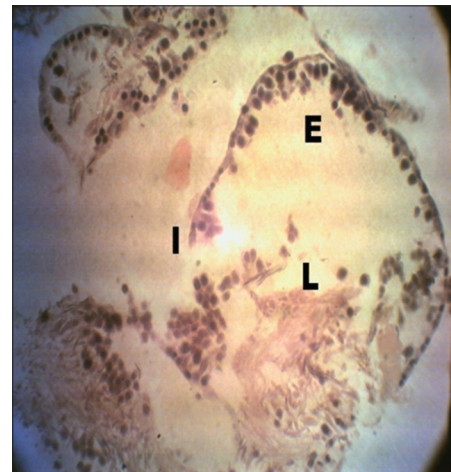

Figure 4: Cross-section of the testis of Group D rats. Treatment: Exposed to 10 ml of imiprothrin for 4 weeks (hematoxylin and eosin $\times 400$), E: Seminiferous epithelium, L: Lumen of seminiferous tubule, I: Testicular interstitium

As shown in Figure 3, the seminiferous tubules of the rats in Group C that were exposed to 5 ml IPA-based air freshener showed moderate degeneration in testicular histoarchitecture. The testicular interstitium was also reduced and was detached from the seminiferous tubules, isolating them from each other. The diameter of the lumen was reduced, characterized by slight vacuolization of the interstitium and reduced spermatozoa.

As shown in Figure 4, the rats in Group D that were exposed to 10 ml of IPA-based air freshener showed severe degeneration of testicular interstitium, a significant reduction in the diameter of seminiferous tubules and lumens devoid of spermatozoa were observed. There was also a significant reduction of the basal seminiferous epithelial cells.

DISCUSSION

Studies have shown that spermatozoa cell membrane to be principally vulnerable to oxidative injury damage through the lipid peroxidation [26]. Several studies have also shown that testicular oxidative stress is characterized by a series of morphological, biochemical and physiological changes in the injured cells [27,28]. In a biological system, vital macromolecules such as proteins, lipid, and DNA may be oxidatively modified resulting in cell or tissue damage, hence a number of diseases have been linked to an excess production of free radicals [29].

This study was designed to investigate the testiculotoxicity implication of IBA freshener on the testis of adult Wistar rats.

It was observed in the study that the control group of animals had a nonsignificant increase in gross anatomical parameters. The improved values of body weight of the control animals could mean that they were still in their active growth phase during the study [27].

The findings from this study showed a decrease in the testis weight, testis weight/body weight ratio and testis volume (ranging from nonsignificant [2.5 ml exposed group], to a significant decrease [10 ml exposed group]) in the study groups ($P < 0.05$), as compared to the control group. The results are in conformity with the previous reports of a considerable decrease in body and testicular weight as a result of seminiferous tubular derangements [8,30-33].

Furthermore, the decrease observed in body weight of the rats may be due to modification of protein metabolism, which was thought to be used for energy production rather than for growth [34].

The histological evidence in this study showed degenerative changes characterized by vacuolization of the interstitium, reduced luminal spermatozoa and devoid spermatozoa in cross-section of the seminiferous tubules of rats exposed to various grades of IPA-based air freshener (2.5, 5, and 10 ml). This is in conformity with several other previous reports on male infertility experiments in animal models involving cytotoxic chemicals [10,27], which showed that animals exposed with cytotoxic chemicals have degenerative changes in the seminiferous tubules as showed by the present of the empty lumen with loose lining cells of the tubules.

The rats that were exposed to the air freshener showed a significant reduction in spermatozoa concentration, sperm motility, and normal sperm morphology and a significant increase in abnormal sperm morphology ($P < 0.05$), when compared to the control groups. The results obtained were consistent with several other reports on testicular toxicity [35,36].

The decrease in sperm parameters of rats that were exposed to air freshener could be as a result of active metabolites generated by IPA which could have aided the production of lipid peroxides, resulting in oxidative degenerative changes in the cell and inhibition of mitochondrial action and eventually causing cell death [37-39].

CONCLUSION

The results of this study showed that IBA freshener causes the following effects on the Wistar rats' testis.

- a. Testis histoarchitecture degeneration
- b. Deranged sperm parameters

The fact that IBA freshener exerts a profound damage to the testis in laboratory animals warrants a further study for its testiculotoxicity in people who are more commonly exposed to this type of air freshener.

Despite these well-established toxic effects of IBA freshener on the rat testis, there is a need for further investigations in humans to determine its pestilent dose.

REFERENCES

1. World Health Organization. Reproductive Health Indicators for Global Monitoring: Report of the Second Interagency Meeting. Vol. 1. Geneva: World Health Organization; 2010. p. 19.
2. Jarow JP. Endocrine causes of male infertility. Urol Clin North Am 2003;30:83-90.
3. Mishail A, Marshall S, Schulsinger D, Sheynkin Y. Impact of a second semen analysis on a treatment decision making in the infertile man with varicocele. Fertil Steril 2009;91:1809-11.
4. Akunna GG, Saalu LC, Ogunlade B, Ogunmodede OS, Akingbade AM. Antifertility role of allethrin based mosquito coil in animal models. IJBPA 2013;2:192-207.
5. Akingbade AM, Saalu LC, Oyeibanji OO, Oyeniran DA, Akande OO, Akunna GG. Rhodinol-based incense testiculotoxicity in albino rats: Testicular histology, spermatogenic and biochemical evaluations. J Pharmacol Toxicol 2014;9:68-81.
6. Akingbade AM, Akunna GG, Faeji CO, Oyeniran DA, Adefisayo MA, Oni OI. Histomorphometric and spermatogenic evaluation of musk based-incense induced testiculotoxicity in adult albino rats. Sch J Appl Med Sci 2015;3:2111-7.
7. Oyewopo AO, Saalu LC, Osinubi AA, Imosemi IO, Omotoso GO, Adefolaju GA. The attenuating effect of zinc on propoxur-induced oxidative stress, impaired spermatogenesis and deranged steroidogenesis in wistar rats. J Med Med Sci 2010;1:178-84.
8. Ahmed M, Mohamadin BS, Amany A, Abd EA, Ahmed A, Elberry FA. Protective effects of Nigella sativa oil on propoxur-induced toxicity and oxidative stress in rat brain regions. Pestic Biochem Physiol 2010;98:128-31.
9. Akunna GG, Saalu LC, Ogunlade B, Akingbade AM, Anderson LE, Olusolade FS. Histo-morphometric evidences for testicular derangement in animal models submitted to chronic and sub-chronic inhalation of fragrance. Am J Res Commun 2015;3:85-101.
10. Saalu LC, Osinubi AA, Olagunju JA. Early and delayed effects of doxorubicin on testicular oxidative status and spermatogenesis in rats. Int J Cancer Res 2010;6:1-9.
11. Smith ER, Cayrou C, Huang R, Lane WS, Côté J, Lucchesi JC. A human protein complex homologous to the Drosophila MSL complex is responsible for the majority of histone H4 acetylation at lysine 16. Mol Cell Biol 2005;25:9175-88.
12. Sokol RZ. The hypothalamic-pituitary-gonadal axis as a target for toxicants. In: Sipes IG, McQueen CA, Gandolfi AJ, editors. Comprehensive Toxicology. Vol. 10. Elsevier Science; 1997. p. 87-98.
13. Hanke W, Jansson B, Komulainen H, Ladefoged O, Mangelsdorf I, Steenhout A. Opinion on risk assessment on indoor air quality. Environ Int 2007;34:51-7.
14. Yuning T, Noor Z. Comparison Effect of Gel and Spray Air Freshener Exposure on Diameter of Seminiferous Tubules and Concentration Sperm of White Rats.
15. Slaughter RJ, Mason RW, Beasley DM, Vale JA, Schep LJ. Isopropanol poisoning. Clin Toxicol 2014;52:470-8.
16. Kapp RW Jr, Bevan C, Gardiner TH, Banton MI, Tyler TR, Wright GA. Isopropyl alcohol and aggravation of liver disease. Regul Pharmacol 1998;23:183-92.
17. Canadian Council of Animal Care. Guide to the Handling and Use of Experimental Animals. Vol. 85. Ottawa: 2 United States NIH Publications; 1985. p. 45-7.
18. World Medical Association; American Physiological Society. Guiding principles for research involving animals and human beings. Am. J Physiol Regul Integr Comp Physiol 2002;283:281-3.
19. Mukhtar A, Nasser A, Majed S, Tajamul H. Potential changes in rat spermatogenesis and sperm parameters after inhalation of Boswellia papyrifera and Boswellia carterii incense. Int J Environ Res Public Health 2013;10:830-44.
20. Mohammad-Reza P, Farzaneh D, Taherch TK, Zoherb PP. The effects of hydroalcoholic extract of Actinidia chinensis on sperm count and motility, and blood levels of estradiol and testosterone in male rats. Arch Iran Med 2005;8:211-6.
21. Yokoi K, Mayi ZK. Organ apoptosis with cytotoxic drugs. Toxicology

- 2003;290:78-95.
22. Atessahin AI, Karahan G, Turk S, Yilmaz S, Ceribasi AO. Protective role of lycopene on cisplatin induced changes in sperm characteristics, testicular damage and oxidative stress in rats. *Reprod Toxicol* 2006;21:42-7.
23. Akpantah AO, Oremosu AA, Ajala MO, Noronha CC, Okanlawon AO. The effect of crude extract of *Garcinia kola* seed on the histology and hormonal milieu of male sprague dawley rats' reproductive organs. *Niger J Health Biomed Sci* 2003;2:40-6.
24. Snedecor GW, Cochran WG. *Statistical Method*. 7th ed. Iowa: Iowa State University Press; 1980. p. 215.
25. Duncan BD. Multiple range tests for correlated and heteroscedastic means. *Biometrics* 1957;13:359-64.
26. Sachdev S, Davies KJ. Production, detection, and adaptive responses to free radicals in exercise. *Free Radic Biol Med* 2008;44:215-23.
27. Saalu LC, Jewo PI, Fadeyebi IO, Ikuerowo SO. The effect of unilateral varicocele on contralateral testicular histo-morphology in *Ratus norvegicus*. *J Med Sci* 2008;8:654-5.
28. Saalu LC, Enye LA, Osinubi AA. An assessment of the histomorphometric evidences of doxorubicin-induced testicular cytotoxicity in wistar rats. *Int J Med Med Sci* 2009;1:370-4.
29. Willcox JK, Ash SL, Catignani GL. Antioxidants and prevention of chronic disease. *Crit Rev Food Sci Nutr* 2004;44:275-95.
30. Ishmael J, Lithfield MH. Chronic toxicity and carcinogenic evaluation of permethrin in rats and mice. *Fundam Appl Toxicol* 1988;11:308-22.
31. Schoenig GP. Mammalian toxicology of pyrethrum extract. In: Casida JE, Quistad GB, editors. *Pyrethrum Flowers: Production, Chemistry, Toxicology and Uses*. New York: Oxford University Press; 1995. p. 249-57.
32. Tavera-Mendoza L, Ruby S, Brousseau P, Fournier M, Cyr D, Marcogliese D. Response of the amphibian tadpole (*Xenopus laevis*) to atrazine during sexual differentiation of the testis. *Environ Toxicol Chem* 2002;21:527-31.
33. Wilhelms KW, Cutler SA, Proudman JA, Anderson LL, Scanes CG. Atrazine and the hypothalamo pituitary-gonadal axis in sexually maturing precocial birds: Studies in male Japanese quail. *Toxicol Sci* 2005;86:152-60.
34. Li MD, Kane JK, Konu O. Nicotine, body weight and potential implications in the treatment of obesity. *Curr Top Med Chem* 2003;3:899-919.
35. Elbetieha A, Da'as SI, Khamas W, Darmani H. Evaluation of the toxic potentials of cypermethrin pesticide on some reproductive and fertility parameters in the male rats. *Arch Environ Contam Toxicol* 2001;41:522-8.
36. Zhang C, Yeh S, Chen YT, Wu CC, Chuang KH, Lin HY, *et al.* Oligozoospermia with normal fertility in male mice lacking the androgen receptor in testis peritubular myoid cells. *Proc Natl Acad Sci U S A* 2006;103:17718-23.
37. Infurna R, Levy B, Meng C, Yau E, Traina V, Rolofson G, *et al.* Teratological evaluations of atrazine technical, a triazine herbicide, in rats and rabbits. *J Toxicol Environ Health* 1988;24:307-19.
38. Kniewald J, Osredecki V, Gojmerac T, Zechner V, Kniewald Z. Effect of s-triazine compounds on testosterone metabolism in the rat prostate. *J Appl Toxicol* 1995;15:215-8.
39. Stevens JT, Breckenridge CB, Wetzel L. A risk characterization for atrazine: Oncogenicity profile. *J Toxicol Environ Health A* 1999;56:69-109.

© **EJManager**. This is an open access article licensed under the terms of the Creative Commons Attribution Non-Commercial License (<http://creativecommons.org/licenses/by-nc/3.0/>) which permits unrestricted, noncommercial use, distribution and reproduction in any medium, provided the work is properly cited.

Source of Support: Nil, Conflict of Interest: None declared.