

A study of placental histological changes in gestational diabetes mellitus on account of fetal hypoxia

Geena Augustine¹, Mumtaz Pulikkathodi², Renjith S³, Jithesh TK⁴

¹Department of Anatomy, MES Medical College, Perinthalmanna, Kerala, India.

²Department of Obstetrics and Gynecology, MES Medical College, Perinthalmanna, Kerala, India.

³Department of Anatomy, Jubilee Mission Medical College and Research Center, Thrissur, Kerala, India.

⁴Central Research Lab, MES Medical College, Perinthalmanna, Kerala, India.

Correspondence to: Geena Augustine, E-mail: geenapinto12@gmail.com

Received April 29, 2016. Accepted May 24, 2016

Abstract

Background: Diabetes in pregnancy has been associated with increased fetal growth and with a high risk of prenatal and postnatal complications. Metabolic impairments in maternal obesity and gestational diabetes mellitus (GDM) provoke an unusual commotion in peripheral blood and prompt vascular structure alterations, which affect the placental development and function. These fetal metabolic changes seem to be related to the duration of diabetes.

Objective: To find out placental histological changes in GDM, as the placenta is the regulator of nutrient composition and supply from mother to fetus and the source of hormonal signals that affect maternal and fetal metabolism, appropriate development of the placenta is crucial to healthy fetal development. Hypoxia has significant effects on placental development, causing hypercapillarization of the villous vasculature.

Materials and Methods: A prospective study was conducted comprising 58 subjects. The placenta was collected soon after delivery. After gross examination, placenta was processed for histological study.

Result: Placenta shows significant difference between the test and control group. There were significant microscopic findings. The area of GDM placenta is 219.65 ± 31.34 and that of the normal placenta is 182.52 ± 28.66 . The thickness of GDM placenta is 3.15 ± 0.40 and that of the normal placenta is 1.67 ± 0.28 . The circumference of GDM placenta is 52.32 ± 3.70 and that of the normal placenta is 48.35 ± 4.66 . The diabetic placenta showed increased syncytial knots, fibrinoid necrosis, decreased vascular syncytial membrane, and chorangiomas.

Conclusion: Intrauterine hypoxia can cause cellular damage that occurs within the central nervous system. This study showed several significant morphological and histological differences in the placenta of the mother with GDM. These changes were absent in normal placenta. The assessment of various histological changes in the placenta on account of hypoxia in GDM is helpful for the retrospective explanations of complications in pregnancy.

KEY WORDS: Gestational diabetes mellitus, hyperglycemia, fetal hypoxia, placenta, chorangiomas

Access this article online

Website: <http://www.ijmsph.com>

DOI: 10.5455/ijmsph.2016.29042016494

Quick Response Code:



Introduction

Gestational diabetes mellitus (GDM) is a complication associated with pregnancy defined as any degree of glucose intolerance that occurs or is first discovered during pregnancy, with average values signaled before, and usually after pregnancy.^[1] Gestational diabetes is caused when insulin receptors do not function properly. This is likely

because of pregnancy-related factors such as the presence of human placental lactogen that interferes with susceptible insulin receptors.^[2] Not only does diabetes have an effect on the intrauterine environment, but it also may influence growth rates in neonates that are breast-fed by mothers with diabetes, as infants retain some programming vulnerability for a short period after birth.^[3]

Diabetes in pregnancy has been associated with increased fetal growth and with a high risk of prenatal and postnatal complications. In pregestational diabetes, analysis of fetal blood obtained by cordocentesis has revealed polycythemia and acidemia but not hypoxemia. These fetal metabolic changes seem to be related to the duration of diabetes, with maternal glycosylated hemoglobin positively associated with fetal hematocrit and erythropoietin.^[4] In pregestational diabetes, fetal plasma insulin and fetal insulin/glucose ratio are positively related to the severity of macrosomia and fetal acidemia, suggesting the role of fetal pancreatic beta cell hyperplasia in the pathogenesis of both fetal acidemia and neonatal hypoglycemia and macrosomia.^[5]

Hypoxia has significant effects on placental development, causing hypercapillarization of the villous vasculature, that is, branching angiogenesis, an effect similar to that seen in vivo at high altitude and with maternal anemia. Intrauterine hypoxia occurs when the fetus is deprived of an adequate supply of oxygen. It may be due to a variety of reasons such as prolapsed or occlusion of the umbilical cord, placental infarction, maternal smoking, and complicated cases of GDM. Intrauterine hypoxia can cause cellular damage that occurs within the central nervous system.

There is a strong association between pregnancy in women with any form of diabetes and high infant mortality and morbidity in their offspring.^[6] The frequency of congenital malformation, as well as morbidity associated with maternal diabetes, is directly related to the severity of diabetes. Abnormalities in systems such as the cardiovascular system, musculoskeletal, and central nervous system occur five times more often in the offspring of the mothers with diabetes.

Intrauterine hypoxia is associated with a variety of maternal, placental, and fetal conditions, which may manifest differently and have different outcomes.^[7] In all normal mature placentas, the villous capillaries are sinusoidal and closely approximated to overlying trophoblast. In many villi, the dilated capillaries bulge out toward the intervillous space, over such vessels, the syncytium is often thinned and anuclear, and may appear to be fused with the vessel wall to form a "vascular syncytial membrane (VSM)." Deficiency of VSM (<5% of villi showing VSM) may be seen because of a manifestation of villous maturation. Immature appearing large diameter intermediate villi with cellular stroma, few terminal villous branching, and right sprouts admixed with more mature appearing intermediate villi. Hence, the villous morphology is often reminiscent of that seen in the third early trimester. Deficiency of VSM results in increased risks of deficiencies in placental transport, abnormalities of placental volume, fetal intrauterine growth restriction, and perinatal morbidity and mortality.

Chorangiosis is a numerical increase of capillaries within the peripheral, placental villi, and may be an indicator of chronic prenatal hypoxia. Chorangiosis is a vascular hyperplasia in the terminal chorionic villi. The diagnostic criteria for chorangiosis were described by Altshuler in 1984, as the presence of a minimum of 10 terminal villi, containing more than 10 capillaries per villous in 10 medium power fields in at least 3 or more random, noninfarcted placental areas.^[8] Intravillous fibrinoid was described as a distinct fibrinoid material appearing in the subtrophoblastic space that finally occupies the whole villous stroma. Intravillous fibrinoid deposits are increased in pathological conditions including diabetes. Fibrinoid necrosis was seen as small nodules of homogenous eosinophilic material within the villi. At places, the fibrinoid material had enlarged by pushing the basement membrane and compressing the entire villous stroma.

Diabetic insults at the beginning of gestation may have long-term effects on these barriers, which can be revealed more through the histological staining. These histological changes can lead to metabolic disturbances. As the prevalence of diabetes is very high in Kerala, India, efficient management of GDM can prevent or delay the complication.^[9] This study population is from the Malappuram District in Kerala, which is one of the backward regions that comprises a community where the socioeconomic and educational standards are less when compared with other districts in Kerala. So, this study from the Malabar population can throw much insight and increase awareness for the better control of diabetes mellitus during the pregnancy, as the number of parties of each woman in this community is more than three. Furthermore, it may improve options to possibly prevent GDM and complications for the mother and child.

Materials and Methods

This prospective study was conducted at MES Medical College Hospital, Perinthalmanna, Kerala, India. The study had started after obtaining the clearance from the institutional ethical committee. Before sample collection, the informed consent was obtained from the subjects. The placenta was collected soon after delivery and washed in running tap water. A gross examination was carried out to record morphological parameters. Surface was dried by using blotting paper and the placenta was cut to obtain two samples of size 1 × 1 cm. The pieces were routinely processed for paraffin embedding and sectioning. Then the slides were stained with hematoxylin-eosin stain and examined under a microscope.

Result

The test population consisted of 58 subjects. Thirty samples from women with GDM were designated as "GDM group." Twenty-eight samples from healthy pregnant women were identified as "Control group." The parameters were compared between these two groups. The results were

statistically analyzed. All the data were presented as mean \pm standard deviation.

Placenta shows significance difference between the test and control group. Morphological parameters are depicted in Table 1. The weight of the placenta shows a significant increase in test population when compared with control population. The burden of GDM placenta is 560.10 ± 155.91 , and the healthy placenta is 462.20 ± 8.57 . All other parameters including area, thickness, diameter, and circumference of GDM placenta show a significant increase when compared with control placenta. The volume of GDM and normal placenta is 487.65 ± 47.12 and 419.20 ± 48.49 . The area of GDM placenta is 219.65 ± 31.34 and that of the normal placenta is 182.52 ± 28.66 . The thickness of GDM placenta is 3.15 ± 0.40 and that of the normal placenta is 1.67 ± 0.28 . The circumference of GDM placenta is 52.32 ± 3.70 and that of the normal placenta is 48.35 ± 4.66 .

The important microscopic findings are depicted in Table 2. The diabetic placenta showed increased syncytial knots, fibrinoid necrosis, decreased VSM, and chorangiomas. Syncytial knots are focal aggregation or clumping of syncytial nuclei on the surface of a tertiary placental villous, forming a multinucleated protrusion from the villous face of a tertiary placental villous, forming a multinucleated protrusion from the villous surface. These are small collections of structureless, homogeneous, and eosinophilic material within the villous.

In all normal mature placentas, the villous capillaries are sinusoidal and closely approximated to overlying trophoblast. In many villi, the dilated capillaries bulge out toward the intervillous space, over such vessels the syncytium is often thinned and anuclear and may appear to be fused with the vessel wall to form a VSM. Chorangiomas is a numerical increase in the capillaries within the peripheral, placental villi, and may be an indicator of chronic prenatal hypoxia.

Discussion

This study showed several significant morphological and histological differences in the placenta of the mother with GDM. These changes in the structure of villous capillaries

would disrupt the environment of fetal development. In this study, deficiency of vasculo-syncytial membrane was observed in GDM placenta, which can adversely affect the transplacental transport, metabolism, and oxygen diffusing. The increasing metabolic activity of placental mitochondria throughout gestation results in increasing oxidative stress in a healthy pregnancy.

A study by Ahmed^[10] suggests that despite similarities in placental abnormalities, differences in placental pathology may reflect differences in pathophysiology among different types of diabetes. These changes were absent in normal placenta. Low oxygen tension is physiological for organogenesis and is a key regulator of cellular events in early trophoblast differentiation. At the beginning of gestation, the trophoblast develops by histiotrophic nutrition but the establishment of intervillous blood flow at 10–12 weeks gestation subjects the trophoblast to oxidative stress. This study results showed that the placental weight may become the single most important factor in determining fetal growth, which is in agreement with the learning of Wilson *et al.*^[11]

In most GDM cases, the placental weight was significantly increased when compared with standard. Other parameters such as placental length, diameter, and volume showed a significant increase. Fetal birth weight was the simplest setting, which serves as the most reliable indicator of the growth, development, and sustenance of the neonate. Most of the babies in GDM cases had macrosomia. This oxidative stress is exacerbated in pregnancies complicated

Table 2: Microscopic features of GDM placenta

Parameters	Test	Control
Increased syncytial knots	Observed in 17 cases	Nil
Fibrinoid necrosis	Observed in 14 cases	Nil
Decreased vasculo-syncytial membrane	Observed in 15 cases	Nil
Chorangiomas	Observed in 14 cases	Nil

GDM, gestational diabetes mellitus

Table 1: Placental morphometry in control and test population

Parameter	Control (n = 28)	Test (n = 30)	t Test sig.
Placental weight (g)	462.20 ± 8.57	560.10 ± 77.91	<0.001
Placental volume (cm ³)	419.11 ± 48.49	487.65 ± 47.12	<0.001
Placental area (cm ²)	182.52 ± 28.66	219.65 ± 31.34	<0.001
Placental thickness (cm)	1.67 ± 0.28	3.15 ± 0.40	<0.001
Placental diameter (cm)	15.4 ± 1.49	16.66 ± 1.18	<0.001
Placental circumference (cm)	48.35 ± 4.66	52.32 ± 3.70	<0.001
Fetal weight (kg)	2.53 ± 0.24	4.20 ± 0.24	<0.001

Significance: two-tailed *t*-test significance, placental morphometry shows the highly significant difference in mean of the test and control population studied.

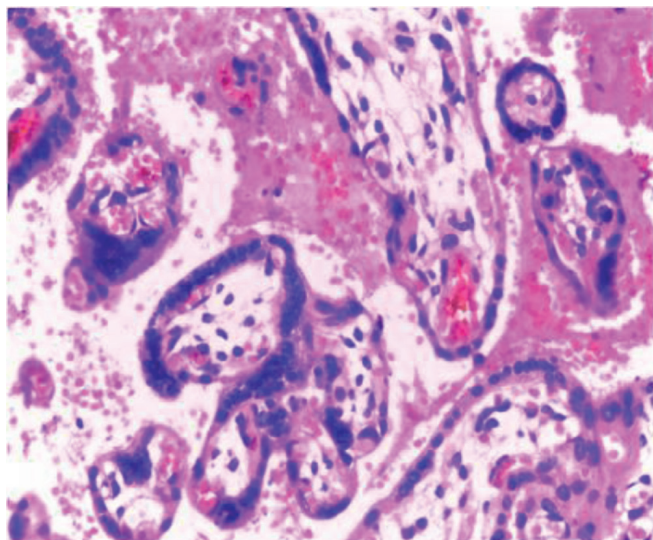


Figure 1: Increased syncytial knots.

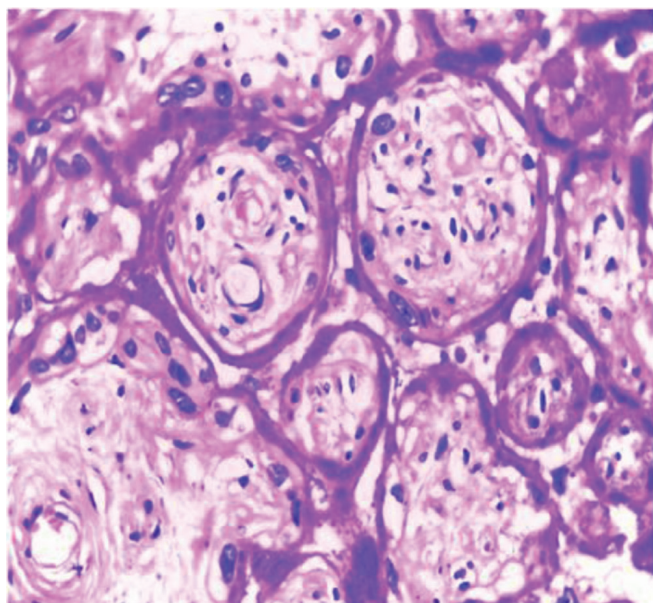


Figure 2: Decreased vascular syncytial membrane.

by preeclampsia or diabetes and can be measured by the production of reactive oxygen species or by the decreased levels of antioxidant enzymes.

Based on the above microscopic observations in the placenta of patients with GDM, it is evident that any factor that influences angiogenesis, especially hypoxia can directly change the villous vascular structure. Reduced vasculo-syncytial formation can be due to the delayed villous maturation, which might be the etiology for the increased risk for intrauterine deaths in diabetic pregnancies. Excessive syncytiotrophoblastic knotting is a histopathologic indicator of excessive chorionic villous capillary proliferation and exaggerated senescence induced by fetal hypoxia. Hence, the

assessment of various histological changes in the placenta on account of hypoxia in GDM is helpful for the retrospective explanations of complications in pregnancy.

Conclusion

Intrauterine hypoxia can cause cellular damage that occurs within the central nervous system. This study showed several significant morphological and histological differences in the placenta of mother with GDM. These changes were absent in normal placenta. The assessment of various histological changes in the placenta on account of hypoxia in GDM is helpful for the retrospective explanations of complications in pregnancy.

References

1. American Diabetes Association. Diagnosis and classification of diabetes mellitus. *Diabetes Care* 2014;37:S81–90.
2. Shao J, Catalano PM, Yamashita H, Ruyter I, Smith S, Youngren J, et al. Decreased insulin receptor tyrosine kinase activity and plasma cell membrane glycoprotein-1 overexpression in skeletal muscle from obese women with gestational diabetes mellitus (GDM): evidence for increased serine/threonine phosphorylation in pregnancy and GDM. *Diabetes* 2000;49(4):603–10.
3. Silverman BL, Rizzo TA, Cho NH, Metzger BE. Long-term effects of the intrauterine environment: the Northwestern University Diabetes in Pregnancy Center. *Diabetes Care* 1998;21 Suppl 2:B142–9.
4. Pridjian G. Pregestational diabetes. *Obstet Gynecol Clin North Am* 2010;37(2):143–58.
5. Drever E, Feig DS. Novel insulin delivery technologies in women with pregestational type 1 diabetes: a review of the literature. *Obstet Med* 2013;6(1):8–12.
6. American Diabetes Association. 2. Classification and Diagnosis of Diabetes. *Diabetes Care* 2016;39 Suppl 1:S13–22.
7. Yli BM, Kjellmer I. Pathophysiology of fetal oxygenation and cell damage during labor. *Best Pract Res Clin Obstet Gynecol* 2016;30:9–21.
8. Lepigeon K, Van Mieghem T, Vasseur Maurer S, Giannoni E, Baud D. Gastroschisis—what should be told to parents? *Prenat Diagn* 2014;34(4):3016–26.
9. Sirdah MM. Protective and therapeutic effectiveness of taurine in diabetes mellitus: a rationale for antioxidant supplementation. *Diabetes Metab Syndr* 2015;9(1):55–64.
10. Ahmed TME. Effect of gestational diabetes on gross morphology, histology and histochemistry of human placenta. *Endocrinol Metab Syndr* 2016;5(1):227.
11. Wilson CB, Nizet V, Maldonado Y, Remington JS, Klein JO. *Remington and Klein's Infectious Diseases of the Fetus and Newborn Infant*. Elsevier Health Sciences, 2015.

How to cite this article: Augustine G, Pulikkathodi M, Renjith S, Jithesh TK. A study of placental histological changes in gestational diabetes mellitus on account of fetal hypoxia. *Int J Med Sci Public Health* 2016;5:2457–2460

Source of Support: Nil, **Conflict of Interest:** None declared.