



# The real-time elastography increasing the diagnostic accuracy of testicular focal lesions

Alfredo D'Andrea<sup>1</sup>, Michele Scialpi<sup>1</sup>, Sabrina Gravante<sup>2</sup>, Michelle Magli<sup>3</sup>, Fabrizio Urraro<sup>3</sup>, Andrea Izzo<sup>3</sup>, Vitaliano Ferrone<sup>3</sup>, Alfonso Reginelli<sup>1</sup>, Corrado Malaspina<sup>1</sup>, Lucia Manganaro<sup>3</sup>, Antonio Rotondo<sup>3</sup>, Irene Piscioi<sup>4</sup>, Teresa Pusiol<sup>5</sup>, Luca Roncati<sup>5,6</sup>

## ABSTRACT

**Objective:** The aim of our research was to evaluate the usefulness of real-time ultrasound elastography (RTE) in the differential diagnosis between benign and malignant non-palpable and palpable testicular lesions in children and adults. **Methods:** B-mode ultrasonography, color/power Doppler, and RTE of 54 patients with 54 unilateral testicular lesions were retrospectively investigated. The imaging results were supported by histopathological examination in all cases. On RTE, the value of tissue rigidity was reported in a chromatic scale and categorized into three patterns: Soft (red), medium (green), and hard (blue). **Results:** Among the 54 testicular lesions, 35 measured more than 2 cm in diameter (32 malignant and 3 benign tumors) while 19 were < 2 cm (9 malignant and 10 benign lesions). In the group of the 41 proved malignant tumors, RTE demonstrated hard pattern in 32 cases. Immature teratomas exhibited a mixed pattern, likely related to their heterogeneous content. In the testicular lesion diagnosis, RTE showed a 78% sensitivity, an 85% specificity, a 94% positive predictive value, a 55% negative predictive value, and an 80% accuracy in differentiating malignant from benign lesions. The integration of ultrasound (US) with color/power Doppler and RTE showed a diagnostic accuracy of 100% and 90%, respectively. **Conclusion:** Integrated with conventional US methods, RTE increases the diagnostic accuracy of US and color/power Doppler in the differential diagnosis between benign and malignant testicular lesions.

<sup>1</sup>Department of Surgical and Biomedical Sciences, Division of Radiology II, University of Perugia, Perugia, Italy, <sup>2</sup>Department of Diagnostic Medicine, Division of Radiology, Santa Maria Hospital, Borgo Val di Taro, Parma, Italy, <sup>3</sup>Department of Internal and Experimental Medicine, "Magrassi-Lanzara," Section of Radiology, Second University of Naples, Naples, Italy, <sup>4</sup>Division of Radiology, Budrio Hospital, Budrio, Italy, <sup>5</sup>Provincial Health Care Services, Institute of Pathology, Santa Maria del Carmine Hospital, Rovereto, Italy, <sup>6</sup>Department of Diagnostic and Clinical Medicine and of Public Health, Section of Pathology, University of Modena and Reggio Emilia, Modena, Italy

**Address for correspondence:** Dr. Luca Roncati, Department of Diagnostic and Clinical Medicine and of Public Health, Section of Pathology, University of Modena and Reggio Emilia, Policlinico Hospital, I-41124 Modena, Italy. Tel.: +390594224812. Fax: +390594224998. E-mail: emailmedical@gmail.com

**Received:** January 08, 2017

**Accepted:** February 27, 2017

**Published:** July 08, 2017

**KEY WORDS:** Color/power doppler, real-time ultrasound elastography, testis, ultrasound, testicular lesions

## INTRODUCTION

The tumors of the testis represent 1% of all male cancers and the most common neoplasia in young men between 15 and 35 years old [1]. An in-depth characterization of the detected lesions is needed for an appropriate treatment (radical orchiectomy *versus* testis-sparing surgery).

Scrotal ultrasound (US) is the first imaging level for the detection of mono- and bi-lateral non-palpable incidental lesions. B-mode US and color/power Doppler, thanks to the assessment of lesion vascularity, have a high sensitivity (100%) in the detection of the lesions; conversely, their specificity is low due to the difficulty in distinguishing malignant and benignant lesions [2].

Contrast-enhanced US (CE-US) significantly improves the diagnostic accuracy, and real-time ultrasound elastography (RTE) increases the specificity in the diagnosis of testicular nodules [3-7]. Magnetic resonance imaging (MRI), recently proposed as an additional diagnostic procedure in the characterization of testicular lesions, offers higher sensitivity and specificity than B-mode US for selected testicular pathologies [8]. Although the role of dynamic contrast-enhanced subtraction MRI (DCE-MRI) in the differential diagnosis between benignant and malignant testicular masses is not yet established [9,10], distinctive DCE-MRI features can allow the differential diagnosis of incidental testicular lesions, such as Leydig cell tumors [11].

The aim of our study was to assess the reliability of RTE in the characterization of focal lesions of the testis, correlating the results with histology.

## METHODS

We have retrospectively investigated 54 testicular lesions, diagnosed from January 2014 to December 2016, belonging to 54 consecutive patients (mean age: 28 years; age range: 10-64 years), with scrotal abnormalities, clinical suspicion, or during screening for infertility and varicocele. Patient data, humoral markers ( $\alpha$ -fetoproteins and  $\beta$ -human-chorionic gonadotropin), and histopathological reports have been retrospectively analyzed, and informed consent was obtained from all patients. The information gathering was achieved in compliance with the Declaration of Helsinki principles. Gray-scale US was used as the first non-invasive imaging test and, in the same session, it was coupled with color/power Doppler and RTE. All the testicular lesions were submitted to histopathological examination. US, color/power Doppler, and RTE of the scrotum were performed by two experienced urologists with almost 15 years of experience on scrotal US, using two different US systems: HI-VISION Preirus (Hitachi Medical Systems; Tokyo, Japan) and GE LOGIQ P3 US System (GE Healthcare; Little Chalfont, Buckinghamshire, UK), with a 5.0-13.0 MHz and 10.0-13.0 MHz linear probe.

RTE has been caudo-cranially carried out through multicompression of the scrotum to improve the signal-to-noise ratio of the diagnostic images [12,13]. The pressure applied to

the testicles was adjusted according to the visual indicator for compression, which indicated the average strain in the region of interest between two frames, displaying also the optimal strain on the video screen. The calculation of tissue elasticity distribution was rendered in real time (up to 30 frames/s), and the stiffness of testicular tissue was displayed with a color overlay on the B-mode image.

## Image Analysis

Standardized protocols with axial and transverse scans of the lesions were applied according to Dogra *et al.* [14]. On gray-scale US, lesion size (in the three spatial planes, cutoff: 20 mm), echogenicity (hypo-, iso-, and hyper-echoic to the parenchyma), homogeneity, and pseudocapsule were taken into account. On color/power Doppler, vascularity (intralesional, perilesional, or mixed vascularization and hyper-, hypo-, or avascularization if compared to normal testicular parenchyma) was documented. On RTE, tissue stiffness was encoded from red (soft) to blue (hard), according to the standard settings of the US system. The evaluation of the tissue rigidity was so reported in a chromatic scale and categorized into three patterns: (1) soft (red), (2) medium (green), and (3) hard (blue). For each patient, at least two representative images or cine loops were stored on an external hard disk.

## Statistical Analysis

All statistical analyses were software assisted (SPSS Statistics base 17.0; SPSS Inc. Chicago, IL, USA). Sensitivity, specificity, negative predictive value, positive predictive value, and diagnostic accuracy were calculated. In the differential diagnosis between seminomas and non-seminomas, we used Pearson's Chi-squared test ( $P < 0.005$  was considered indicative of a statistically significant difference).

## RESULTS

With respect to lesion size, the lesions ( $n = 54$ ) were categorized in lesions  $>20$  mm ( $n = 35$ ) and in lesions  $<20$  mm ( $n = 19$ ).

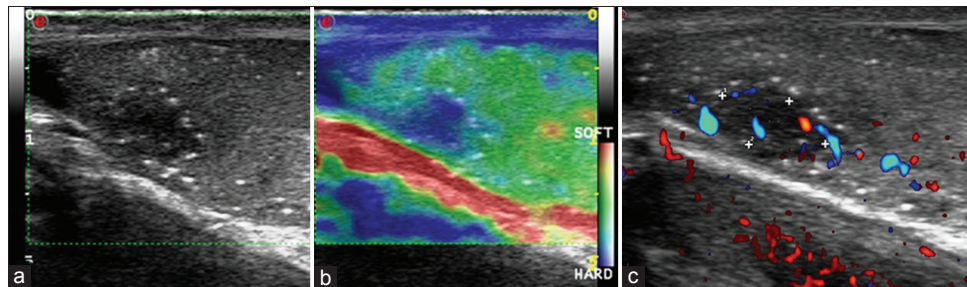
The 35 lesions (diameter  $>20$  mm) were treated by radical inguinal orchiectomy, and the histopathologic examination revealed that 32 of the 35 lesions were testicular malignant tumors (18 seminomas, 9 mixed germinal cell tumors, 2 embryonal carcinomas, and 3 immature teratomas), while the remaining 3 of the 35 lesions were testicular benign tumors (Leydig cell tumors). Table 1 shows the findings relative to gray-scale US, color/power Doppler US, and RTE for the above-mentioned 35 lesions. On gray-scale US, a statistically significant difference between seminomatous ( $n = 18$ ) and not pure seminomatous tumors ( $n = 17$ ) was revealed ( $P < 0.0001$ ). No statistical differences on color/power Doppler and RTE were noticed.

Among the 19 lesions with diameter  $<20$  mm, 17 were approached through inguino-scrotal exploration, followed by nodulectomy with intraoperative examination and, only after the achievement of a malignant diagnosis, the patients

**Table 1: Findings on gray-scale US, color/power Doppler, and RTE of 35 lesions >20 mm**

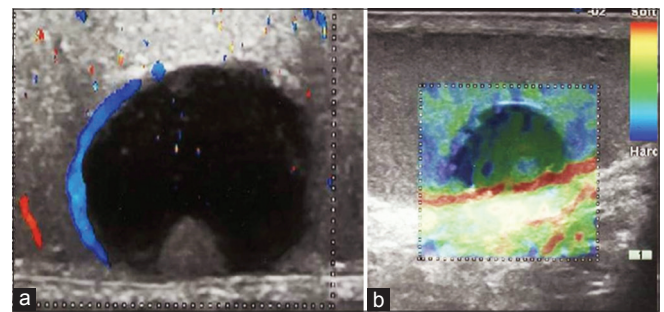
Lesions	n	US pattern					Color doppler pattern			RTE pattern		
		Homogeneous	Inhomogeneous	Hypo-echoic	Mixed echogenicity/isoechoic	Hyper-echoic	Peripheral	Intralesional	Mixed vascularization	Hard blue	Green	Red-green-blue (mixed)
Seminomas	18	18	-	10	8	-	-	5	13	18	-	-
Mixed seminomatous and/or nonseminomatous tumors	9	5	4	8	1	-	5	2	2	7	2	-
Embryonal carcinoma	2	-	2	1	1	-	-	2	-	2	-	-
Immature teratoma	3	-	3	1	1	1	-	3	-	-	1	2
Leydig cell tumors	3	2	1	-	-	3	2	-	1	-	3	-
Total	35	25	10	20	11	4	7	12	16	27	6	2

RTE: Real-time elastography, US: Ultrasound

**Figure 1:** Seminoma arisen in cryptorchid testis. (a) A focal hypoechoic lesion (4 mm in diameter) with diffuse calcification (microlithiasis) at gray-scale ultrasound, (b) Type III hard signal on RTE and (c) intrinsic vascularization at color/power Doppler

underwent a radical inguinal orchiectomy. Histopathologic examination revealed 9 malignant tumors, that is, 5 seminomas [Figure 1], 2 mixed germinal cell tumors and 2 immature teratomas, and 8 benign lesions, in detail, 2 Leydig cell tumors, 1 papillary cystadenoma [Figure 2], 2 orchitis, 1 dermoid cyst, 1 focal fibrosis, and 1 adnexal remnant. The remaining 2 of the 17 lesions, 1 hyaline nodule [Figure 3] and 1 post-traumatic focal fibrosis [Figure 4], were intraoperatively biopsied. Table 2 shows the findings relative to gray-scale US, color/power Doppler US, and RTE for the above-mentioned 19 lesions. For lesions <20 mm, the differential diagnosis between benignant and malignant lesion was not possible by gray-scale US and color/power Doppler, and only the benign fibrotic and hyaline lesions were distinguished, thanks to the absence of signal-color on color/power Doppler. RTE rendered a soft pattern for 2 lesions (immature teratoma) among the 9 malignant lesions, a mixed pattern for 5 of 10 benign lesions ( $P < 0.05$ ), and a hard pattern in 2 of 10 benign lesions (orchitis and hyaline nodule).

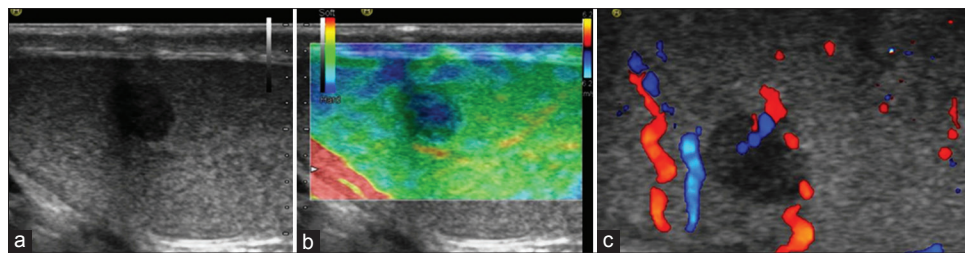
In Table 3, the findings relative to gray-scale US, color/power Doppler, and RTE for all lesions are reported. For RTE, 78% sensitivity (32 of 41 lesions), 85% specificity (11 of 13 lesions), 94% positive predictive value (32 of 34 lesions), 55% negative predictive value (11 of 20 lesions), and 80% accuracy (43 of 54 lesions) have been emerged in testicular tumor diagnosis, about all lesions included in our study.

**Figure 2:** Papillary cystadenoma: The color/power Doppler shows intratesticular anechoic cyst with inclusions and peripheral vascularity of the lesion (a) and a Type I and II pattern on real-time ultrasound elastography (b)

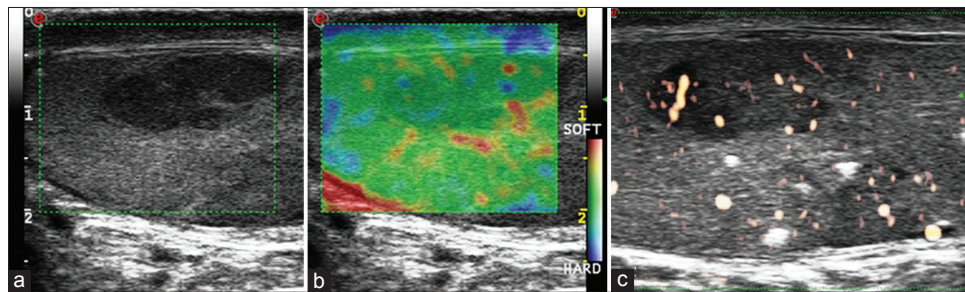
For the 35 lesions >20 mm, RTE showed 84% sensitivity (27 of 32 lesions), 100% specificity (3 of 3 lesions), 100% positive predictive value (27 of 27 lesions), 43% negative predictive value (3 of 7 lesions), and 86% accuracy (30 of 35 lesions).

For the 19 lesions <20 mm, RTE showed 55% sensitivity (5 of 9 lesions), 80% specificity (8 of 10 lesions), 71% positive predictive value (5 of 7 lesions), 67% negative predictive value (8 of 12 lesions), and 68% accuracy (13 of 19 lesions).

For conventional US (gray-scale US and color/power Doppler), we obtained 80% sensitivity (37 of 46 lesions), 62% specificity



**Figure 3:** Hyaline nodule inside the testicular parenchyma seen at ultrasound (a), real-time ultrasound elastography (RTE) (b), and color/power Doppler (c): An intraparenchymal focal hypoechoic lesion (a), a Type III pattern into the lesion with a Type II and III pattern in the peripheral zone on RTE (b), and an intrinsic vascularization at color/power Doppler (c) are appreciable



**Figure 4:** A focal fibrosis arisen inside a cryptorchid testis with calcifications at ultrasound (US) (a), real-time ultrasound elastography (RTE) (b), and color/power Doppler (c): An intratesticular hypoechoic lesion at US (a) is observable, while RTE shows Type II pattern (b), and color power-Doppler intralesional vascularity (c)

**Table 2:** Findings on gray-scale US, color/power Doppler US, and RTE of 19 lesions <20 mm

Lesions	n	US pattern					Color doppler pattern			RTE pattern		
		Homogeneous	Inhomogeneous	Hypo-echoic	Mixed echogenicity/isoechoic	Hyper-echoic	Peripheral	Intralesional	Mixed vascularization	Hard blue	Green	Red-green-blue (mixed)
Seminomas	5	5	-	4	1	-	-	-	5	3	2	-
Mixed seminomatous and/or nonseminomatous tumors	2	2	-	2	-	-	-	1	1	2	-	-
Immature teratoma	2	1	1	1	1	-	-	-	2	-	-	2
Leydig cell tumors	2	1	1	-	1	1	2	-	-	-	2	-
Orchitis	2	-	2	1	-	1	1	-	1	1	-	1
Dermoid cyst	1	-	1	-	-	1	1	-	-	-	-	1
Adnexal remnant	1	-	1	-	-	1	-	-	1	-	1	-
Papillary cystadenoma	1	-	1	-	1	-	1	-	-	-	-	-
Hyaline nodule	1	1	-	1	-	-	1	-	-	1	-	-
Focal fibrosis	1	1	-	1	-	-	1	-	-	-	1	-
Post-traumatic focal fibrosis	1	1	-	1	-	-	-	-	1	-	1	-
<b>Total</b>	<b>19</b>	<b>12</b>	<b>7</b>	<b>11</b>	<b>4</b>	<b>4</b>	<b>7</b>	<b>1</b>	<b>11</b>	<b>7</b>	<b>7</b>	<b>5</b>

RTE: Real-time elastography, US: Ultrasound

(5 of 8 lesions), 92% positive predictive value (37 of 40 lesions), 36% negative predictive value (5 of 14 lesions), and 78% accuracy (42 of 54 lesions).

For integrated gray-scale US, color/power Doppler, and RTE, we have obtained 100% sensitivity (41 of 41 lesions), 61% specificity (8 of 13 lesions), 89% positive predictive value (41 of 46 lesions),

100% negative predictive value (8 of 8 lesions), and 90% accuracy (49 of 54 lesions).

## DISCUSSION

To differentiate benignant from malignant testicular tumors is essential to establish the appropriate treatment. Gray-scale



Table 3: Findings on gray-scale US, color/power Doppler, and RTE of all 54 lesions

Lesions	n	US pattern					Color doppler pattern			RTE pattern		
		Homogeneous	Inhomogeneous	Hypo-echoic	Mixed echogenicity/isoechoic	Hyper-echoic	Peripheral	Intralesional	Mixed vascularization	Hard blue	Green	Red. green-blue (mixed)
All lesions												
Seminomas	23	22	1	14	9	-	-	5	18	21	2	-
Mixed	11	7	4	10	1	-	5	3	3	9	2	-
Seminomatous and/or nonseminomatous tumors												
Embryonal C	2	-	2	1	1	-	-	2	-	2	-	-
Immature teratoma	5	1	4	2	2	1	-	3	2	-	1	4
Leydig cell tumors	5	3	2	-	1	4	4	-	1		5	-
Orchitis	2	-	2	1	-	1	1	-	1	1	-	1
Dermoid cyst	1	-	1	-	-	1	1	-	-	-	-	1
Adnexal remnant	1	-	1	-	-	1	-	-	1	-	1	-
Papillary cystadenoma	1	-	1	-	1	-	1	-	-	-	-	1
Hyaline nodule	1	1	-	1	-	-	1	-	-	1	-	-
Focal fibrosis	1	1	-	1	-	-	1	-	-	-	1	-
Posttraumatic focal fibrosis	1	1	-	1	-	-	-	-	1	-	1	-
Total	54	36	18	31	15	8	14	13	27	34	13	7

RTE: Real-time elastography, US: Ultrasound

US is the first-line diagnostic examination to depict testicular tumors in most cases; however, the differential diagnosis between benign and malignant tumor is difficult by gray-scale US and color/power Doppler [15], especially for small lesions (<20 mm).

Testicular tumors with a diameter <15 mm may not show flow on color/power Doppler and thus may be misinterpreted as benign lesions. A particular target is the differentiation between hypovascular and avascular lesions, presuming that an avascular lesion has a benign nature, and for this, CE-US is recommended, in particular for focal testicular lesions [16]. Isidori *et al.* have demonstrated that, in experienced centers, CE-US can improve the diagnostic accuracy of unenhanced US in the differential diagnosis of testicular non-palpable lesions [4]. CE-US allows the visualization of testicular microvascularization and may aid in the pre-operative assessment of suspected testicular lesions with hypervascularization, especially of smallest ones [17,18]. The combination of unenhanced and CE-US has in fact achieved a high diagnostic accuracy in the diagnosis of small testicular malignancies [4]. Similarly, the possibility of MRI using as third-level imaging in the study of testicular lesions has been proposed, in particular if they are difficultly characterizable, after inconclusive sonography [19].

In some cases, the lesions identified by US have characteristics, which allow to discriminate their nature with high accuracy; for example, the cysts are lesions easily detectable for their fluid content, without further diagnostic examinations. Instead, many focal lesions have overlapping sonographic features and often to discriminate their nature on the basis of their US presentation is very difficult, if not impossible.

MRI has been advocated as an adjunct to unenhanced US and CE-US examination and it can be used as a problem-solving tool in cases of equivocal findings or uncertainty, as also occurs in other diagnostic fields [20,21], decreasing the number of unnecessary surgical procedures. MRI can potentially characterize benign and malignant testicular lesions and can suggest a specific diagnostic hypothesis (e.g., Leydig cell tumor and seminoma) when specific imaging features are present [11]. However, MRI remains an expensive investigation tool and lacks availability [8,11,22].

To increase the diagnostic value of gray-scale US and color/power Doppler for differentiating between tumorous and non-tumorous testicular lesions, RTE, originally introduced to make non-invasive measurements of tissue mechanical properties and to image the elasticity of biological substrates, has been already proposed [23-25]. Surely, the familiarity with US techniques in both benign and malignant abnormalities should aid to improve the confidence for reaching a correct diagnosis.

In general, most malignancies show increased stiffness because they have a higher cell and vascular density, if compared with the surrounding normal tissues [3]. According to Aigner *et al.*, some benign intratesticular lesions are associated with an increased stiffness at RTE, such as fibrosis, scar, orchitis, and adnexal remnant.<sup>3</sup> In our study, RTE has shown a red or green pattern in 11/13 (85%) of the benign lesions, and only 5/41 cases (12%) with soft pattern were found malignant. With the exception for the 5 malignant lesions (5 teratomas) with a soft pattern, all malignant lesions showed a hard pattern, evidence of the extremely high sensitivity of RTE; the low stiffness of teratomas

is likely the result of a high inhomogeneity of the tumor, also related to the presence, in a variable percentage, of adipocytes.

As reported in literature [26], Leydig cell tumor can demonstrate a variable pattern at RTE, depending on the number and size of Leydig cells, lymphatic or vascular invasion, cytonuclear atypia, number of mitoses, absence of well-defined edge, or presence of a capsule; in our experience, the 5 benign Leydig cell tumors showed a medium stiff pattern. On RTE, seminoma is usually hard (21/23 lesions); furthermore, seminoma occasionally can show a soft intralesional area, due to necrotic changes [26], in support of our two cases of seminoma with green pattern.

Unlike Aigner *et al.*, some cases of fibrosis included in our study (1 focal fibrosis and 1 post-traumatic focal fibrosis) have mainly shown a green pattern on RTE evaluation, while the hyaline nodule ( $n = 1$ ) has shown a blue pattern. Furthermore, we have not included cysts because they are diagnosable by US and color/power Doppler.

On RTE images, Goddi *et al.* assign a 5-stiff pattern to testicular lesions, as elastographic score, according to the distribution and degree of strain suggested by Itoh *et al.* for breast disease [23-27]. On the other hand, Aigner *et al.* classify the tissue stiffness of the lesions in 2 score, that is soft and hard, on the basis of their previous experience [3].

We consider that 2-stiff pattern is not sufficient, as several injuries have an intermediate pattern of compression, while 5-stiff pattern can be confusing, so 3-stiff pattern, as degrees of compressibility, appears optimal.

Since Goddi *et al.* do not provide detailed histological data for each type of lesion and use a different classification of the lesions [23], we cannot perform a reliable comparison between their and our results.

About focal lesions with suspicious for malignancy detected by even one of the three assessments (gray-scale US, color/power Doppler, and RTE), we believe they should be considered as malignant lesions until proven otherwise.

## CONCLUSION

In our experience, RTE has the potential to increase sensitivity and diagnostic accuracy of gray-scale US and color/power Doppler, up to 100% and 90%, respectively. This preliminary study demonstrates the effectiveness of RTE in the evaluation of focal testicular lesions, especially for small lesions (<20 mm), thus avoiding unnecessary surgery with its risks and its consequences, especially in young patients.

## REFERENCES

- Russell SS. Testicular cancer: Overview and implications for health care providers. *Urol Nurs* 2014;34:172-6, 192.
- Grainger AJ, Hide IG, Elliott ST. The ultrasound appearances of scrotal oedema. *Eur J Ultrasound* 1998;8:33-7.
- Aigner F, De Zordo T, Pallwein-Pretner L, Junker D, Schäfer G, Pichler R, *et al.* Real-time sonoelastography for the evaluation of testicular lesions. *Radiology* 2012;263:584-9.
- Isidori AM, Pozza C, Gianfrilli D, Giannetta E, Lemma A, Pofi R, *et al.* Differential diagnosis of non-palpable testicular lesions: Qualitative and quantitative contrast-enhanced ultrasound (CEUS) of benign and malignant testicular tumors. *Radiology* 2014;273:606-18.
- Lock G, Schröder C, Schmidt C, Anheuser P, Loening T, Dieckmann KP. Contrast-enhanced ultrasound and real-time elastography for the diagnosis of benign Leydig cell tumors of the testis - A single center report on 13 cases. *Ultraschall Med* 2014;35:534-9.
- Huang DY, Sidhu PS. Focal testicular lesions: Colour Doppler ultrasound, contrast-enhanced ultrasound and tissue elastography as adjuvants to the diagnosis. *Br J Radiol* 2012;85:S41-53.
- Cantisani V, Olive M, Di Segni M, Di Leo N, Grazdhan H, D'Ettore G, *et al.* Contrast-enhanced ultrasonographic (CEUS) and elastosonographic features of a case of testicular Leydig tumor. *Ultraschall Med* 2012;33:407-9.
- Kim W, Rosen MA, Langer JE, Banner MP, Siegelman ES, Ramchandani P. US MR imaging correlation in pathologic conditions of the scrotum. *Radiographics* 2007;27:1239-53.
- Watanabe Y, Dohke M, Ohkubo K, Ishimori T, Amoh Y, Okumura A, *et al.* Scrotal disorders: Evaluation of testicular enhancement patterns at dynamic contrast-enhanced subtraction MR imaging. *Radiology* 2000;217:219-27.
- Tsili AC, Argyropoulou MI, Astrakas LG, Ntoulia EA, Giannakis D, Sofikitis N, *et al.* Dynamic contrast enhanced subtraction MRI for characterizing intratesticular mass lesions. *Am J Roentgenol* 2013;200:578-85.
- Woldrich JM, Im RD, Hughes-Cassidy FM, Aganovic L, Sakamoto K. Magnetic resonance imaging for intratesticular and extratesticular scrotal lesions. *Can J Urol* 2013;20:6855-9.
- Konofagou EE, Ophir J, Kallel F, Varghese T. Elastographic dynamic range expansion using variable applied strains. *Ultrason Imaging* 1997;19:145-66.
- Varghese T, Zagzebski JA, Frank G, Madsen EL. Elastographic imaging using a handheld compressor. *Ultrason Imaging* 2002;24:25-35.
- Dogra VS, Gottlieb RH, Oka M, Rubens DJ. Sonography of the scrotum. *Radiology* 2003;227:18-36.
- Lesnik G, Nickl S, Kuschnig P, Sinzig M, Hausegger K, Jeschke K. Sonography of the scrotum. *Rofo* 2006;178:165-79.
- Piscaglia F, Nolsøe C, Dietrich CF, Cosgrove DO, Gilja OH, Bachmann Nielsen M, *et al.* The EFSUMB guidelines and recommendations on the clinical practice of contrast enhanced ultrasound (CEUS): Update 2011 on non-hepatic applications. *Ultraschall Med* 2012;33:33-59.
- Lock G, Schmidt C, Helmich F, Stolle E, Dieckmann KP. Early experience with contrast-enhanced ultrasound in the diagnosis of testicular masses: A feasibility study. *Urology* 2011;77:1049-53.
- Shah A, Lung PF, Clarke JL, Sellars ME, Sidhu PS. Re: New ultrasound techniques for imaging of the indeterminate testicular lesion may avoid surgery completely. *Clin Radiol* 2010;65:496-7.
- Muglia V, Tucci S Jr., Elias J Jr., Trad CS, Bilbey J, Cooperberg PL. Magnetic resonance imaging of scrotal diseases: When it makes the difference. *Urology* 2002;59:419-23.
- Manganaro L, Scialpi M, Pescioli F, Pusiol T, Roncati L. MRI prenatal diagnosis of genitourinary abnormalities in a case of inconclusive ultrasonography. *J Obstet Gynaecol* 2016;36:762-3.
- Manganaro L, Vinci V, Giancotti A, Gerli S, Cozzi DA, Pusiol T, *et al.* Bi-parametric magnetic resonance imaging applied to obstetrics. *J Obstet Gynaecol* 2017;17:1-3.
- Park SB, Lee WC, Kim JK, Choi SH, Kang BS, Moon KH, *et al.* Imaging features of benign solid testicular and paratesticular lesions. *Eur Radiol* 2011;21:2226-34.
- Goddi A, Sacchi A, Magistretti G, Almolla J, Salvatore M. Real-time tissue elastography for testicular lesion assessment. *Eur Radiol* 2012;22:721-30.
- Grasso M, Blanco S, Raber M, Nespoli L. Elasto-sonography of the testis: Preliminary experience. *Arch Ital Urol Androl* 2010;82:160-3.
- Pallwein L, Steiner H, Akkad T, Bartsch G, Frauscher F. Real-time

- elastography for evaluation of testicular masses: Initial experience. *Eur Urol* 2006;5:96.
26. Valentino M, Bertolotto M, Martino P, Barozzi L, Pavlica P. Incidentally detection of non-palpable testicular nodules at scrotal ultrasound: What is new? *Arch Ital Urol Androl* 2014;86:378-82.
27. Itoh A, Ueno E, Tohno E, Kamma H, Takahashi H, Shiina T, *et al.* Breast disease: Clinical application of US elastography for diagnosis. *Radiology* 2006;239:341-50.

© **EJManager**. This is an open access article licensed under the terms of the Creative Commons Attribution Non-Commercial License (<http://creativecommons.org/licenses/by-nc/3.0/>) which permits unrestricted, noncommercial use, distribution and reproduction in any medium, provided the work is properly cited.

**Source of Support: Nil, Conflict of Interest: None declared.**